

# Dental and Medical Problems

QUARTERLY ISSN 1644-387X (PRINT) ISSN 2300-9020 (ONLINE)

[www.dmp.umed.wroc.pl](http://www.dmp.umed.wroc.pl)

2019, Vol. 56, No. 3 (July–September)

Ministry of Science and Higher Education – 20 pts.  
Index Copernicus (ICV) – 113.05 pts.



WROCLAW  
MEDICAL UNIVERSITY

# Dental and Medical Problems

ISSN 1644-387X (PRINT)

ISSN 2300-9020 (ONLINE)

www.dmp.umed.wroc.pl

**QUARTERLY**  
**2019, Vol. 56, No. 3**  
**(July–September)**

“Dental and Medical Problems” is a peer-reviewed open access journal published by Wrocław Medical University. Journal publishes articles from different fields of dentistry and other medical, biological, deontological and historical articles, which were deemed important to dentistry by the Editorial Board – original papers (clinical and experimental), reviews, clinical cases, and letters to the Editorial Board.

## Address of Editorial Office

Marcinkowskiego 2–6  
50-368 Wrocław, Poland  
Tel.: +48 71 784 11 33  
E-mail: dental@umed.wroc.pl

## Publisher

Wrocław Medical University  
Wybrzeże L. Pasteura 1  
50-367 Wrocław, Poland

© Copyright by Wrocław Medical University  
Wrocław 2019

Online edition is the original version of the journal

## Editor-in-Chief

Tomasz Konopka

## Vice-Editor-in-Chief

Marcin Mikulewicz

## Thematic Editors

Anna Zalewska (Cariology)  
Mariusz Lipski (Endodontics)  
Urszula Kaczmarek (Pedodontics  
and Dental Prevention)  
Renata Górską (Oral Pathology)  
Korkud Demirel (Periodontology)  
Piotr Majewski (Implant Dentistry)

Andrzej Wojtowitz (Oral Surgery)  
Marcin Kozakiewicz (Maxillofacial Surgery)  
Teresa Sierpińska (Prosthodontics)  
Jolanta Kostrzewa-Janicka (Disorders  
of Masticatory System)  
Marcin Mikulewicz (Orthodontics)  
Ingrid Różyło-Kalinowska (Dental Radiology)

## International Advisory Board

Akira Aoki (Japan)  
Einar Berg (Norway)  
Wojciech Blonski (USA)  
Ewa Czochrowska (Poland)  
Patrizia Defabianis (Italy)  
Marzena Dominiak (Poland)  
Barbara Dorocka-Bobkowska (Poland)  
Omar El-Mowafy (Canada)  
Katarzyna Emerich (Poland)  
Piotr Fudalej (Czech Republic, Switzerland)  
Thomas Gedrange (Germany)  
Hanna Gerber (Poland)  
David Herrera (Spain)  
Michał Jeleń (Poland)  
Milan Kamínek (Czech Republic)  
Kazimierz Kobus (Poland)  
Krystyna Konopka (USA)  
Marcin Kos (Germany)

Tadeusz F. Krzemiński (Poland)  
Monika Łukomska-Szymańska (Poland)  
Marina V. Maevskaya (Russia)  
Agnieszka Mielczarek (Poland)  
Joseph Nissan (Israel)  
Raphaël Olszewski (Belgium)  
Hyo-Sang Park (South Korea)  
Alina Pūrienė (Lithuania)  
Małgorzata Radwan-Oczko (Poland)  
Monique-Marie Rousset-Caron (France)  
Franciszek Szatko (Poland)  
Jacek C. Szepietowski (Poland)  
Selena Toma (Belgium)  
János Vág (Hungary)  
Danuta Waszkiel (Poland)  
Dariusz Wołowicz (Poland)  
Grażyna Wyszyńska-Pawelec (Poland)  
Marek Ziętek (Poland)

**Statistical Editor**

Krzysztof Topolski

**Technical Editorship**

Adam Barg

Joanna Gudarowska

Paulina Kunicka

Marek Misiak

**English Language Copy Editors**

Eric Hilton

Sherill Howard-Pociecha

Jason Schock

Marcin Tereszewski

**Editorial Policy**

During the reviewing process, the Editorial Board conforms to the "Uniform Requirements for Manuscripts Submitted to Biomedical Journals: Writing and Editing for Biomedical Publication" approved by the International Committee of Medical Journal Editors (<http://www.icmje.org/>). Experimental studies must include a statement that the experimental protocol and informed consent procedure were in compliance with the Helsinki Convention and were approved by the ethics committee.

Indexed in: MEDLINE, Scopus, DOAJ, GFMER, Index Copernicus, Ministry of Science and Higher Education, CiteFactor, WorldCat, Directory of Research Journal Indexing.

This publication has been co-financed by the Ministry of Science and Higher Education.

Typographic design: Monika Kołęda, Piotr Gil

Cover: Monika Kołęda

DTP: Wrocław Medical University Press

Printing and binding: EXDRUK

## Contents

### Original papers

- 223 Rajaa Abdullah Albugami, Steph Smith, Mohammed Al-Sheikh Hassan, Khalid Almas  
**Trends in implant dentistry: Implant systems, complications and barriers in Riyadh, Saudi Arabia**
- 231 Katarzyna Wąsacz, Agnieszka Pac, Dagmara Darczuk, Maria Chomyszyn-Gajewska  
**Validation of a modified Oral Health Impact Profile scale (OHIP-14) in patients with oral mucosa lesions or periodontal disease**
- 239 Paridokht Zarean, Reza Roozbeh, Parichehr Zarean, Maryam Zare Jahromi, Parvin Mirzakoochaki Broujeni  
**In vitro comparison of shear bond strength of a flowable composite resin and a single-component glass-ionomer to three different pulp-capping agents**
- 245 Shila Emamieh, Mahya Elahi, Amir Ghasemi  
**Effect of two universal adhesives on microshear bond strength of resin cement to zirconia**
- 251 Mohammad Ramadan Rayyan  
**Effect of the interproximal contact level on the perception of smile esthetics**
- 257 Sarah Irfan, Mubassar Fida  
**Comparison of soft and hard tissue changes between symmetric and asymmetric extraction patterns in patients undergoing orthodontic extractions**
- 265 Mahmood Hasan Toameh, Issam Alkhouri, Mohammed Ammar Karman  
**Management of patients with disk displacement without reduction of the temporomandibular joint by arthrocentesis alone, plus hyaluronic acid or plus platelet-rich plasma**
- 273 Rami Shurbaji Mozayek, Manar Ali Alkhalil, Mirza Allaf, Suleiman Dayoub  
**Evaluation of the fracture strength of porcelain sectional veneers made from different sintered feldspathic porcelains: An in vitro study**
- 279 Farzaneh Ostovarrad, Somayeh Nemati, Abbas Shokri, Elaheh Baghizadeh, Zahra Yousefi  
**Evaluation of the effect of the inversion filter on enhancing the visibility of the mandibular incisive canal in comparison with the original images**
- 285 Elżbieta Łuczaj-Cepowicz, Grażyna Marczuk-Kolada, Małgorzata Pawińska, Janusz Różycki, Ewa Chorzewska  
**Comparison of the radiopacity of selected materials used for vital pulp therapy: An in vitro assessment**

### Reviews

- 291 Renata Samulak-Zielińska, Elżbieta Dembowska, Piotr Lizakowski  
**Dental treatment of post-myocardial infarction patients: A review of the literature**
- 299 Massoumeh Zargaran  
**Clinicians' role in the occurrence of oral biopsy artifacts as a potential diagnostic dilemma**

## Clinical cases

- 307 Chaitali Hambire  
**Shprintzen–Goldberg syndrome with plagiocephaly: A case report**
- 311 Mateusz Dymek, Mariusz Książek, Bogumił Lewandowski  
**Transformation of a glandular odontogenic cyst into mucoepidermoid carcinoma of the mandible: A case report**
- 317 Maria Olejnik, Zuzanna Ślebioda, Barbara Dorocka-Bobkowska  
**Low-level laser therapy (LLLT) in the treatment of recurrent aphthous stomatitis (RAS) – a promising treatment option: A report of two cases**

## Spis treści

### Prace oryginalne

- 223 Rajaa Abdullah Albugami, Steph Smith, Mohammed Al-Sheikh Hassan, Khalid Almas  
**Trendy w implantologii stomatologicznej – systemy implantologiczne, powikłania i ograniczenia w stolicy Arabii Saudyjskiej, Rijadzie**
- 231 Katarzyna Wąsacz, Agnieszka Pac, Dagmara Darczuk, Maria Chomyszyn-Gajewska  
**Walidacja zmodyfikowanego wskaźnika profilu zdrowia jamy ustnej (OHIP-14) u pacjentów z chorobami błony śluzowej jamy ustnej lub periodontopatiami**
- 239 Paridokht Zarean, Reza Roozbeh, Parichehr Zarean, Maryam Zare Jahromi, Parvin Mirzakoochaki Broujeni  
**Porównanie in vitro wytrzymałości na ścinanie wiązania płynnej żywicy kompozytowej i jednoskładnikowego szkło-jonomeru z trzema materiałami do pokrycia miazgi**
- 245 Shila Emamieh, Mahya Elahi, Amir Ghasemi  
**Wpływ dwóch uniwersalnych systemów łączących na wytrzymałość na mikrościananie wiązania cementu kompozytowego do cyrkonu**
- 251 Mohammad Ramadan Rayyan  
**Wpływ miejsca kontaktu międzyzębowego na odbiór estetyki uśmiechu**
- 257 Sarah Irfan, Mubassar Fida  
**Porównanie zmian tkanek miękkich i twardych pomiędzy metodami ekstrakcji symetrycznej i asymetrycznej u pacjentów leczonych ekstrakcyjnie ze wskazań ortodontycznych**
- 265 Mahmood Hasan Toameh, Issam Alkhoury, Mohammed Ammar Karman  
**Leczenie pacjentów z przemieszczeniem krążka stawowego z zablokowaniem stawu skroniowo-żuchwowego wyłącznie przez artrocentezę lub dodatkowo z kwasem hialuronowym lub osoczem bogatopłytkowym**
- 273 Rami Shurbaji Mozayek, Manar Ali Alkhalil, Mirza Allaf, Suleiman Dayoub  
**Ocena wytrzymałości na złamanie częściowych licówek porcelanowych otrzymanych z różnych spiekanych ceramik skaleniowych – badanie in vitro**
- 279 Farzaneh Ostovarrad, Somayeh Nemati, Abbas Shokri, Elaheh Baghizadeh, Zahra Yousefi  
**Ocena widoczności kanału przysiecznego żuchwy po zastosowaniu filtra inwersyjnego w odniesieniu do oryginalnego obrazowania radiologicznego**
- 285 Elżbieta Łuczaj-Cepowicz, Grażyna Marczuk-Kolada, Małgorzata Pawińska, Janusz Różycki, Ewa Chorzewska  
**Porównanie pochłaniania promieni rentgenowskich przez wybrane materiały stosowane w leczeniu biologicznym miazgi – ocena in vitro**

### Prace poglądowe

- 291 Renata Samulak-Zielińska, Elżbieta Dembowska, Piotr Lizakowski  
**Leczenie stomatologiczne pacjentów po przebytych zawale mięśnia sercowego – przegląd piśmiennictwa**
- 299 Massoumeh Zargarani  
**Rola lekarzy klinicyстів w powstawaniu artefaktów w badaniu histopatologicznym jamy ustnej jako możliwy dylemat diagnostyczny**

## Prace kazuistyczne

- 307 Chaitali Hambire  
**Zespół Shprintzena–Goldberga ze skośnogłowiem – opis przypadku**
- 311 Mateusz Dymek, Mariusz Książek, Bogumił Lewandowski  
**Transformacja zębopochodnej torbieni gruczołowej w raka śluzowo-płaskonabłonkowego żuchwy – opis przypadku**
- 317 Maria Olejnik, Zuzanna Ślebioda, Barbara Dorocka-Bobkowska  
**Terapia laserem małej mocy w aftach nawrotowych – obiecująca opcja w leczeniu. Opis dwóch przypadków**

# Trends in implant dentistry: Implant systems, complications and barriers in Riyadh, Saudi Arabia

## Trendy w implantologii stomatologicznej – systemy implantologiczne, powikłania i ograniczenia w stolicy Arabii Saudyjskiej, Rijadzie

Rajaa Abdullah Albugami<sup>1,B,C,F</sup>, Steph Smith<sup>2,D–F</sup>, Mohammed Al-Sheikh Hassan<sup>3,C</sup>, Khalid Almas<sup>2,A,D–F</sup>

<sup>1</sup> Department of Periodontics, Riyadh Dental Center, King Saud Medical City, Riyadh, Saudi Arabia

<sup>2</sup> Division of Periodontology, Department of Preventive Dental Sciences, College of Dentistry, Imam Abdulrahman Bin Faisal University, Dammam, Saudi Arabia

<sup>3</sup> Faculty of Health and Life Sciences, De Montfort University, Leicester, UK

A – research concept and design; B – collection and/or assembly of data; C – data analysis and interpretation;

D – writing the article; E – critical revision of the article; F – final approval of the article

Dental and Medical Problems, ISSN 1644-387X (print), ISSN 2300-9020 (online)

*Dent Med Probl.* 2019;56(3):223–230

### Address for correspondence

Khalid Almas  
E-mail: Kalmas@iau.edu.sa

### Funding sources

None declared

### Conflict of interest

None declared

### Acknowledgements

The authors would like to thank all the dentists/specialists who participated in the study.

Received on December 16, 2018

Reviewed on March 25, 2019

Accepted on April 19, 2019

Published online on September 30, 2019

### Cite as

Albugami RA, Smith S, Hassan MA, Almas K. Trends in implant dentistry: Implant systems, complications and barriers in Riyadh, Saudi Arabia. *Dent Med Probl.* 2019;56(3):223–230. doi:10.17219/dmp/108659

### DOI

10.17219/dmp/108659

### Copyright

© 2019 by Wrocław Medical University

This is an article distributed under the terms of the Creative Commons Attribution 3.0 Unported License (CC BY 3.0) (<https://creativecommons.org/licenses/by/3.0/>)

## Abstract

**Background.** Patients who are partially dentate or edentulous can receive both conventional and implant-supported fixed prostheses, which leads to improvement in function, esthetics and self-esteem. Currently, implant dentistry is one of the fastest-growing disciplines in dentistry.

**Objectives.** The aim of the study was to assess the education and training of dentists practicing implant therapy in the Riyadh region of Saudi Arabia, including their preferred dental implant systems, the clinical complications experienced as well as the barriers to implant therapy they encounter.

**Material and methods.** A self-administered questionnaire was distributed among dentists in Riyadh performing dental implants in both the state and private sectors. The questionnaire included demographic data, such as nationality, the practitioner's affiliated specialist category and their respective qualifications. Other data included their main sources of education pertaining to implant dentistry, the most commonly used implant systems, common clinical complications, and barriers to implant therapy. A descriptive statistical analysis of the data was carried out.

**Results.** A significant majority of non-Saudi dental practitioners were employed in the private sector ( $p = 0.001$ ), whereas a significant majority of Saudi dental practitioners were employed in the state sector ( $p = 0.001$ ). The largest group of practitioners performing implants were general dentists (48.1%). The 3i™ implant system was the most widely utilized (35.4%). Failed osseointegration (12.6%) and peri-implantitis (12%) were the most common clinical complications. The biggest barrier to placing implants was the cost of implants to patients (59.1%).

**Conclusions.** Fundamental to implant practice is the clinical practitioner and patient selection. The utilization of implant systems should preferably be based on the chemical properties of implant surfaces which promote early osseointegration. Comparative studies investigating the reasons for failed osseointegration and other clinical complications are needed locally and internationally. Further research, together with advanced clinical specialist training, can lead to improvement in the quality of implant therapy for the benefit of patients.

**Key words:** implant practice survey, implant systems, implant complications, hydrophilic implants, hydrophobic implants

**Słowa kluczowe:** przegląd praktyk implantologicznych, systemy implantologiczne, powikłania implantologiczne, implanty hydrofilowe, implanty hydrofobowe



## Introduction

The replacement of lost teeth is achievable by utilizing removable partial dentures, complete dentures, overdentures, and fixed partial prostheses. Expanded treatment options available to the general population suffering from tooth loss include implant therapy.<sup>1</sup> Partially dentate and edentulous patients may significantly benefit from the placement of implants in terms of both esthetics and function.<sup>2</sup>

Male patients in Saudi Arabia complained that tooth loss affected their profile as well as the chewing function.<sup>3</sup> A study in Saudi Arabia reported that 61.5% of the participants believed that the utilization of dental implants was the best treatment option for replacing missing teeth.<sup>4</sup> Another study in Riyadh revealed that 75.7% of the respondents would willingly undergo implant therapy again, and 79.3% would encourage others to consider implant treatment.<sup>5</sup>

In both Saudi Arabia and elsewhere, few studies regarding the practice of implant dentistry refer to the practitioners' level of education. There is every indication that the majority of oral surgeons perform implants, followed by periodontists and general dental practitioners (GDPs).<sup>6-8</sup> Education and training in implant dentistry in different countries can also vary, including undergraduate and formal post-graduate training, fellowship/board training as well as the attendance of courses and/or seminars.<sup>8</sup>

The choice of implant system utilized also varies between studies and is determined by different factors. Practicing dentists placing implants may be employed either in the private sector or in state institutions, where budget constraints may limit the choice of implant system to be used.<sup>8</sup> Other factors may be the consideration of long-term implant success rates as well as the financial barriers experienced by patients.<sup>4,8</sup> However, the cost of implants has been given the lowest priority by practicing dentists when choosing an implant system, especially in the private sector.<sup>9</sup>

Implant therapy complications resulting in the loss or failure of implants are attributed to inaccurate treatment planning, surgical mistakes or improper prosthodontic restoration.<sup>9</sup> The reported complications include dehiscence/fenestration, gingival inflammation and fistulae. Surgical complications such as hemorrhage and neurosensory disturbances have also been reported.<sup>10</sup> The prevalence of peri-implantitis as a complication varies from study to study.<sup>8,11,12</sup> This may be due to the inconsistencies in the precise diagnoses of peri-implantitis and peri-implant mucositis in different clinical settings.<sup>8</sup> Implant placement location, poor oral hygiene, the patient's medical condition, and patient noncompliance are also reasons that may underlie implant therapy complications.<sup>7,8,13</sup>

A recent study in the Eastern Province of Saudi Arabia indicated that far more non-Saudis than Saudis practiced implant dentistry.<sup>8</sup> This was attributed to the

recruitment of a large number of non-Saudi dentists into the private sector due to an increased demand for implant therapy. The study reported that the largest proportion of dentists performing implants were oral surgeons (44.7%), followed by GDPs (21.1%), periodontists (18.4%), and prosthodontists (13.2%).<sup>8</sup> It was therefore the purpose of the present study to assess the education and training of dentists practicing implant therapy in the Riyadh region of Saudi Arabia, including their preferred dental implant systems, the clinical complications experienced and the barriers to implant therapy they encounter. This would allow us to compare the practice of implant therapy in the Riyadh region to that in the Eastern Province of Saudi Arabia.

## Material and methods

The study was conducted between May 2017 and March 2018. A self-administered English-language questionnaire was distributed among practicing dental practitioners currently placing dental implants. The practitioners were working in state hospitals, and in various private centers in and around the city of Riyadh. Access and permission to distribute the questionnaires was obtained from both the state and private institutions.

The questionnaire included demographic data to ascertain the total number of practicing dentists performing both stage 1 and stage 2 of implant surgery. Their respective qualifications including their specialist category were also noted. Saudi and non-Saudi practitioners were differentiated, as were state and private sectors.

The questionnaire also referred to the practitioners' main source of education pertaining to implant dentistry as well as the most commonly used implant systems. The most common clinical complications experienced by practitioners were investigated as well as the barriers to implant therapy they encountered. A descriptive statistical analysis was carried out using IBM SPSS Statistics for Windows, v. 22.0. (IBM Corp., Armonk, USA). Statistical significance was set at 0.05.

## Results

Out of a total of 248 questionnaires, 192 were completed, signifying a response rate of 77.4%. The majority of the respondents were male ( $n = 127$ ; 66.1%). Non-Saudi dental practitioners were in the majority (56.6%), with a significant proportion employed in the private sector (89.2%;  $p = 0.001$ ). A significant majority of Saudi dental practitioners, however, were employed in the state sector (82.14%;  $p = 0.001$ ).

Formal education regarding implant placement was reported to consist mostly of post-graduate training during the acquisition of a Master's degree (43.2%), followed by

the attendance of courses and/or seminars (30.7%), undergraduate training (13%), fellowship/board training (9.9%), and doctoral studies (8.3%).

Of a total of 192 respondents placing implants, 48.1% were GDPs, 30.8% periodontists, 11.9% oral surgeons, 5.4% prosthodontists, and 3.8% restorative specialists. The percentage distribution of the qualifications held by the listed proportions of the practitioners is depicted in Fig. 1. The highest qualification held by the majority of GDPs was a Bachelor's degree (90.9%), that held by the majority of periodontists and oral surgeons was a Master's degree (57.9% and 61.9%, respectively), and that held by the largest number of prosthodontists was a fellowship (50%). The largest number of restorative specialists held either a Master's degree (42.86%) or a fellowship (42.86%).

Regarding the dental implant systems being used, it was found that the 3i™ system was the most commonly used (35.4%), followed by Astra Tech™ (22.4%), Osstem® (10.4%), Noble Biocare™ (9.4%), Straumann® (7.8%), and Zimmer® (5.2%) (Fig. 2).

Regarding the criteria for selection when considering a specific implant system, 18.3% of the respondents reported that the particular implant system was chosen by the administration of their hospital and/or clinic, followed by the popularity of the system (15.7%), easy handling (7.3%) and the long-term prognosis (5.7%).

The consideration of costs (1.04%) and esthetics (1.04%) were given the lowest priority by the practitioners (Table 1).

Of the respondents, both state and private employees, who reported performing implants every month (Fig. 3):

- 25.5% stated that they placed an average of 1–5 implants/month;
- 31.2% – 6–10 implants/month;
- 17.1% – 11–15 implants/month;
- 10.4% – 16–20 implants/month;
- 14.3% – >20 implants/month.

The most common clinical situation for the placement of implants was single posterior tooth loss (89%), followed by single anterior tooth loss (71%), edentulous

Table 1. Implant system selection criteria in terms of the percentage of practicing dentists

Implant system selection criteria	Percentage of practicing dentists [%]
Hospital/clinic administration	18.3
Popularity of the system	15.7
Easy handling	7.3
Long-term prognosis	5.7
Cost	1.04
Esthetics	1.04

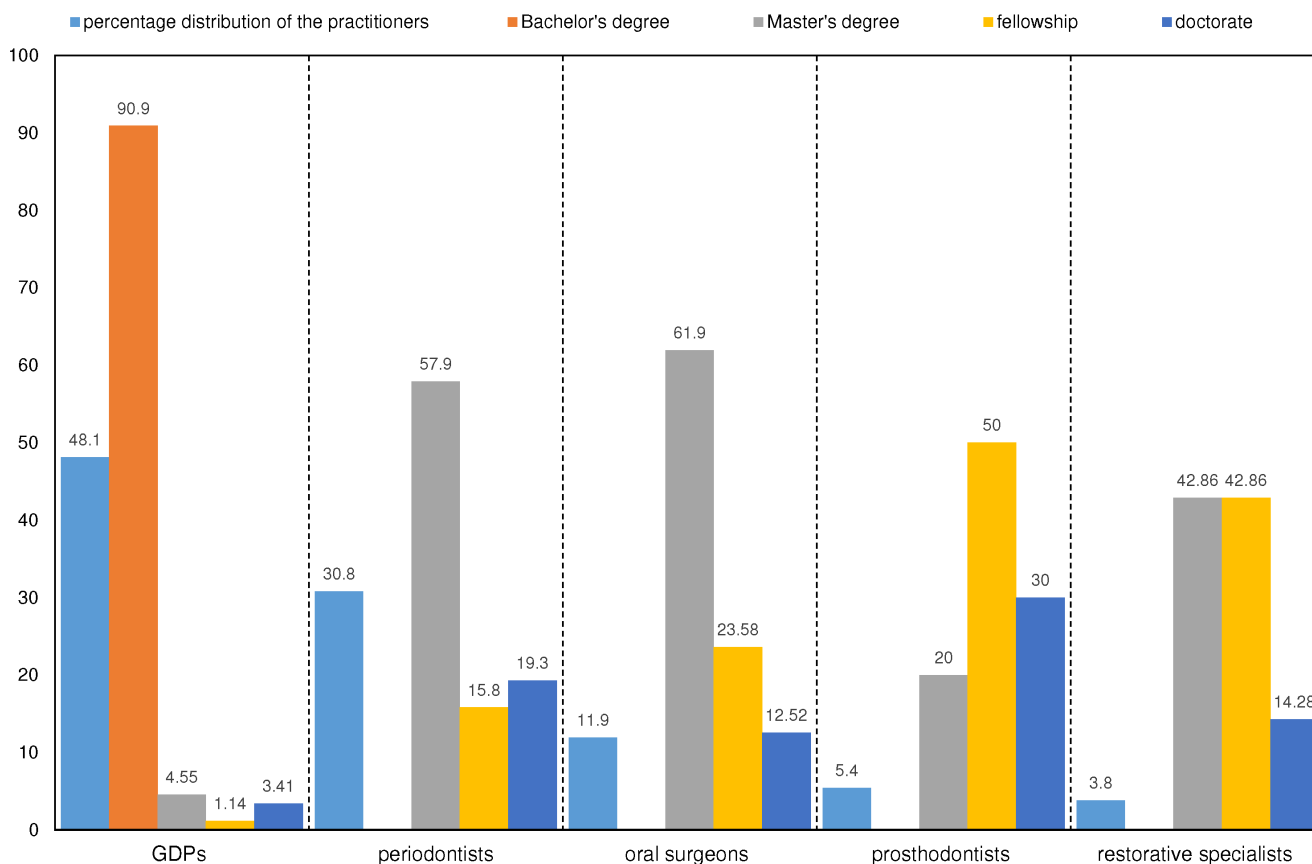


Fig. 1. Percentage distribution of qualifications held by the percentage proportions of practitioners  
GDP – general dental practitioner.

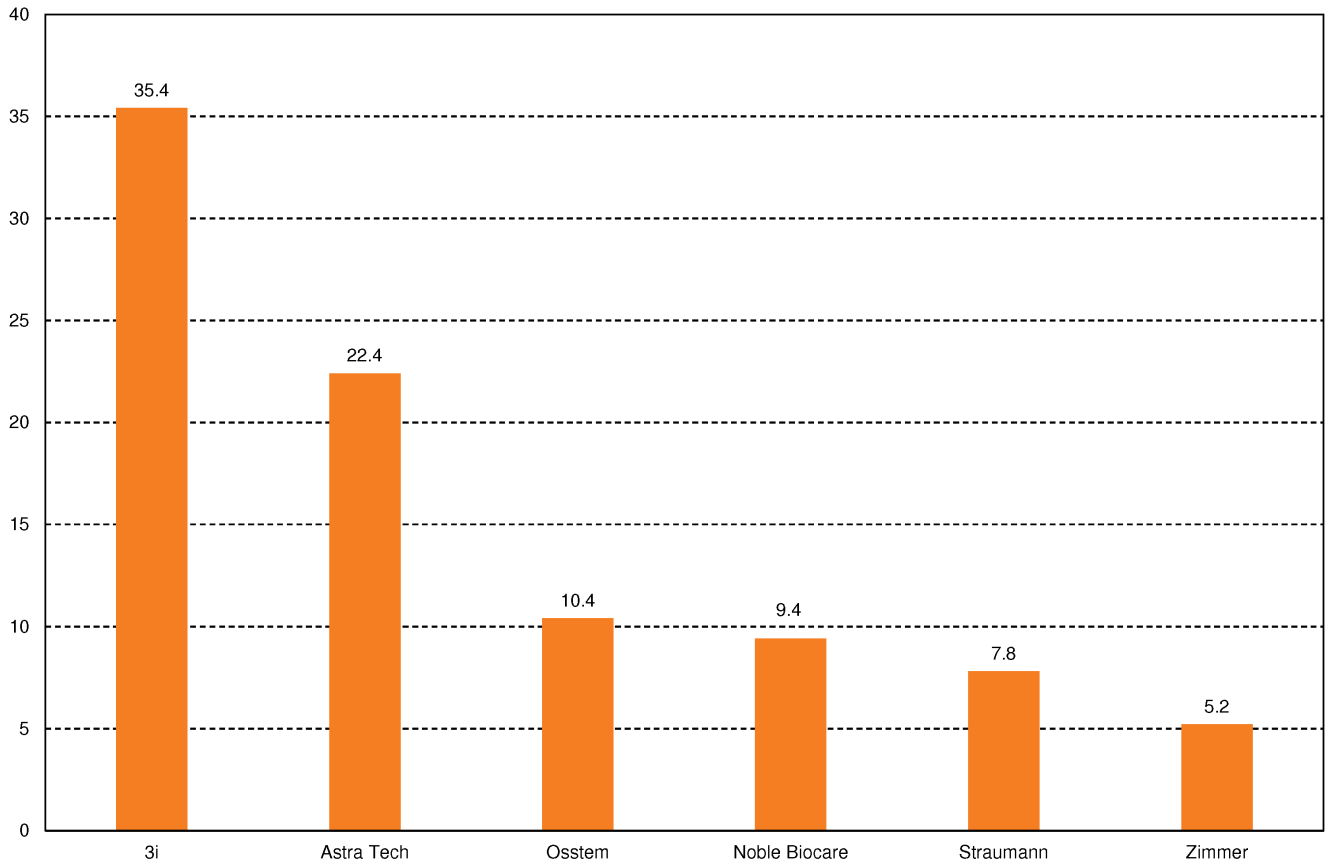


Fig. 2. Percentage distribution of the implant systems used

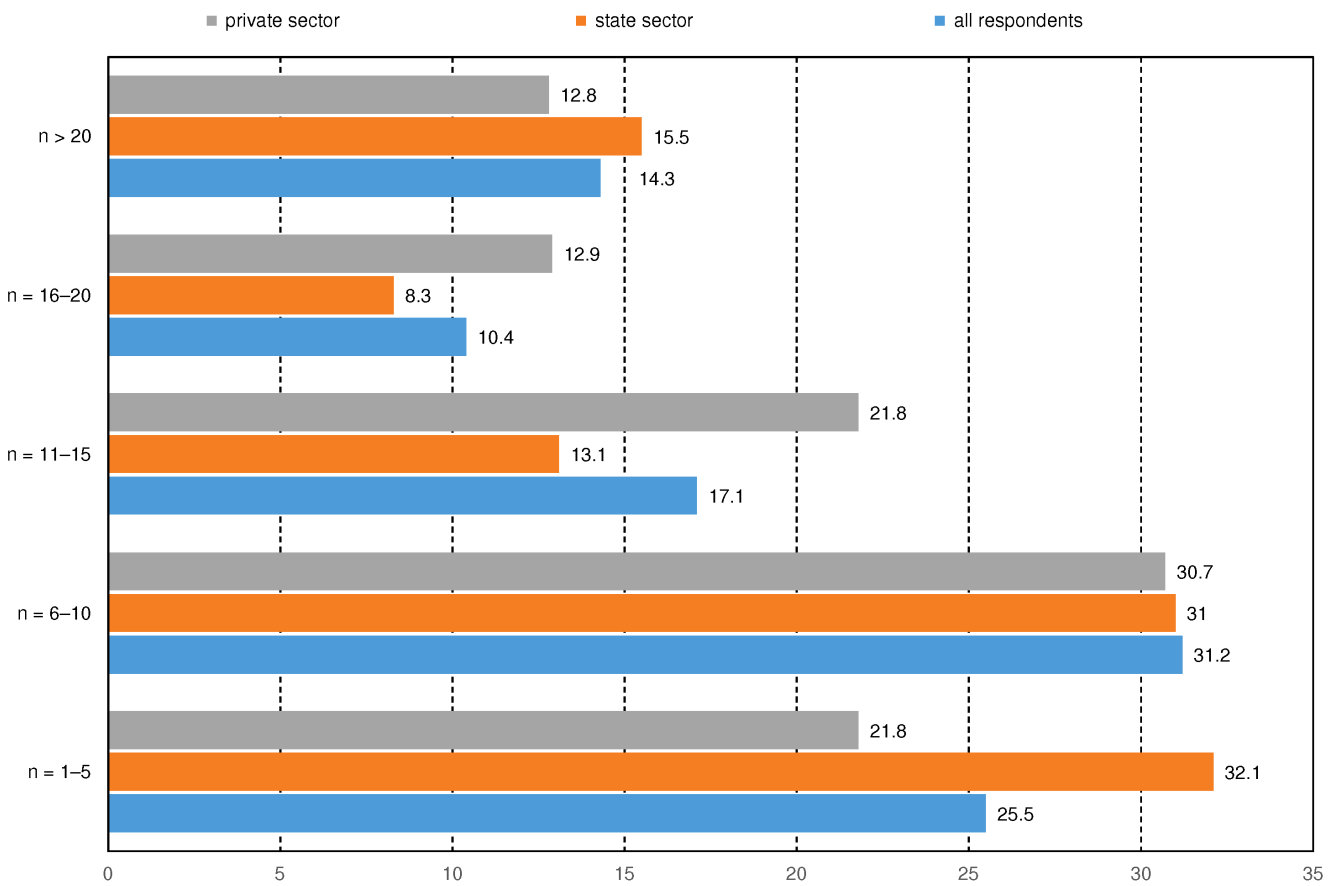


Fig. 3. Percentage distribution of respondents placing n number of implants per month

cases (56.5%), free-end saddles (42.4%), multiple tooth loss (39.8%), and abutments for either fixed partial dentures (FPDs) or overdentures (26.9%) (Table 2). In this study, the lower first molar was the most common posterior tooth to be replaced with an implant. The recommendation of substituting missing teeth with implants as the first choice of treatment was reported by 87.8% of the respondents, in contrast to utilizing FPDs or removable dentures.

Common challenges encountered before the surgical placement of implants were reported to be low sinus levels (38.4%), smoking (15.6%), the patient's medical condition (15.1%), the severity of bone loss (11.9%), the presence of gingivitis/periodontal disease (7.8%), and a high caries risk (6.2%) (Table 2).

The biggest barrier to performing implant surgery was the cost of implants to the patient, reported by 59.1% of the respondents, followed by the patient's fear (9.9%), a shortage of equipment (6.8%), and a lack of time reported by the patient (1.6%). (Table 2).

The clinical complications most frequently encountered after implant surgery were reported to be failed osseointegration (12.6%), peri-implantitis (12%) and peri-implant mucositis (9.3%). This was followed by dehiscence/fenestration (7.3%) and local infection (6.7%). The underlying reasons for these clinical complications as perceived by the respondents were patient noncompliance, poor oral hygiene and smoking (24.5%). Other indicated reasons

were periodontal diseases and infection (22.9%), followed by improper implant placement and the practitioner's inexperience (20.8%).

Regarding the referral of patients for the management of unexpected complications, 74.3% of all respondents reported that they referred their patients for the appropriate treatment of any clinical complications. Of these, the highest referral rate (91%) was reported among GDPs, followed by restorative specialists (85.7%), oral surgeons (63.6%) and periodontists (56.3%). Prosthodontists had the lowest referral rate (40%).

## Discussion

The population of Saudi Arabia was estimated to be 33.5 million in 2018. The demand for implant therapy has been increasing in the Saudi population.<sup>4</sup> Al-Houtan et al. in their study investigated implant therapy practices in the Eastern Province of Saudi Arabia, which is the largest administrative area in the country.<sup>8</sup> The Eastern Province has an estimated population of 4.6 million, distributed over 5 cities in the region. The total number of dentists placing implants in the Eastern Province is estimated to be 55. The survey-based study in the Eastern Province had a response rate of 69% (n = 38), which was regarded as weak.<sup>8</sup> On the other hand, the city of Riyadh – the capital and the largest city in the country, situated in the central part of Saudi Arabia – alone has an estimated population of 4.21 million.<sup>14</sup> The total number of dentists placing implants in Riyadh is estimated to be 248. The response rate in the present study was 77.4% (n = 192). Although the response rates in these 2 studies may seem to be comparable, the number of respondents in the present study is considered more acceptable.

The prevalence of clinical complications may vary between studies, both on a local and international basis. In the present study, failed osseointegration was the most commonly reported complication, along with peri-implantitis. The Eastern Province study also reported peri-implantitis as the main clinical complication.<sup>8</sup> Other studies with larger population samples did not, however, uphold this tendency.<sup>11,12,15</sup> Patient noncompliance and poor oral hygiene were identified as the main reasons underlying these clinical complications in both of the Saudi Arabian studies as well as in a study conducted in Sweden.<sup>7</sup> Also, in the present study, periodontal diseases, infection, improper implant placement, and the inexperience of practitioners were highlighted as causes of complications.

In this study, a high referral rate was reported by GDPs for the treatment of the complications they encountered. A more thorough understanding and knowledge of potential clinical complications is needed, which means that further research regarding implant practices and complications, with larger sample sizes, both regionally and in-

**Table 2.** Clinical indications, pre-surgical challenges and barriers encountered in terms of the percentage of practicing dentists

Clinical indications, pre-surgical challenges and barriers	Percentage of practicing dentists [%]
<b>Clinical indications</b>	
Single posterior tooth loss	89.0
Single anterior tooth loss	71.0
Edentulism	56.5
Free-end saddle	42.4
Multiple tooth loss	39.8
Abutment for FPD/overdenture	26.9
<b>Pre-surgical challenges</b>	
Low sinus levels	38.4
Smoking	15.6
Patient's medical condition	15.1
Severity of bone loss	11.9
Gingivitis/periodontal disease	7.8
High caries risk	6.2
<b>Barriers</b>	
Cost of implants to the patient	59.1
Patient's fear	9.9
Shortage of equipment	6.8
Lack of time for the patient	1.6

FPD – fixed partial denture.

ternationally, should be conducted. Furthermore, from an educational perspective, in both the present study and the Eastern Province study, the attendance of courses and/or seminars was listed by a large proportion of the respondents as part of their training in implant placement. The increased popularity of such courses was described in another study.<sup>16</sup> However, as the Eastern Province study pointed out, the ideal practitioner to place implants is a surgically trained periodontist or oral surgeon.<sup>8</sup> Therefore, it should be reiterated that such courses and seminars should concentrate on considering the complexity of the various aspects of implant planning and surgical placement as well as the involved difficulties. This would allow the future development of complications and compromises in the quality of implant therapy to be avoided to a larger extent.<sup>8</sup>

Further comparisons between the present study in Riyadh with the Eastern Province study reveal certain major differences (Table 3). The predominant gender practicing implant dentistry in both studies was male; however, a larger pro rata percentage of males is evident in the Eastern Province (81.6%).<sup>8</sup> This may be attributed retrospectively to a larger number of dental schools in Riyadh, qualifying more female students. These Riyadh schools have been open significantly longer than dental schools in the Eastern Province. Only recently have female students been graduating from schools in the Eastern Province. It may also be postulated that more male dentists are recruited into the private sector in the Eastern Province.

Of all practicing dentists in Riyadh, a smaller percentage were in private practice (54.8%) as compared to the Eastern Province (65.8%). However, due to the sample sizes in the 2 studies ( $n = 192$  and  $n = 38$ , respectively), there was a much larger number of private practitioners in Riyadh. This may possibly be ascribed to the Riyadh region being more affluent than the Eastern Province.

The Riyadh region had a larger proportion of Saudi nationals practicing implant dentistry as compared to the Eastern Province. However, there is still a slightly higher proportion of non-Saudis practicing implant dentistry, albeit fewer than in the Eastern Province. Riyadh has a larger population, with more state and private teaching dental hospitals than the Eastern Province. It is under-

standable that Saudis who are permanently resident and educated in Riyadh would prefer to remain and practice in Riyadh.

A larger number of implants were being placed in Riyadh as compared to the Eastern Province. Riyadh has a far greater population than any of the 5 cities in the Eastern Province, along with a larger number of practicing dentists placing implants. The demand for implant therapy is therefore expected to be higher. A survey conducted in Riyadh indicated the increased popularity of implants as a treatment option, with wide acceptance and a high level of satisfaction expressed after placement.<sup>4</sup>

The present study found that the majority of practitioners placing implants in Riyadh were GDPs, whereas in the Eastern Province, implants are mostly placed by oral surgeons. The reasons for this tendency may be twofold. Firstly, there is a greater number of both state and private dental schools in the Riyadh region as compared to the Eastern Province, so by implication, more Saudi GDPs are being qualified. Secondly, this study showed that a significant majority of non-Saudi dental practitioners were employed in the private sector (89.2%), and the majority of GDPs in Riyadh are non-Saudis. This may be ascribed to a higher number of non-Saudi GDPs being recruited to the private sector in Riyadh as compared to the Eastern Province.

Both locally and internationally, the factors influencing the choice of implant system may vary. A greater proportion of practicing dentists in Riyadh utilize the 3i system, whereas in the Eastern Province, the Straumann system is more frequently used. The reasons for different implant systems being preferred in these 2 regions in the same country are not clear. In this study, the popularity of the system, easy handling in use and the long-term prognosis were among the reasons for the choice of implant system. A limitation of this study regarding the choice of implant system is the absence of any investigation of whether the preferred use was based on published scientific literature that included clinical data. Studies in other countries also indicated the preferential use of particular implant systems, such as Noble Biocare and Straumann.<sup>17,18</sup> The use of a particular implant system during the practitioner's specialist training, the influence of aggressive commer-

**Table 3.** Comparison of implant practices between Riyadh and the Eastern Province of Saudi Arabia

Difference	Riyadh	Eastern Province of Saudi Arabia
Predominant gender of the practitioners placing implants	male (67.2%)	male (81.6%)
Employment sector	private (54.8%)	private (65.8%)
Percentage of non-Saudi practitioners	56.6%	68.4%
Number of practitioners placing 6–10 implants per month	57 (342–570 implants)	13 (78–130 implants)
Practitioners placing the most implants	GDPs (48.1%)	oral surgeons (44.7%)
Implant system mostly used	3i (35.4%)	Straumann (34.2%)
Clinical complication encountered most frequently	failed osseointegration (12.6%)	peri-implantitis (23.7%)

cial marketing, lower costs as well as personal preferences for specific implant systems, for example due to restorative convenience, may underlie this tendency. Globally, implant manufacturers profess that their various implant systems have ‘the best’ physicochemical, biological and clinical properties.<sup>19</sup> However, the current basis for implant treatment protocols is early osseointegration, which comprises the immediate and early loading of implants.<sup>19</sup> The enhancement of the bone-to-implant contact (BIC) interface is an important parameter affecting the speed of osseointegration.<sup>20</sup> The modification of the topographical features of dental implant surfaces at the micro- and nanoscale can significantly improve BIC and bone anchorage at the early stages of osseointegration.<sup>19</sup> Hydrophilicity has been shown to positively affect the initial stages of wound healing during osseointegration, whereby the adsorption of plasma proteins essential for the initial osteogenic interaction is accomplished.<sup>21</sup> This leads to beneficial gene expression, intense and rapid osteogenesis, bone mineralization, and early osseointegration.<sup>19,22</sup> Various studies compared hydrophobic and hydrophilic implant surfaces having the same microtopography. These studies concluded that osseointegration was enhanced by super-hydrophilic surfaces, demonstrating a stronger bone response in comparison with hydrophobic surfaces with the same topographical features.<sup>20,23</sup>

Surface chemistry that promotes hydrophilicity, and not micro-surface topography, has been shown to accelerate implant osseointegration and increase BIC.<sup>19,20,23</sup> Surface chemistry potentially alters ionic interactions, protein adsorption and cellular activity at the implant surface.<sup>24</sup> Protein adsorption at the implant surface influences the attachment and migration of cells. A higher affinity to individual protein molecules, which influences the bonding strength and maintains the conformation, orientation and function of these proteins, is exerted on hydrophilic surfaces than on hydrophobic ones.<sup>25,26</sup> This is of considerable importance, since initial protein interactions with the implant surface largely mediate the impact of hydrophilicity on cellular and tissue reactions toward biomaterials.<sup>25</sup> This includes biological signals activating and expressing the receptors located on the membranes of cells, subsequently determining initial cellular attachment as well as cell proliferation and differentiation.<sup>25</sup> Hydrophobic surfaces, however, may induce the denaturation of proteins by bringing about conformational changes.<sup>27,28</sup>

Various studies found that hydrophilic surfaces enhance the early stages of cell adhesion, proliferation and differentiation as well as bone mineralization as compared to hydrophobic surfaces.<sup>29</sup> This includes promoting the differentiation and maturation of osteoblasts, thereby contributing to accelerated osseointegration, as well as initializing the earlier onset of secondary implant stability.<sup>28,30</sup> Furthermore, other studies described a significantly lower overall early failure rate of hydrophilic implants as compared to hydrophobic ones.<sup>31</sup> The majority of implant

surfaces currently being utilized in clinical practice are hydrophobic.<sup>25,32,33</sup> The examples of hydrophobic implants are 3i, Astra Tech, Straumann, and Dentsply Friadent; the examples of hydrophilic implants are Astra Tech, Osstem, Nobel Biocare, and Straumann.<sup>25</sup>

Lastly, in the present study, failed osseointegration was recorded as the most common clinical complication (12.6%), as compared to the Eastern Province study, which reported peri-implantitis to be more common. However, due to the larger total number of implants placed in Riyadh (between 342 and 570 per month), along with the similar reported prevalence of peri-implantitis (12%) among the Riyadh patients, failed osseointegration may be ascribed to poor patient compliance, smoking and bad oral hygiene, as reported in this study.

## Conclusions

The majority of practitioners placing implants in Riyadh were GDPs. Failed osseointegration and peri-implantitis were the most common clinical complications. The cost of implants to patients was the biggest barrier to placing implants.


The practice of implant placement can differ from one region to another, both locally and internationally. However, what is fundamental is the choice of implant system. It should be based on factors that promote early osseointegration for the purpose of the immediate and early loading of implants. Therefore, consideration should be given to the advantages of chemically modified surfaces that promote hydrophilicity, rather than to the topographical features alone. Implant placement, as practiced by various qualified clinicians, also involves the aspects of patient selection and clinical complications. Studies with larger sample sizes are needed to ascertain and compare the demand and practice of implant placement in other regions of Saudi Arabia.


Additional comparative research should be undertaken on a local as well as international basis. The research should incorporate patient selection, restorative planning and the surgical placement of implants as well as the prevalence and reasons for implant complications and failures. Appropriate patient selection for implant therapy cannot be overemphasized. By this means, additional knowledge, insight and expertise regarding proficiency in clinical therapeutic guidelines may be further developed. This knowledge, in addition to advanced clinical specialist training, will inevitably lead to the improvement in the quality of implant therapy for the benefit of patients.

### ORCID iDs

Rajaa Abdullah Albugami  <https://orcid.org/0000-0003-3553-6385>

Steph Smith  <https://orcid.org/0000-0002-1093-8727>

Mohammed Al-Sheikh Hassan  <https://orcid.org/0000-0001-7020-1156>

Khalid Almas  <https://orcid.org/0000-0002-2552-587X>

## References

- Amjad F, Aziz S. Trends, awareness, and attitudes of patients towards replacement of missing teeth at University College of Dentistry. *Pakistan Oral & Dental Journal*. 2014;34(1):190–193.
- Nickenig HJ, Wichmann M, Terheyden H, Kreppel M. Oral health-related quality of life and implant therapy: A prospective multicenter study of preoperative, intermediate, and posttreatment assessment. *J Craniomaxillofac Surg*. 2016;44(6):753–757.
- Akeel R. Attitudes of Saudi male patients toward the replacement of teeth. *J Prosthet Dent*. 2003;90(6):571–577.
- Al-Johany S, Al Zoman HA, Al Juhaini M, Al Refeai M. Dental patients' awareness and knowledge in using dental implants as an option in replacing missing teeth: A survey in Riyadh, Saudi Arabia. *Saudi Dent J*. 2010;22(4):183–188.
- Al-Hamdan K, Meshrif H. Patient's satisfaction with dental implants in Riyadh, Saudi Arabia. *Saudi Dent J*. 2007;19(2):91–96.
- Akeredolu PA, Adeyemo WL, Gbotolorun OM, James O, Olorunfemi BO, Arotiba GT. Knowledge, attitude and practice of dental implantology in Nigeria. *Implant Dent*. 2007;16(1):110–118.
- Derks J, Schaller D, Håkansson J, Wennström JL, Tomasi C, Berglundh T. Effectiveness of implant therapy analyzed in a Swedish population: Prevalence of peri-implantitis. *J Dent Res*. 2016;95(1):43–49.
- Al-Houtan T, Smith S, Almas K. Survey of dental implant practices in the Eastern Province of Saudi Arabia. *Odontostomatol Trop*. 2018;41(163):31–41.
- Academy Report. Peri-implant mucositis and peri-implantitis: A current understanding of their diagnoses and clinical implications. *J Periodontol*. 2013;84(4):436–443.
- Goodacre CJ, Bernal G, Rungcharassaeng K, Kan JY. Clinical complications with implants and implant prostheses. *J Prosthet Dent*. 2003;90(2):121–132.
- Mir-Mari J, Mir-Orfila P, Figueiredo R, Valmaseda-Castellón E, Gay-Escoda C. Prevalence of peri-implant diseases. A cross-sectional study based on a private practice environment. *J Clin Periodontol*. 2012;39(5):490–494.
- Atieh MA, Alsabeeha NH, Faggion CM Jr, Duncan WJ. The frequency of peri-implant diseases: A systematic review and meta-analysis. *J Periodontol*. 2013;84(11):1586–1598.
- Vohra F, Habib R. Knowledge and attitude of dentists toward implant retained restorations in Saudi Arabia. *Niger J Clin Pract*. 2015;18(3):312–317.
- Global Media Insight. Posted in Infographics, 2018. <https://www.globalmediainsight.com/blog/saudi-arabia-population-statistics/>. Accessed December 3, 2018.
- Simonis P, Dufour T, Tenenbaum H. Long-term implant survival and success: A 10–16-year follow-up of non-submerged dental implants. *Clin Oral Implants Res*. 2010;21(7):772–777.
- Brandt RI, Fitzpatrick BJ, Moloney FB, Bartold PM. Continuing dental education in osseointegrated implants. A survey. *Austral Dent J*. 2000;45(4):285–288.
- Shah RJ, Shah SG, Patel GC. Trends in implant dentistry among private dental practitioners of Gujarat: A survey. *J Dent Imp*. 2014;4(1):48–52.
- Lambrecht JT, Cardone E, Kühl S. Status report on dental implantology in Switzerland in 2006. A cross-sectional survey. *Eur J Oral Implantol*. 2010;3(1):71–74.
- Sartoretto SC, Alves AT, Resende RF, Calasans-Maia J, Granjeiro JM, Calasans-Maia MD. Early osseointegration driven by the surface chemistry and wettability of dental implants. *J Appl Oral Sci*. 2015;23(3):279–287.
- Wennerberg A, Jimbo R, Stübinger S, Obrecht M, Dard M, Berner S. Nanostructures and hydrophilicity influence osseointegration: A biomechanical study in the rabbit tibia. *Clin Oral Implants Res*. 2014;25(9):1041–1050.
- Vasak C, Busenlechner D, Schwarze UY, et al. Early bone apposition to hydrophilic and hydrophobic titanium implant surfaces: A histologic and histomorphometric study in minipigs. *Clin Oral Impl Res*. 2014;25(12):1378–1385.
- Donos N, Hamlet S, Lang NP, et al. Gene expression profile of osseointegration of a hydrophilic compared with a hydrophobic micro-rough implant surface. *Clin Oral Implants Res*. 2011;22(4):365–372.
- Lang NP, Salvi GE, Huynh-Ba G, Ivanovski S, Donos N, Bosshardt DD. Early osseointegration to hydrophilic and hydrophobic implant surfaces in humans. *Clin Oral Implants Res*. 2011;22(4):349–356.
- Schliephake H, Scharnweber D, Dard M, Sewing A, Aref A, Roessler S. Functionalization of dental implant surfaces using adhesion molecules. *J Biomed Mater Res B Appl Biomater*. 2005;73(1):88–96.
- Gittens RA, Scheideler L, Rupp F, et al. A review on the wettability of dental implant surfaces II: Biological and clinical aspects. *Acta Biomater*. 2014;10(7):2907–2918.
- Wilson CJ, Clegg RE, Leavesley DI, Percy MJ. Mediation of biomaterial-cell interactions by adsorbed proteins: A review. *Tissue Eng*. 2005;11(1–2):1–18.
- Terheyden H, Lang NP, Bierbaum S, Stadlinger B. Osseointegration – communication of cells. *Clin Oral Implants Res*. 2012;23(10):1127–1135.
- Smeets R, Stadlinger B, Schwarz F, et al. Impact of dental implant surface modifications on osseointegration. *Biomed Res Int*. 2016;2016:6285620.
- Eriksson C, Nygren H, Ohlson K. Implantation of hydrophilic and hydrophobic titanium discs in rat tibia: Cellular reactions on the surfaces during the first 3 weeks in bone. *Biomaterials*. 2004;25(19):4759–4766.
- Zhao G, Schwartz Z, Wieland M, et al. High surface energy enhances cell response to titanium substrate microstructure. *J Biomed Mater Res A*. 2005;74(1):49–58.
- Le Gac O, Grunder U. Six-year survival and early failure rate of 2918 implants with hydrophobic and hydrophilic enossal surfaces. *Dent J (Basel)*. 2015;3(1):15–23.
- Rupp F, Scheideler L, Eichler M, Geis-Gerstorfer J. Wetting behavior of dental implants. *Int J Oral Maxillofac Implants*. 2011;26(6):1256–1266.
- Palmquist A, Engqvist H, Lausmaa J, Thomsen P. Commercially available dental implants: Review of their surface characteristics. *J Biomater Tissue Eng*. 2012;2(2):112–124.

# Validation of a modified Oral Health Impact Profile scale (OHIP-14) in patients with oral mucosa lesions or periodontal disease

## Walidacja zmodyfikowanego wskaźnika profilu zdrowia jamy ustnej (OHIP-14) u pacjentów z chorobami błony śluzowej jamy ustnej lub periodontopatiami

Katarzyna Wąsacz<sup>1,A–F</sup>, Agnieszka Pac<sup>2,C,E,F</sup>, Dagmara Darczuk<sup>1,B,E,F</sup>, Maria Chomyszyn-Gajewska<sup>1,A,E,F</sup>

<sup>1</sup> Department of Periodontology and Oral Medicine, Institute of Dentistry, Jagiellonian University Medical College, Kraków, Poland

<sup>2</sup> Department of Epidemiology and Preventive Medicine, Jagiellonian University Medical College, Kraków, Poland

A – research concept and design; B – collection and/or assembly of data; C – data analysis and interpretation; D – writing the article; E – critical revision of the article; F – final approval of the article

Dental and Medical Problems, ISSN 1644-387X (print), ISSN 2300-9020 (online)

*Dent Med Probl.* 2019;56(3):231–237

### Address for correspondence

Katarzyna Wąsacz

E-mail: katarzyna.wasacz@doctoral.uj.edu.pl

### Funding sources

None declared

### Conflict of interest

None declared

Received on March 6, 2019

Reviewed on April 22, 2019

Accepted on May 15, 2019

Published online on July 31, 2019

### Cite as

Wąsacz K, Pac A, Darczuk D, Chomyszyn-Gajewska M. Validation of a modified Oral Health Impact Profile scale (OHIP-14) in patients with oral mucosa lesions or periodontal disease. *Dent Med Probl.* 2019;56(3):231–237. doi:10.17219/dmp/109388

### DOI

10.17219/dmp/109388

### Copyright

© 2019 by Wrocław Medical University

This is an article distributed under the terms of the

Creative Commons Attribution 3.0 Unported License (CC BY 3.0)

(<https://creativecommons.org/licenses/by/3.0/>)

## Abstract

**Background.** Now that healthcare systems have helped successfully extend the human lifespan, the next challenge is to improve the patient's quality of life (QOL), in particular health-related quality of life (HRQOL). A proper HRQOL assessment requires using reliable instruments that are well-adapted to the population.

**Objectives.** The objective of this study was to validate a modified Polish version of the Oral Health Impact Profile scale (OHIP-14) for patients with oral mucosa lesions or periodontal disease.

**Material and methods.** The sample consisted of 180 adults seeking highly specialized treatment at the Periodontology Department of the University Dental Clinic in Kraków, Poland. The main modification made to OHIP-14 was the inclusion of subquestions regarding the teeth (subscale 1), oral mucosa and other soft tissues (subscale 2), and dentures (subscale 3).

**Results.** The Cronbach's alpha values were excellent for all 3 subscales (subscale 1:  $\alpha = 0.924$ ; subscale 2:  $\alpha = 0.937$ ; subscale 3:  $\alpha = 0.936$ ). In the case of subscale 1, the Kaiser criterion showed a model with 3 factors ("psychological and social limitations"; "physical limitations"; "functional limitations"), which together explained 67.1% of the variance, in the case of subscale 2 – a model with 1 factor, and in the case of subscale 3 – a 2-factor model ("social interactions limitations"; "basic activities disorder and personal discomfort").

**Conclusions.** Statistical testing demonstrated that a modified OHIP-14 questionnaire is a reliable tool for evaluating QOL in patients with periodontal or oral mucosa diseases.

**Key words:** oral health, periodontal disease, validation, health-related quality of life

**Słowa kluczowe:** zdrowie jamy ustnej, choroby przyzębia, walidacja, jakość życia związana ze zdrowiem fizycznym



## Introduction

Now that healthcare systems have helped successfully extend the human lifespan, the next challenge is to improve the patient's quality of life (QOL), in particular health-related quality of life (HRQOL). This goal accords with the World Health Organization's own definition of health, namely that "health is a state of complete physical, mental and social well-being, and not merely the absence of disease or infirmity".<sup>1</sup> The HRQOL assessment is based on the patient's own subjective evaluation and may significantly improve the patient's treatment (by improving compliancy and the physician-patient communication, and helping to focus more on the patient's needs, expectations and satisfaction),<sup>2,3</sup> but, at the same time, may also indicate suitable ways of improving the healthcare system itself.<sup>4</sup> This is especially important in the case of chronic diseases,<sup>5</sup> which may require regular medical appointments, longer treatment, some sacrifices, and changes in the patient's habits, which often need to be maintained for the rest of their life. A proper HRQOL assessment requires using reliable instruments that are well-adapted to the population. Many of these have already been developed to evaluate oral health-related quality of life (OHRQOL) in adults, e.g., Oral Health Impact Profile (OHIP-49,<sup>6</sup> OHIP-14<sup>7</sup>), Geriatric Oral Health Assessment Index (GOHAI),<sup>8</sup> Liverpool Oral Rehabilitation Questionnaire (LORQ),<sup>9,10</sup> and Chronic Oral Mucosal Diseases Questionnaire (COMDQ).<sup>11</sup>

The original English version of OHIP-14 was developed from OHIP-49 and validated by Slade.<sup>7</sup> Since then, this instrument has been applied in many different languages, e.g., German,<sup>12</sup> Italian,<sup>13</sup> Greek,<sup>14</sup> Turkish,<sup>15</sup> Japanese,<sup>16</sup> Vietnamese,<sup>17</sup> and Polish.<sup>18</sup> The original OHIP-14 is a self-administered questionnaire consisting of 14 items divided into 7 dimensions: functional limitation (items 1 and 2), physical pain (items 3 and 4), psychological discomfort (items 5 and 6), physical disability (items 7 and 8), psychological disability (items 9 and 10), social disability (items 11 and 12), and handicap (items 13 and 14). The respondents answer questions regarding the frequency of the factors that have impacted their QOL in the last 12 months and their responses are recorded on a 5-point Likert scale: never – 0; hardly ever – 1; occasionally – 2; fairly often – 3; very often – 4.

The aim of this study was to validate a modified Polish version of OHIP-14 in a population of patients with mucosal lesions or periodontal disease in order to make this scale applicable to this group.

## Material and methods

Two hundred and thirty-two adult patients looking for treatment at the Periodontology Department in the University Dental Clinic in Kraków, Poland, between

January 2017 and July 2018 were approached. Out of the 232 individuals, 180 agreed to participate in the study (a response rate of 77.6%). The study comprised a modified short Polish version of Oral Health Impact Profile (mOHIP-14-pl) and was part of a larger questionnaire-based study that included a clinical examination. The cross-cultural adaptation process of the English version of OHIP-14 was carried out according to the suggested guidelines.<sup>19</sup> The original questionnaire was translated into Polish by 2 persons with advanced English language skills, then the back-translation was performed and the review committee agreed on the final Polish version.

In this study, the authors used their own modified version of the standard OHIP-14 (Table 1) that features 2 adjustments. The first involved asking about the same items separately in relation to the teeth (subscale 1), oral mucosa and other soft tissues, e.g., gingiva or tongue (subscale 2), and dentures (subscale 3). The purpose of this modification was to explore the differences in the respondents' opinions, which could influence the clinical approach. The second adjustment concerned the inclusion of 2 additional answers: "I don't know", because some of the respondents found it difficult to determine the proper frequency of a given factor, and "not applicable", which was useful in the questions regarding the teeth in edentulous patients or dentures in patients who do not use any of them. Two supplementary answers were thus recorded: "I don't know" – 5 and "not applicable" – 6.

Each of the enrolled subjects was provided with detailed information about the study. All the participants gave their written informed consent. The exclusion criterion was only lack of consent. The study was approved by the Ethics Committee of the Jagiellonian University Medical College in Kraków, Poland (No. 122.6120.354.2016).

The data was analyzed using the IBM SPSS Statistics for Windows, v. 24 (IBM Inc., Armonk, USA). The reliability analysis based on Cronbach's alpha test was performed to evaluate the internal consistency of the scales. Additionally, to check if the reliability of the scale could be improved by excluding any items, Cronbach's alpha for the scale without this item was estimated. The factor analysis was used to make an initial decision about the number of underlying factors contributing to a set of responses. The varimax rotation was used to simplify the structure, with each item loading on as few dimensions as possible. The number of factors chosen was based on the inspection of the scree plot and the Kaiser criterion with an eigenvalue  $\leq 1$ .<sup>20</sup> Eigenvalues show the degree of variance of all factors, explained by the factor with greater eigenvalues, accounting for more of the variance. The level of significance was set at  $p < 0.05$  for all analyses.

**Table 1.** Authors' modified, Polish version of Oral Health Impact Profile (mOHIP-14-pl)

Original dimension	Question No.	Item	Subscale
Functional limitation	1.	Have you had trouble pronouncing any words because of problems with your:	A. teeth? B. oral mucosa? C. denture?
	2.	Have you felt that your sense of taste has worsened because of problems with your:	A. teeth? B. oral mucosa? C. denture?
Physical pain	3.	Have you had painful aching in your mouth because of problems with your:	A. teeth? B. oral mucosa? C. denture?
	4.	Have you found it uncomfortable to eat any foods because of problems with your:	A. teeth? B. oral mucosa? C. denture?
Psychological discomfort	5.	Have you been self-conscious because of your:	A. teeth? B. oral mucosa? C. denture?
	6.	Have you felt tense because of problems with your:	A. teeth? B. oral mucosa? C. denture?
Physical disability	7.	Has your diet been unsatisfactory because of problems with your:	A. teeth? B. oral mucosa? C. denture?
	8.	Have you had to interrupt meals because of problems with your:	A. teeth? B. oral mucosa? C. denture?
Psychological disability	9.	Have you found it difficult to relax because of problems with your:	A. teeth? B. oral mucosa? C. denture?
	10.	Have you been a bit embarrassed because of problems with your:	A. teeth? B. oral mucosa? C. denture?
Social disability	11.	Have you been a bit irritable with other people because of problems with your:	A. teeth? B. oral mucosa? C. denture?
	12.	Have you had difficulty doing your usual jobs because of problems with your:	A. teeth? B. oral mucosa? C. denture?
Handicap	13.	Have you felt that life in general is less satisfying because of problems with your:	A. teeth? B. oral mucosa? C. denture?
	14.	Have you been totally unable to function because of problems with your:	A. teeth? B. oral mucosa? C. denture?

## Results

A group of 180 subjects (age: 24–82 years; mean age: 55 years; 40.6% men; details in Fig. 1 and Table 2) self-completed the modified Polish language version of the OHIP-14 questionnaire for all 3 subscales. The main disorders diagnosed in patients are presented in Table 3.

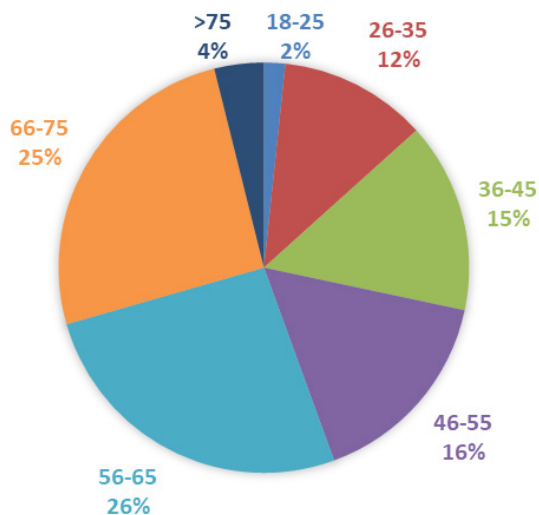


Fig. 1. Age structure of the respondents

Table 2. General diseases of the patients

General disease	n (%)
No general diseases	66 (36.7)
Any cardiovascular disease (including hypertension)	73 (40.6)
Hypertension	54 (30.0)
Diabetes mellitus	7 (3.9)
Osteoarticular diseases	32 (17.8)
Nervous system diseases (e.g., depression)	5 (2.8)
Any gastrointestinal diseases (including gastroesophageal reflux)	20 (11.1)
Gastroesophageal reflux	6 (3.3)
Respiratory diseases (asthma, chronic obstructive pulmonary disease)	6 (3.3)
Obesity	1 (0.6)
Lichen planus cutis	1 (0.6)
Other	52 (28.9)

The questionnaires with 1 and more “I don’t know”, “not applicable” and missing answers were excluded from the statistical analysis. One hundred and twenty-eight patients (71.1%) gave detailed answers to the questions regarding the teeth (subscale 1). In subscale 2, 134 respondents (74.4%) and in subscale 3, 82 patients (45.6%) were considered in the analysis. Ninety-three patients (51.7%) were fixed or removable prosthesis users.

Table 3. Disorders diagnosed in the patients

Disorders	n (%)
Gingivitis: dental biofilm-induced	56 (31.1)
Periodontitis	79 (43.9)
Periodontal abscesses and endodontic-periodontal lesions	1 (0.6)
Gingival recession	8 (4.4)
Oral mucosa diseases (oral lichen planus, leukoplakia, burning mouth syndrome, candidosis, xerostomia, geographic tongue, aphthous stomatitis, Sjögren’s syndrome)	74 (41.1)
Neuralgia	1 (0.6)
Caries	7 (3.9)
Teeth to extraction	9 (5.0)
Temporomandibular joint disorders	4 (2.2)
Fetor ex ore	4 (2.2)
Prosthesis-related oral mucosa injuries	5 (2.8)
Defect after maxillectomy or mandibulectomy	4 (2.2)

The internal consistency assessed on the basis of Cronbach’s alpha test was excellent for all 3 subscales (subscale 1:  $\alpha = 0.924$ ; subscale 2:  $\alpha = 0.937$ ; subscale 3:  $\alpha = 0.936$ ). Excluding items in each subscale did not significantly improve the Cronbach’s alpha value, so the authors decided that all items were necessary in the scale.

The factor structure of the examined scales was explored using the factor analysis. Bartlett’s test of sphericity (subscale 1:  $\chi = 1102.7$ ,  $df = 91$ ,  $p < 0.001$ ; subscale 2:  $\chi = 1303.8$ ,  $df = 91$ ,  $p < 0.001$ ; subscale 3:  $\chi = 888.2$ ,  $df = 91$ ;  $p < 0.001$ ) revealed significant correlations between the studied items, thereby enabling further analysis. The Kaiser–Meyer–Olkin (KMO) test for sampling adequacy (subscale 1: 0.907,  $p < 0.001$ ; subscale 2: 0.897,  $p < 0.001$ ; subscale 3: 0.882,  $p < 0.001$ ) indicated that the items could be implemented as a scale and the factor analysis could be applied.

In the case of subscale 1, the Kaiser criterion showed a model with 3 factors, which together explained 67.1% of the variance (Table 4). The 1<sup>st</sup> factor, accounting for 32.9% of the variance, represented psychological and social limitations. The highest factorial load was observed for the following items: 6, 10, 5, 11, 13, 14, and 12. The 2<sup>nd</sup> factor, constituting 22.0% of the variance, represented physical limitations. The items with a high factorial load were as follows: 3, 8, 9, 4, and 7. The 3<sup>rd</sup> factor, making up 12.2% of the variance, determined functional limitations. A high factorial load was observed for items 1 and 2.

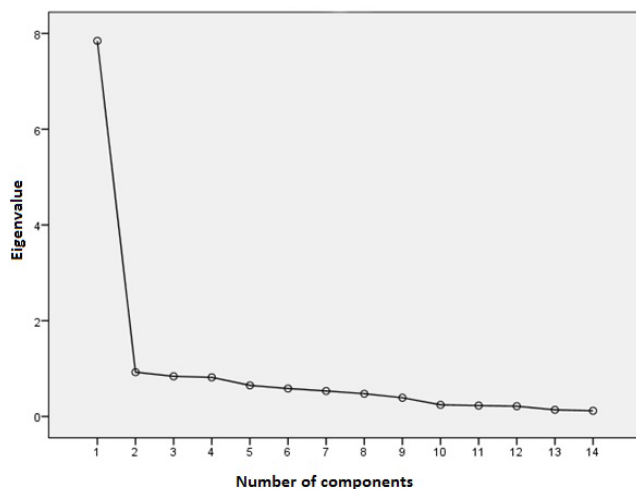
The Kaiser criterion for subscale 2 as well as the inspection of the scree plot produced a single-factor model (Fig. 2). This means that there are no other subscales for this scale.

In the case of subscale 3, the Kaiser criterion produced a model with 2 factors, which together explained 65.2% of the variance (Table 5). The 1<sup>st</sup> factor, accounting for 38.9% of the variance, referred to physical and psychological limitations that were particularly disruptive during social interactions. The highest factorial load was observed for the following

**Table 4.** Factor loadings in the rotated factor solution for subscale 1 (loadings below 0.3 are not displayed)

OHIP-14 item	Factor		
	psychological and social limitations	physical limitations	functional limitations
Item 6	0.893	–	–
Item 10	0.846	–	–
Item 5	0.825	–	–
Item 11	0.789	0.304	–
Item 13	0.615	0.389	–
Item 14	0.552	0.367	–
Item 12	0.519	0.431	–
Item 3	–	0.808	–
Item 8	0.316	0.803	–
Item 9	0.517	0.598	–
Item 4	0.366	0.540	0.368
Item 7	0.476	0.484	0.305
Item 1	–	–	0.919
Item 2	–	0.448	0.596
Variance explained	32.9%	22.0%	12.2%

OHIP – Oral Health Impact Profile.

**Fig. 2.** Scree plot for subscale 2

items: 5, 4, 10, 6, 3, 8, 7, and 9. The 2<sup>nd</sup> factor, accounting for 26.3% of the variance, comprised basic activities and personal comfort limitations. A high factorial load was observed for the following items: 14, 12, 13, 11, 1, and 2.

## Discussion

An objective assessment of QOL requires the use of reliable tools. Reliability is tested using a standardized statistical process called validation. Its purpose

**Table 5.** Factor loadings in the rotated factor solution for subscale 3 (loadings below 0.3 are not displayed)

OHIP-14 item	Factor	
	social interactions limitations	basic activities disorder and personal discomfort
Item 5	0.842	–
Item 4	0.842	–
Item 10	0.828	0.371
Item 6	0.813	0.372
Item 3	0.731	–
Item 8	0.684	0.394
Item 7	0.663	0.418
Item 9	0.510	0.465
Item 14	–	0.884
Item 12	–	0.826
Item 13	0.442	0.648
Item 11	0.616	0.621
Item 1	0.490	0.516
Item 2	0.326	0.442
Variance explained	38.9%	26.3%

is not only to create new reliable scales and questionnaires, but also to improve the already constructed ones. Validation should be conducted carefully and precisely for every surveyed population in view of linguistic differences and other factors related to age, disease, environment, etc.

To the authors' knowledge, this is the first study confirming the hypothetical factorial model of the OHIP-14 questionnaire in patients with periodontal disease and oral mucosa diseases. The assessment of QOL among such patients performed separately in relation to the teeth, oral mucosa and dentures showed a different structure of these scales. The factor analysis showed that using the same set of questions but in relation to distinct parts of the oral cavity raises the importance of different aspects of QOL. The factor structure of subscale 1 related to the teeth shows that the psychological and social, physical, and functional aspects of QOL should be treated separately. On the contrary, QOL for the oral mucosa subscale was shown to have only a 1-dimensional structure, suggesting that all aspects of QOL are mixed and strongly correlated. Subscale 3 is related to the denture usage and for this subscale, a 2-factor structure was found. In addition, those factors were different from the factors for subscale 1 – social relations were found to be most pronounced and other problems/aspects constituted the 2<sup>nd</sup> factor. These results suggest that oral health related to QOL, especially from the point of view of the periodontal patient, should be analyzed carefully, not only as a general oral health measure, but also in relation to the specific problems.

The statistical test used most frequently to assess the internal consistency of an instrument is Cronbach's alpha. In the present study, conducted among Polish adults suffering from periodontal or oral mucosa diseases, the Cronbach's alpha value was high for each subscale (subscale 1:  $\alpha = 0.924$ ; subscale 2:  $\alpha = 0.937$ ; subscale 3:  $\alpha = 0.936$ ). Similar results were found for the validation of the Polish ( $\alpha > 0.9$ ),<sup>18</sup> Turkish ( $\alpha = 0.91$ ),<sup>15</sup> and Greek and Spanish ( $\alpha = 0.90$ )<sup>14,21</sup> version of the OHIP questionnaire. Excellent internal consistency was found in the German version of OHIP-49 ( $\alpha = 0.96$ ).<sup>12</sup> Values above 0.7 show a factorial structure with good internal consistency, but according to Bland and Altman, for the clinical application, very high values of Cronbach's alpha are needed.<sup>22</sup> The desirable value is 0.95 and the minimum – 0.90.

The internal reliability of the original English version of the scale obtained by Slade, who recalibrated the original English version of OHIP-14 for a group of 1217 Australians,<sup>7</sup> was worse than in this study ( $\alpha = 0.88$ ).

Periodontal patients often suffer from tooth mobility, displacement and loss. These problems may cause limitations in social interactions (fear of smiling and laughing, problems during eating related to mobile teeth and/or dentures, etc.), but also influence private life (fear of sudden tooth loss, tension, etc.). In periodontal patients, OHRQOL decreases<sup>23–27</sup> and is multidimensional. Oral rehabilitation as well as many factors related to treatment (e.g., the sort of denture, the frequency and regularity of follow-up appointments) can influence OHRQOL. McKenna et al. investigated the influence of prosthetic rehabilitation on OHRQOL in 2 groups of partially dentulous older people: group 1 was treated with removable partial dentures and group 2 – with fixed adhesive bridges.<sup>28</sup> The OHRQOL of the patients improved after oral rehabilitation in both groups. The improvement was greater in group 2 and was maintained at the same level for 24 months following the treatment. In group 1, the initial pace of improvement started to diminish after 6 months.

This study has some limitations. Firstly, it was conducted in a highly specialized university clinic, where many patients are referred because of the severity of their diseases, which may adversely influence the patients' HRQOL. Secondly, the majority of the respondents were elderly and their life experience, general diseases and social expectations may have affected the results. On this account, it is possible that the patients modified the answers to seem healthier or to emphasize their complaints and the severity of the disease. There is no doubt that the general health condition (such as insomnia or depression) can also influence the patient's responses.<sup>29,30</sup> It may be related to lowering the individual's acceptance level, some sacrifices or new habits in the case of chronic diseases, or with cognitive functions disorders in the case of mental diseases. Thirdly, the study population consisted not only of first-time patients, but also of regular patients. This means that some of the patients had undergone at least

the initial treatment (in some cases, also the long-term treatment), and that their awareness of their disease had changed and acute symptoms had been eliminated, which could influence subjective HRQOL.<sup>23</sup>


On the other hand, this study is innovative in the way HRQOL is assessed using a modified OHIP-14 questionnaire, in which this aspect is separately analyzed in relation to the teeth, oral mucosa and dentures. This may point out the dimensions that are especially affected in periodontal patients; in their case, the problem relates not only to the teeth and the surrounding tissues, but also to tooth loss and the necessity of prosthetic treatment. In the future, this innovative view of assessing the patient's HRQOL could be applied in clinical settings and influence the individual patient's treatment plan, compliance and satisfaction.


## Conclusions


Statistical testing showed the mOHIP-14-pl questionnaire to be a reliable tool for evaluating OHRQOL in patients with periodontal or oral mucosa diseases. The factor analysis confirmed 3 dimensions which should be considered regarding the teeth ("physical and social limitations", "physical limitations" and "functional limitations") and 2 dimensions regarding dentures ("social interactions limitations" and "basic activities disorder and personal discomfort"). Regarding oral mucosa, all standard dimensions should be taken into account. Very high values of Cronbach's alpha indicate that the questionnaire can be used in clinical settings.

## ORCID iDs

Katarzyna Wąsacz  <https://orcid.org/0000-0001-8599-7927>

Agnieszka Pac  <https://orcid.org/0000-0002-6057-479X>

Dagmara Darczuk  <https://orcid.org/0000-0003-1843-4707>

Maria Chomyszyn-Gajewska  <https://orcid.org/0000-0002-0122-3463>

## References

- Callahan D. The WHO definition of 'health'. *Stud Hastings Cent.* 1973;1(3):77–87.
- Turska W, Skowron A. Methodics of quality of life assessment [in Polish]. *Farm Pol.* 2009;65(8):572–580.
- Sixou JL. How to make a link between Oral Health-Related Quality of Life and dentin hypersensitivity in the dental office? *Clin Oral Investig.* 2013;17(Suppl 1):41–44.
- Petersen PE, Yamamoto T. Improving the oral health of older people: The approach of the WHO Global Oral Health Programme. *Community Dent Oral Epidemiol.* 2005;33(2):81–92.
- Kłak A, Mińsko M, Siwczyńska D. Questionnaire methods of studies on quality of life [in Polish]. *Probl Hig Epidemiol.* 2012;93(4):632–638.
- Slade GD, Spencer AJ. Development and evaluation of the Oral Health Impact Profile. *Community Dent Health.* 1994;11(1):3–11.
- Slade GD. Derivation and validation of a short-form oral health impact profile. *Community Dent Oral Epidemiol.* 1997;25(4):284–290.
- Atchison KA, Dolan TA. Development of the Geriatric Oral Health Assessment Index. *J Dent Educ.* 1990;54(11):680–687.
- Pace-Balzan A, Cawood JI, Howell R, Lowe D, Rogers SN. The Liverpool Oral Rehabilitation Questionnaire: A pilot study. *J Oral Rehabil.* 2004;31(6):609–617.

10. Pace-Balzan A, Cawood JI, Howell R, Butterworth CJ, Lowe D, Rogers SN. The further development and validation of the Liverpool Oral Rehabilitation Questionnaire: A cross-sectional survey of patients attending for oral rehabilitation and general dental practice. *Int J Oral Maxillofac Surg.* 2006;35(1):72–78.
11. Rajan B, Ahmed J, Shenoy N, Denny C, Ongole R, Binnal A. Assessment of quality of life in patients with chronic oral mucosal diseases: A questionnaire-based study. *Perm J.* 2014;18(1):e123–e127.
12. John MT, Patrick DL, Slade GD. The German version of the Oral Health Impact Profile – translation and psychometric properties. *Eur J Oral Sci.* 2002;110(6):425–433.
13. Corridore D, Campus G, Guerra F, Ripari F, Sale S, Ottolenghi L. Validation of the Italian version of the Oral Health Impact Profile-14 (IOHIP-14). *Ann Stomatol (Roma).* 2014;4(3–4):239–243.
14. Papagiannopoulou V, Oulis CJ, Papaioannou W, Antonogeorgos G, Yfantopoulos J. Validation of a Greek version of the oral health impact profile (OHIP-14) for use among adults. *Health Qual Life Outcomes.* 2012;10:7.
15. Balci N, Alkan N, Gurgan C. Psychometric properties of a Turkish version of the oral health impact profile-14. *Niger J Clin Pract.* 2017;20(1):19–24.
16. Ide R, Yamamoto R, Mizoue T. The Japanese version of the Oral Health Impact Profile (OHIP) – validation among young and middle-aged adults. *Community Dent Health.* 2006;23(3):158–163.
17. Gerritsen AE, Nguyen TC, Witter DJ, Bronkhorst EM, Creugers NHJ. A Vietnamese version of the 14-item oral health impact profile (OHIP-14VN). *Open J Epidemiol.* 2012;2(1):28–35.
18. Skośkiewicz-Malinowska K, Kaczmarek U, Ziętek M, Malicka B. Validation of the Polish version of the oral health impact profile-14. *Adv Clin Exp Med.* 2015;24(1):129–137.
19. Guillemin F, Bombardier C, Beaton D. Cross-cultural adaptation of health-related quality of life measures: Literature review and proposed guidelines. *J Clin Epidemiol.* 1993;46(12):1417–1432.
20. Kaiser HF. The varimax criterion for analytic rotation in factor analysis. *Psychometrika.* 1958;23(3):187–200.
21. Lopez R, Baelum V. Spanish version of the Oral Health Impact Profile (OHIP-Sp). *BMC Oral Health.* 2006;6:11.
22. Bland J, Altman D. Cronbach's alpha. *BMJ.* 1997;314(7080):572.
23. Needleman I, McGrath C, Floyd P, Biddle A. Impact of oral health on the life quality of periodontal patients. *J Clin Periodontol.* 2004;31(6):454–457.
24. Ng SK, Leung WK. Oral health-related quality of life and periodontal status. *Community Dent Oral Epidemiol.* 2006;34(2):114–122.
25. Meusel DR, Ramacciato JC, Motta RH, Brito Júnior RB, Flório FM. Impact of the severity of chronic periodontal disease on quality of life. *J Oral Sci.* 2015;57(2):87–94.
26. Nagarajan S, Chandra RV. Perception of oral health related quality of life (OHQoL-UK) among periodontal risk patients before and after periodontal therapy. *Community Dent Health.* 2012;29(1):90–94.
27. Jowett AK, Orr MT, Rawlinson A, Robinson PG. Psychosocial impact of periodontal disease and its treatment with 24-h root surface debridement. *J Clin Periodontol.* 2009;36(5):413–418.
28. McKenna G, Allen PF, Hayes M, DaMata C, Moore C, Cronin M. Impact of oral rehabilitation on the quality of life of partially dentate elders in a randomised controlled clinical trial: 2 year follow-up. *PLoS One.* 2018;13(10):e0203349.
29. Noguchi S, Makino M, Haresaku S, Shimada K, Naito T. Insomnia and depression impair oral health-related quality of life in the old-old. *Geriatr Gerontol Int.* 2017;17(6):893–897.
30. Ostberg AL, Andersson P, Hakeberg M. Oral impacts on daily performances: Associations with self-reported general health and medication. *Acta Odontol Scand.* 2009;67(6):370–376.



# In vitro comparison of shear bond strength of a flowable composite resin and a single-component glass-ionomer to three different pulp-capping agents

## Porównanie in vitro wytrzymałości na ścinanie wiązania płynnej żywicy kompozytowej i jednoskładnikowego szkło-jonomeru z trzema materiałami do pokrycia miazgi

Paridokht Zarean<sup>1,D–F</sup>, Reza Roozbeh<sup>2,B–D</sup>, Parichehr Zarean<sup>3,D–F</sup>, Maryam Zare Jahromi<sup>4,A,B,D</sup>, Parvin Mirzakoochaki Broujeni<sup>5,A</sup>

<sup>1</sup> Dental Implant Research Center, Dental Research Institute, Isfahan University of Medical Sciences, Iran

<sup>2</sup> Private dental office, Yazd, Iran

<sup>3</sup> Dental Research Center, Dental Research Institute, Isfahan University of Medical Sciences, Iran

<sup>4</sup> Department of Endodontics, Dental School, Islamic Azad University, Isfahan (Khorasgan) Branch, Iran

<sup>5</sup> Department of Esthetic Dentistry, Dental School, Islamic Azad University, Isfahan (Khorasgan) Branch, Iran

A – research concept and design; B – collection and/or assembly of data; C – data analysis and interpretation; D – writing the article; E – critical revision of the article; F – final approval of the article

Dental and Medical Problems, ISSN 1644-387X (print), ISSN 2300-9020 (online)

*Dent Med Probl.* 2019;56(3):239–244

### Address for correspondence

Maryam Zare Jahromi  
E-mail: m.zare@khuif.ac.ir

### Funding sources

None declared

### Conflict of interest

None declared

Received on January 22, 2019

Reviewed on April 3, 2019

Accepted on May 8, 2019

Published online on September 30, 2019

### Cite as

Zarean P, Roozbeh R, Zarean P, Zare Jahromi M, Mirzakoochaki Broujeni P. In vitro comparison of shear bond strength of a flowable composite resin and a single-component glass-ionomer to three different pulp-capping agents. *Dent Med Probl.* 2019;56(3):239–244. doi:10.17219/dmp/109233

### DOI

10.17219/dmp/109233

### Copyright

© 2019 by Wrocław Medical University

This is an article distributed under the terms of the Creative Commons Attribution 3.0 Unported License (CC BY 3.0) (<https://creativecommons.org/licenses/by/3.0/>)

## Abstract

**Background.** Various materials are used for vital pulp capping and the bond strength of restorative materials to these pulp-capping agents significantly affects the success rate of vital pulp therapy.

**Objectives.** The aim of this study was to determine the shear bond strength of a flowable composite resin and a single-component glass-ionomer to mineral trioxide aggregate (MTA), calcium-enriched mixture (CEM) cement and Biodentine™ as pulp-capping agents.

**Material and methods.** Seventy-two cylindrical acrylic resin blocks, with a central hole 4 mm × 2 mm, were prepared. Mineral trioxide aggregate, CEM cement and Biodentine were placed in the cavities (n = 24 in each group) and incubated for 24 h. The blocks were subdivided into the composite resin and glass-ionomer subgroups. Cylindrical plastic molds, measuring 3 mm in height and diameter, were used to place the restorative materials on the samples. The shear bond strength test was performed at a strain rate of 1 mm/min in a universal testing machine. The samples were evaluated under a stereomicroscope at ×25 magnification for fracture modes. The data was analyzed with the one-way analysis of variance (ANOVA) and Tukey tests.

**Results.** The maximum and minimum mean shear bond strength values were recorded in the Biodentine–composite resin (4.77 MPa) and MTA–glass-ionomer (2.20 MPa) groups, respectively. There were significant differences in the mean shear bond strength values of MTA, CEM cement and Biodentine to the composite resin and glass-ionomer ( $p < 0.001$ ).

**Conclusions.** A composite material may be preferable for definitive filling after pulp capping with Biodentine.

**Key words:** shear bond strength, mineral trioxide aggregate, composite resin, glass-ionomer cement, Biodentine

**Słowa kluczowe:** wytrzymałość wiązania na ścinanie, agregat trójtlenków mineralnych, żywica kompozytowa, cement szkło-jonomerowy, Biodentyne



## Introduction

Vital pulp therapy consists in placing a biocompatible material on the exposed pulp of the teeth with an open apex.<sup>1</sup> Various materials are used for pulp capping, including calcium hydroxide, mineral trioxide aggregate (MTA) and newer silicate-based cements, such as BioAggregate®, EndoSequence®, Biodentine™, etc.<sup>2</sup>

Mineral trioxide aggregate is a hydrophilic cement composed of calcium oxide, silica and bismuth oxide. Several successful clinical applications have been reported for MTA.<sup>1</sup> Long-term studies (over 3 years) have reported that the success rate of vital pulp therapy with MTA is higher than in the case of calcium hydroxide (78% vs 60%).<sup>2</sup> These favorable outcomes for direct pulp therapy with MTA have been confirmed in recent systematic reviews.<sup>3</sup> Despite the various reported advantages, MTA has also some disadvantages, including potential for discoloration, difficult handling, long setting time, high cost, unavailability of a solvent, and difficulty with its removal after setting.<sup>4</sup>

Biodentine is a new calcium silicate-based cement with high purity, which has drawn attention as a substitute for dentin in composite resin restorations, direct pulp capping and endodontic treatment.<sup>5,6</sup> Biodentine consists of tricalcium silicate, calcium carbonate (as a filler), zirconium oxide (as an opacifier), and a water-based liquid containing calcium chloride. Calcium chloride serves as a water-reducing agent and decreases the initial and final setting times. The incorporation of calcium chloride into the liquid not only results in the acceleration of the setting time of Biodentine, but also improves the handling properties and strength of the cement.<sup>5</sup> In previous studies, Biodentine has exhibited better sealing ability, higher compressive strength, shorter setting time, lower microleakage, better antimicrobial properties, less toxic effects, and better biocompatibility, bioactivity and biomineralization compared to MTA.<sup>7</sup>

Calcium-enriched mixture (CEM) cement is a newly introduced material in endodontics. It is a water-based cement with clinical properties similar to those of MTA; however, its chemical properties are different.<sup>8</sup> This new material is recommended for direct pulp capping and pulpotomy in deciduous and permanent molars.<sup>9</sup>

One of the most important issues in vital pulp therapy is the ability to seal the pulp-capping agents, because keeping them intact affects the prognosis of the therapeutic procedure. Composite resins are common restorative materials, especially in the esthetic zones. A proper bond between the composite resin and the pulp-capping agent can distribute stresses beyond the bonded area on the tooth surface, decrease microleakage and increase the strength of the remaining tooth structure.<sup>10</sup>

In cases with an insufficient amount of enamel around the access cavity, resin-modified glass-ionomer (RMGI) is considered a suitable restorative material for the reconstruction of the crowns of the teeth that have undergone pulp therapy.<sup>11</sup> Glass-ionomers bond to the tooth structure

chemically, exhibit proper bio-compatibility, no polymerization shrinkage and no free monomers, and have dimensional stability in the presence of moisture, as their advantages.<sup>12</sup> At present, newer types of glass-ionomer cements have been introduced to overcome the disadvantages of old cements, including sensitivity to water and low translucency, and preserve their advantages, such as fluoride release and adhesion, at the same time.<sup>13</sup> A proper bond between the restorative material and the pulp-capping agent results in the distribution of stresses on all bonded surfaces, ensures the vitality of the pulp and its sealing, and improves the prognosis of vital pulp therapy.<sup>7,14</sup>

Cantekin and Avci evaluated the shear bond strength of a methacrylate-based and a silorane-based composite resin and a glass-ionomer to MTA and Biodentine.<sup>7</sup> They reported that the highest bond strength was related to the methacrylate-based composite resin bonded to Biodentine.<sup>7</sup> Later on, Doozaneh et al. reported that the bond strength of a self-adhering flowable composite resin to CEM cement and MTA was higher than in the case of improved RMGI with an additional application of an adhesive.<sup>15</sup> Also, in 2018, Elmi et al. concluded that irrespective of the type of adhesive system, the shear bond strength of a composite resin to CEM cement is higher than that of RMGI.<sup>16</sup>

The purpose of the present *in vitro* study was to determine the shear bond strength of a composite resin and a single-component glass-ionomer to MTA, CEM cement and Biodentine as pulp-capping agents.

## Material and methods

A total of 72 cylindrical acrylic resin blocks (Acropars®; Marlic Medical Ind. Co., Tehran, Iran) were prepared for the purpose of this *in vitro* study. A cavity, measuring 4 mm in diameter and 2 mm in depth, was prepared at the center of each cylinder. Mineral trioxide aggregate (ProRoot® MTA; Dentsply Sirona Inc., York, USA), CEM cement (Yektazist Dandan, Tehran, Iran) and Biodentine (Septodont, Saint-Maur-des-Fossés, France) were used according to the manufacturers' instructions. Mineral trioxide aggregate was mixed at a powder-to-liquid ratio of 3:1.<sup>4</sup> The liquid and powder of CEM cement were mixed according to the manufacturer's instructions to achieve a proper consistency. Biodentine was prepared in an amalgamator by adding 5 drops of Biodentine liquid to the capsule containing its powder in 30 s. Then, the prepared materials were placed in the cavities at the center of the acrylic blocks.

The blocks were divided into 3 groups according to the material used: MTA, CEM cement and Biodentine ( $n = 24$  in each group). The acrylic blocks were incubated at 37°C and 100% relative humidity for 24 h for the complete setting of the materials.<sup>7</sup> As the acid-etching procedure affected the compressive strength and surface microhardness, after 24 h, surface changes occurred, which enhanced bonding.<sup>17</sup> Then, each group was divided into 2 subgroups

– Grandio Flow® composite resin and Ionoseal® glass-ionomer (VOCO GmbH, Cuxhaven, Germany).

The blocks receiving the composite resin were acid-etched with 35% phosphoric acid for 15 s to avoid over-etching, which decreases the shear bond strength.<sup>18</sup> Afterward, they were rinsed with water for 30 s, followed by drying with an oil-free air stream for 5 s. At the next stage, the adhesive Solobond® M (VOCO GmbH) was applied on the specimen surfaces. It was applied twice and dried with an air flow for 5 s in order to evaporate its solvent. The next step was light-curing (LED D; Guilin Woodpecker Medical Instrument Co. Ltd., Guilin, China) for 15 s.

Cylindrical plastic molds, measuring 3 mm in diameter and height, were used to place the flowable composite resin.<sup>19</sup> The molds were filled with the Grandio Flow composite resin and placed on the prepared surfaces of the samples before setting, followed by light-curing for 20 s from the top, based on the manufacturer's instructions. Then, the plastic molds were gently detached from the composite resin molds, which was followed by light-curing for 20 s from the sides. Similar plastic molds were used for the Ionoseal glass-ionomer. The glass-ionomer was placed within the transparent molds put on the samples, followed by light-curing from the top for 20 s. Then, the plastic molds were gently separated from the glass-ionomer samples, which was followed by light curing from the sides for 20 s. Next, the samples were stored at 37°C and 100% relative humidity for 24 h.

Subsequently, the samples were transferred to a universal testing machine (Walter+Bai AG, Löhningen, Switzerland), equipped with a chisel-shaped head measuring 5 mm in width. A perpendicular force was applied at the restorative material–pulp-capping agent interface at a crosshead speed of 1 mm/min to detach the composite resin and glass-ionomer from the endodontic materials and to draw a graph. Before carrying out statistical analyses, the resultant data, recorded in N, was divided by the surface area of the samples (7.06 mm<sup>2</sup>) in order to determine the bond strength in MPa. Finally, all samples were evaluated under a stereomicroscope (trinocular zoom stereo microscope SMP-200; HP Inc., Palo Alto, USA) at ×25 magnification to evaluate the fracture modes (cohesive, adhesive or mixed).

The data was analyzed with the one-way analysis of variance (ANOVA), *t*-test and post hoc Tukey tests.

The significance level was assumed at  $p < 0.05$ . The tables were drawn using the software IBM SPSS Statistics for Windows, v. 20 (IBM Corp., Armonk, USA).

## Results

As shown in Table 1, the maximum and minimum mean shear bond strength values were recorded in the Biodentine–composite resin (4.77 MPa) and MTA–glass-ionomer (2.20 MPa) groups, respectively. There were significant differences in the mean shear bond strength values of MTA, CEM cement and Biodentine to the composite resin and glass-ionomer ( $p < 0.001$ ). Since the differences in the mean shear bond strength value of MTA, CEM cement and Biodentine to the composite resin and glass-ionomer were significant, the post hoc Tukey tests were used. The mean shear bond strength value of MTA to the composite resin was 3.19 MPa, which was significantly higher than those in the MTA–glass-ionomer and CEM cement–glass-ionomer groups ( $p < 0.001$ ). On the other hand, the mean shear bond strength value of the MTA–composite resin group was lower than those in the CEM cement–composite resin and Biodentine–composite resin groups, which was statistically significant ( $p < 0.001$ ). However, despite the lower mean shear bond strength value in the MTA–composite resin group compared to the Biodentine–glass-ionomer group, the difference was not statistically significant ( $p = 0.88$ ).

Based on the data in Table 2, the shear bond strength values for the CEM cement–composite resin group was

Table 1. Mean shear bond strength values of MTA, CEM and Biodentine to composite resin and glass-ionomer

Pulp-capping agent	Restorative material	Number	Mean bond strength [MPa]	SD
MTA	composite resin	12	3.19	0.23
	glass-ionomer	12	2.20	0.27
CEM cement	composite resin	12	4.00	0.47
	glass-ionomer	12	2.36	0.39
Biodentine	composite resin	12	4.77	0.30
	glass-ionomer	12	3.35	0.38

SD – standard deviation; MTA – mineral trioxide aggregate; CEM – calcium-enriched mixture.

Table 2. Two-by-two comparisons of the shear bond strength value between the study groups

Study groups	MTA –composite	CEM cement –composite	Biodentine –composite	MTA –glass-ionomer	CEM cement –glass-ionomer	Biodentine –glass-ionomer
	3.19	4.00	4.77	2.20	2.36	3.35
MTA–composite	–	$p < 0.001$	$p < 0.001$	$p < 0.001$	$p < 0.001$	$p = 0.88$
CEM cement–composite	$p < 0.001$	–	$p < 0.001$	$p < 0.001$	$p < 0.001$	$p < 0.001$
Biodentine–composite	$p < 0.001$	$p < 0.001$	–	$p < 0.001$	$p < 0.001$	$p < 0.001$
MTA–glass-ionomer	$p < 0.001$	$p < 0.001$	$p < 0.001$	–	$p = 0.87$	$p < 0.001$
CEM cement–glass-ionomer	$p < 0.001$	$p < 0.001$	$p < 0.001$	$p = 0.87$	–	$p < 0.001$
Biodentine–glass-ionomer	$p = 0.88$	$p < 0.001$	$p < 0.001$	$p < 0.001$	$p < 0.001$	–

higher compared to all other groups except for the Biodentine–composite resin group and the differences, whether higher or lower, were significant ( $p < 0.001$ ). The Biodentine–composite resin group had a higher shear bond strength value than all other 5 groups and the difference was statistically significant ( $p < 0.001$ ).

Also, the mean shear bond strength value in the MTA–glass-ionomer group was lower compared to other groups and this difference was not significant only with regard to the CEM cement–glass-ionomer group ( $p = 0.87$ ); however, the difference was significant in the case of the other groups ( $p < 0.001$ ).

The mean shear bond strength value in the CEM cement–glass-ionomer group was not significantly different only from that in the MTA–glass-ionomer group ( $p < 0.87$ ); however, the difference with regard to other groups was significant ( $p < 0.001$ ). The comparison of the mean shear bond strength values between the Biodentine–glass-ionomer and other groups showed no significant difference between this group and the MTA–composite resin group ( $p = 0.88$ ); however, the differences between this group and other groups were significant ( $p < 0.001$ ).

## Discussion

After vital pulp therapy, the treated tooth requires a suitable restoration. Recently, composite resins have been widely used for this purpose, but in some areas, where there is not enough enamel around the preparation site, RMGIs can be a good alternative.<sup>20</sup> The bond strength of restorative materials to pulp-capping agents plays a crucial role in the coronal sealing, and consequently the success of vital pulp therapy.<sup>7</sup> A proper bond between the restorative material and the pulp-capping agent also distributes stresses on the bonded surface area of dentin.<sup>14</sup>

Therefore, in the present study, the shear bond strength test was used to evaluate the adhesive properties of restorative materials (composite resin and glass-ionomer) to 3 pulp-capping agents (MTA, CEM cement and Biodentine). The shear bond strength of different restorative materials to MTA has been evaluated in previous studies.<sup>11,15</sup> However, only a few studies on the bond strength of different restorative materials to CEM cement and Biodentine are available.<sup>11,15,16,21</sup>

The results of the present study showed that the highest shear bond strength between the pulp-capping agent and the restorative material was in the Biodentine–composite resin group. Furthermore, Biodentine exhibited higher shear bond strength to the composite resin and glass-ionomer compared to that of MTA and CEM cement. This result is in agreement with Cengiz and Ulusoy's study.<sup>22</sup> Such a difference might be explained by the fact that, unlike MTA, in which only distilled water is used for setting, the liquid of Biodentine contains a mixture of distilled water, calcium chloride and a water-soluble monomer.<sup>23</sup>

Calcium chloride accelerates the setting reaction, and the water-soluble monomer serves as a water-reducing agent and decreases the amount of water in the material, increasing the strength of the material.<sup>23,24</sup>

In the present study, the surfaces of the pulp-capping agents were not polished; therefore, they had some indentations, resulting in the greater penetration of the composite resin and glass-ionomer. The use of a bonding agent in the composite resin groups could result in higher bond strength. Composite resin is a hydrophobic material and forms a better bond with surfaces that have low water content. The bonding agent used in the present study was of the total-etch type (Solobond<sup>®</sup> M; VOCO GmbH), which creates a better bond with drier surfaces. Considering the presence of a water-reducing agent in Biodentine, the water content of the material decreases, resulting in better conditions for bonding with composite resin.

The exact mechanism of bonding restorative materials to Biodentine has not been elucidated. Since Biodentine and MTA have a similar chemical structure, it is probable that their water absorption is also similar. Etchants, during shorter than usual times, might cause the selective elimination of the matrix around crystal structures, leading to successful bonding through micromechanical interlocking.<sup>17</sup>

The majority of studies on various adhesive systems applied on MTA have shown favorable shear bond strength obtained with the use of total-etch adhesive systems; it has been demonstrated that phosphoric acid creates deeper and more retentive microscopic pores compared to self-etch adhesive systems.<sup>17</sup> In the present study, the samples receiving composite resin were acid-etched with 35% phosphoric acid. Since no resin structure is present in MTA and CEM cement, it can be claimed that their bonding to restorative materials is completely mechanical.

Altunsoy et al. evaluated the shear bond strength of 2 different types of composite resin to MTA, CEM cement and Biodentine.<sup>25</sup> The results showed that the lowest bond strength was related to Biodentine–composite resin, contrary to the results of the present study. They used a self-adhesive flowable composite resin, without etching and dentin bonding. In addition, in their study, the specimen surfaces were polished with abrasive paper for 1 min, which resulted in a decrease in bond strength.<sup>25</sup>

Cantekin and Avci evaluated the shear bond strength of a methacrylate-based and a silorane-based composite resin as well as a glass-ionomer to MTA and Biodentine.<sup>7</sup> They reported that the highest bond strength was related to methacrylate-based composite resin bonded to Biodentine. The results of their study are consistent with those of the present study. It should be pointed out that in the study by Cantekin and Avci, contrary to the present study, the composite resins were packable; in the present study, a flowable composite resin was used. In addition, the glass-ionomer used in the study by Cantekin and Avci was a type of conventional self-cured glass-ionomer.<sup>7</sup>

Ajami et al. compared the shear bond strengths of composite resin and glass-ionomer to MTA, CEM cement and white MTA (WMTA) mixed with  $\text{Na}_2\text{HPO}_4$  (NAMTA) as pulp-capping agents.<sup>11</sup> The highest bond strength was recorded in the NAMTA–composite resin group. It should be pointed out that some properties of NAMTA are different from those of MTA. The study carried out by Ajami et al. was different from the present one with regard to the methods and the materials used. In their study, all samples were sandblasted and a packable composite resin was used in association with a one-step self-etch adhesive system.<sup>11</sup>

Based on the results of the present study, the minimum shear bond strength value between the pulp-capping agent and the restorative material was recorded in the MTA–glass-ionomer group. When a restorative glass-ionomer is placed on MTA, one of the following reactions might occur:

- the  $\text{COO}^-$  group in polyacrylic acid might react with calcium in MTA to produce calcium salts;
- the MTA hydrated silicate gel might be compressed by the glass-ionomer hydrated silicate gel to create byproducts.<sup>26</sup>

Given the high percentage of metallic oxides in MTA and the porous surface topography of MTA, it is expected that glass-ionomer will form a relatively strong bond with MTA.<sup>27</sup> The glass-ionomer used in the present study was Ionoseal, which is a single-component material. Since no etching or bonding were used in the glass-ionomer groups, possibly this material exhibited lower bond strength compared to the composite resin bonded to the pulp-capping agents. However, since in the present study, the surfaces of the pulp-capping agents were not polished and had some inherent porosity as well as considering the fact that the glass-ionomer used in the present study was flowable and exhibited proper adaptation to the surface, the restorative material formed a relatively strong bond to the pulp-capping agents.

In the study by Cantekin and Avci, in which the bond strength of Biodentine and MTA to a silorane-based composite resin, a methacrylate-based composite resin and a self-curing conventional glass-ionomer was evaluated, the lowest bond strength was recorded in the MTA–glass-ionomer group,<sup>7</sup> which is consistent with the results of the present study.

In the study by Ajami et al., in which the shear bond strength of composite resin and glass-ionomer to MTA, CEM cement and NAMTA was evaluated, the lowest bond strength values were recorded in the CEM cement–glass-ionomer group,<sup>11</sup> which does not agree with the results of the present study. It should be pointed out that such a discrepancy in the results might be attributed to the differences in the methodologies, including the use of sandblasting and the use of polyacrylic acid as a conditioner before the application of RMGI.

In the present study, the fracture mode in all samples was cohesive within the pulp-capping agents. Recent stu-

dies have demonstrated that the fracture mode between MTA and dentin was cohesive within MTA. However, the number of cohesive fractures decreased and the number of adhesive fractures increased over time.<sup>28</sup> In addition, the researchers pointed out that when CEM cement was used as a root-end filling material, the fracture mode was cohesive in the push-out test.<sup>29</sup> In order to carry out a successful restorative procedure with 2 different materials, there should be a proper bond between the 2 materials. Generally, a bond is favorable when the fracture occurs within the material rather than at the bonded interface (i.e., a cohesive fracture is better than adhesive failure).<sup>19</sup>


Since in the present study, the failure mode in all samples was cohesive within the pulp-capping agents, the results indicate a favorable bond between the restorative material and the pulp-capping agent. In the evaluation of failure modes, especially in the shear bond strength tests, one important issue should be taken into account. The tendency toward a cohesive fracture might be attributed to the uneven distribution of stresses within the bonded materials, resulting in early failure before the bonded surface is affected.<sup>30</sup> This is an inherent problem with the shear bond strength test, in which a lot of tensile force is applied to the area below the force application point, with simultaneous compressive stresses at the point opposite the force application point.<sup>31</sup>


## Conclusions


Within the limitations of an in vitro study, the composite resin exhibited stronger bonds to all the evaluated pulp-capping agents compared to the glass-ionomer. Among the pulp-capping materials, Biodentine exhibited a higher bond strength value to the flowable composite resin and the glass-ionomer. Therefore, to achieve a proper bond, the use of a composite resin on Biodentine is recommended.


### ORCID iDs

Paridokht Zarean  <https://orcid.org/0000-0002-9983-3066>

Reza Roozbeh  <https://orcid.org/0000-0003-1831-8028>

Parichehr Zarean  <https://orcid.org/0000-0002-6858-6146>

Maryam Zare Jahromi  <https://orcid.org/0000-0002-4642-2810>

Parvin Mirzakoochaki Broujeni  <https://orcid.org/0000-0001-9393-8222>

### References

1. Ford TR, Torabinejad M, Abedi HR, Bakland LK, Kariyawasam SP. Using mineral trioxide aggregate as a pulp-capping material. *J Am Dent Assoc.* 1996;127(10):1491–1494.
2. Mente J, Geletneky B, Ohle M, et al. Mineral trioxide aggregate or calcium hydroxide direct pulp capping: An analysis of the clinical treatment outcome. *J Endod.* 2010;36(5):806–813.
3. Didilescu AC, Cristache CM, Andrei M, Voicu G, Perlea P. The effect of dental pulp-capping materials on hard-tissue barrier formation: A systematic review and meta-analysis. *J Am Dent Assoc.* 2018;149(10):903–917.e4.
4. Parirokh M, Torabinejad M. Mineral trioxide aggregate: A comprehensive literature review. Part I: Chemical, physical, and antibacterial properties. *J Endod.* 2010;36(1):16–27.

5. Koubi G, Colon P, Franquin JC, et al. Clinical evaluation of the performance and safety of a new dentine substitute, Biodentine, in the restoration of posterior teeth – a prospective study. *Clin Oral Investig*. 2013;17(1):243–249.
6. Schmidt A, Schäfer E, Dammaschke T. Shear bond strength of lining materials to calcium-silicate cements at different time intervals. *J Adhes Dent*. 2017;19(2):129–135.
7. Cantekin K, Avci S. Evaluation of shear bond strength of two resin-based composites and glass ionomer cement to pure tricalcium silicate-based cement (Biodentine®). *J Appl Oral Sci*. 2014;22(4):302–306.
8. Asgary S, Shahabi S, Jafarzadeh T, Amini S, Kheirieh S. The properties of a new endodontic material. *J Endod*. 2008;34(8):990–993.
9. Malekafzali B, Shekarchi F, Asgary S. Treatment outcomes of pulpotomy in primary molars using two endodontic biomaterials: A 2-year randomised clinical trial. *Eur J Paediatr Dent*. 2011;12(3):189–193.
10. Heymann HO, Swift EJ Jr., Ritter AV, Sturdevant CM. *Sturdevant's Art and Science of Operative Dentistry*. 6<sup>th</sup> ed. St. Louis, MO: Elsevier/Mosby; 2013:245.
11. Ajami AA, Jafari Navimipour E, Savadi Oskoe S, Abed Kahnamoui M, Lotfi M, Daneshpoo M. Comparison of shear bond strength of resin-modified glass ionomer and composite resin to three pulp capping agents. *J Dent Res Dent Clin Dent Prospects*. 2013;7(3):164–168.
12. Hilton TJ, Ferracane JL, Broome JC, eds. *Summitt's Fundamentals of Operative Dentistry: A Contemporary Approach*. 4<sup>th</sup> ed. Hanover Park, IL: Quintessence Publishing Co. Inc.; 2013:516.
13. Sakaguchi RL, Powers JM, eds. *Craig's Restorative Dental Materials*. 13<sup>th</sup> ed. Philadelphia, PA: Elsevier/Mosby; 2012:156–159.
14. Oskoe SS, Kimyai S, Bahari M, Motahari P, Eghbal MJ, Asgary S. Comparison of shear bond strength of calcium-enriched mixture cement and mineral trioxide aggregate to composite resin. *J Contemp Dent Pract*. 2011;12(6):457–462.
15. Doozaneh M, Koohpeima F, Firouzmandi M, Abbassiyan F. Shear bond strength of self-adhering flowable composite and resin-modified glass ionomer to two pulp capping materials. *Iran Endod J*. 2017;12(1):103–107.
16. Elmi M, Ehsani M, Esmaeili B, Khafri S. Comparison of bond strength of a composite resin with two different adhesive systems and a resin modified glass ionomer to calcium enriched mixture. *J Conserv Dent*. 2018;21(4):369–372.
17. Kayahan MB, Nekoofar MH, Kazandağ M, et al. Effect of acid-etching procedure on selected physical properties of mineral trioxide aggregate. *Int Endod J*. 2009;42(11):1004–1014.
18. Al-Suleiman M, Baba F, Sawan MN, Suliman A. Mechanical evaluation of the effect of reducing phosphoric acid concentrations and etching duration on the bond strength of orthodontic brackets. *J Dent Oral Disord Ther*. 2014;2(2):1–5.
19. Tate WH, Friedl KH, Powers JM. Bond strength of composites to hybrid ionomers. *Oper Dent*. 1996;21(4):147–152.
20. Paterson RC. Bacterial contamination and the exposed pulp. *Br Dent J*. 1976; 140(7):231–236.
21. Odabaş ME, Bani M, Tirali RE. Shear bond strengths of different adhesive systems to biodentine. *ScientificWorldJournal*. 2013;2013:626103.
22. Cengiz E, Ulusoy N. Microshear bond strength of tri-calcium silicate-based cements to different restorative materials. *J Adhes Dent*. 2016;18(3):231–237.
23. Bortoluzzi EA, Broon NJ, Bramante CM, Felipe WT, Tanomaru Filho M, Esberard RM. The influence of calcium chloride on the setting time, solubility, disintegration, and pH of mineral trioxide aggregate and white Portland cement with a radiopacifier. *J Endod*. 2009;35(4):550–554.
24. Pradelle-Plasse N, Tran XV, Colon P. Physico-chemical properties. In: ORE-FDI working group; Goldberg M, ed. *Biocompatibility or Cytotoxic Effects of Dental Composites*. Oxford, UK: Coxmoor Publishing Company; 2009:184–194.
25. Altunsoy M, Tanriver M, Ok E, Kucukyilmaz E. Shear bond strength of a self-adhering flowable composite and a flowable base composite to mineral trioxide aggregate, calcium-enriched mixture cement, and Biodentine. *J Endod*. 2015;41(10):1691–1695.
26. Nandini S, Ballal S, Kandaswamy D. Influence of glass-ionomer cement on the interface and setting reaction of mineral trioxide aggregate when used as a furcal repair material using laser Raman spectroscopic analysis. *J Endod*. 2007;33(2):167–172.
27. Yesilyurt C, Yildirim T, Taşdemir T, Kusgoz A. Shear bond strength of conventional glass ionomer cements bound to mineral trioxide aggregate. *J Endod*. 2009;35(10):1381–1383.
28. Mozayeni MA, Milani AS, Marvasti LA, Asgary S. Cytotoxicity of calcium enriched mixture cement compared with mineral trioxide aggregate and intermediate restorative material. *Aust Endod J*. 2012;38(2):70–75.
29. Shokouhinejad N, Razmi H, Fekrazad R, et al. Push-out bond strength of two root-end filling materials in root-end cavities prepared by Er,Cr:YSGG laser or ultrasonic technique. *Aust Endod J*. 2012;38(3):113–117.
30. Asgary S, Eghbal MJ, Parirokh M, Ghodduji J, Kheirieh S, Brink F. Comparison of mineral trioxide aggregate's composition with Portland cements and a new endodontic cement. *J Endod*. 2009;35(2):243–250.
31. Armstrong S, Geraldeli S, Maia R, Raposo LH, Soares CJ, Yamagawa J. Adhesion to tooth structure: A critical review of "micro" bond strength test methods. *Dent Mater*. 2010;26(2):e50–e62.

## Effect of two universal adhesives on microshear bond strength of resin cement to zirconia

## Wpływ dwóch uniwersalnych systemów łączących na wytrzymałość na mikrościananie wiązania cementu kompozytowego do cyrkonu

Shila Emamieh<sup>A,D,F</sup>, Mahya Elahi<sup>A,B</sup>, Amir Ghasemi<sup>E,F</sup>

Shahid Beheshti University of Medical Sciences, Tehran, Iran

A – research concept and design; B – collection and/or assembly of data; C – data analysis and interpretation; D – writing the article; E – critical revision of the article; F – final approval of the article

Dental and Medical Problems, ISSN 1644-387X (print), ISSN 2300-9020 (online)

*Dent Med Probl.* 2019;56(3):245–249

### Address for correspondence

Shila Emamieh  
E-mail: shilaemamieh@gmail.com

### Funding sources

None declared

### Conflict of interest

None declared

Received on December 28, 2018

Reviewed on March 18, 2019

Accepted on May 14, 2019

Published online on July 23, 2019

### Cite as

Emamieh S, Elahi M, Ghasemi A. Effect of two universal adhesives on microshear bond strength of resin cement to zirconia. *Dent Med Probl.* 2019;56(3):245–249. doi:10.17219/dmp/109349

### DOI

10.17219/dmp/109349

### Copyright

© 2019 by Wrocław Medical University

This is an article distributed under the terms of the

Creative Commons Attribution 3.0 Unported License (CC BY 3.0)

(<https://creativecommons.org/licenses/by/3.0/>)

## Abstract

**Background.** Considering the increasing demand of patients for esthetic and durable restorations, zirconia, with its excellent mechanical properties, has overcome most of the limitations of all-ceramic restorations. However, bonding to zirconia is still challenging.

**Objectives.** This study compared the effect of 2 universal adhesives on the microshear bond strength of resin cement to zirconia after 24 h and 6 months of water storage.

**Material and methods.** This in vitro experimental study was performed on 56 zirconia (Prettau® Zirconia) blocks, which were randomly divided into 2 groups. The Scotchbond™ Universal single-component adhesive and the All-Bond Universal™ 2-component adhesive were used. The PANAVIA™ F 2.0 resin cement was bonded to all samples, and they were stored in distilled water for 24 h and 6 months. The microshear bond strength test was then performed, and the data was analyzed using the Kruskal–Wallis and Mann–Whitney tests.

**Results.** After 24 h of water storage, the All-Bond samples showed significantly higher microshear bond strength than the Scotchbond samples ( $p < 0.001$ ), but at 6 months, the microshear bond strength of Scotchbond was higher. The bond strength of All-Bond decreased after 6 months ( $p < 0.001$ ), but no significant change occurred in the bond strength of the Scotchbond samples over time.

**Conclusions.** The microshear bond strength of resin cement to zirconia depends on the type of adhesive and the duration of water storage. The Scotchbond Universal adhesive resulted in a stronger bond in the long term.

**Key words:** zirconium oxide, adhesives, resin cement, All-Bond system

**Słowa kluczowe:** tlenek cyrkonu, systemy łączące, cement kompozytowy, system All-Bond

## Introduction

From among different dental ceramics, zirconia has become highly popular among clinicians due to its biocompatibility, favorable mechanical properties, long-term durability, and optimal esthetics.<sup>1</sup> Zirconia can well mimic the natural appearance of the teeth. However, it is brittle, fragile and susceptible to fracture.<sup>2</sup> Saliva, thermal changes and the acidity of the oral environment after food consumption decrease the mechanical stability of zirconia.<sup>3</sup> Several methods have been suggested for the ceramic surface preparation, such as micromechanical retention, sandblasting with alumina particles, laser treatment, and chemical bonding. However, difficult handling of alumina particles is one limitation of this method. Thus, a strong bond is required to provide retention. For the cementation of zirconia restorations, the application of a bonding agent can significantly enhance the bond strength of resin cement to zirconia.<sup>4–6</sup> The manufacturers claim that the universal adhesives available on the market can be used for different substrates. Two-component universal adhesives are also available. These adhesives require fewer procedural steps, which consequently saves time and decreases the technical sensitivity of the procedure.<sup>7</sup> The new universal adhesives contain the 10-methacryloyloxydecyl dihydrogen phosphate (10-MDP) monomer and, therefore, can form a chemical bond to resin cement.<sup>8</sup>

Several studies have searched for a suitable bonding agent to be applied on zirconia, but no simple scientific method has been introduced for this purpose. This study aimed to compare the effect of 2 universal adhesives on the microshear bond strength of resin cement to zirconia after 24 h and 6 months of water storage.

## Material and methods

Fifty-six zirconia (Prettau® Zirconia; Zirkozahn GmbH, Gais, Italy) blocks measuring 8 mm × 15 mm × 2 mm were fabricated, sintered and polished. The surface of all samples was rinsed with alcohol and water to remove debris, and dried with air spray. The zirconia blocks were divided into 2 groups, for the Scotchbond™ Universal single-component adhesive (3M ESPE, St. Paul, USA) and the All-Bond Universal™ 2-component adhesive (Bisco Inc., Schaumburg, USA) to be used. Each group was divided into 2 subgroups for water storage for 24 h and 6 months.

In the Scotchbond groups, 1 layer of Scotchbond was applied on the clean surface of the samples using a microbrush and dried with air spray to obtain a uniform layer of the adhesive on the surface. Curing was performed for 10 s, according to the manufacturer's instructions. For the application of All-Bond, 1 drop from each bottle was poured into an amalgam mixing bowl and mixed for 10–15 s. The mixture was then applied on the surface of zirconia using a microbrush, dried with air spray

and cured for 10 s. To bond the resin cement to the zirconia blocks, the TYGON® tubes (Saint-Gobain Performance Plastics Corp., Akron, USA) with an internal diameter of 0.7 mm were used. They were cut to the height of 1 mm and fixed to glass slides using glue.

For the preparation of the PANAVIA™ F 2.0 resin cement (Kuraray Noritake Dental Inc., Kurashiki, Japan), pastes A and B were mixed according to the manufacturer's instructions, and applied to the TYGON microtubes using a fine plugger. The TYGON tubes filled with the resin cement were placed on the zirconia blocks coated with the adhesive and excess cement was removed using a dental explorer. Each cement tube was cured for 20 s using a light-emitting diode (LED) light-curing unit (Guilin Woodpecker Medical Instrument Co. Ltd., Guilin, China) with a light intensity of 1000 mW/cm<sup>2</sup>.

After 24 h of water storage, the TYGON tubes were separated from the PANAVIA F 2.0 resin cement using a scalpel, whereas the resin cylinders with a diameter of 0.7 mm and a height of 1 mm remained attached to the zirconia surface. Half of the samples were subjected to the microshear bond strength test after 24 h of immersion in distilled water and incubation at 37°C. The remaining half were immersed in distilled water and incubated at 37°C for 6 months.

The Microtensile Tester machine (Bisco Inc.) was used for the measurement of the microshear bond strength of the PANAVIA F 2.0 resin cement to the zirconia ceramic.

The zirconia blocks bonded to the resin cement were fixed to the testing machine using cyanoacrylate glue. An orthodontic wire in the form of a hook was used for the load application to the resin cylinders. These wires were fixed to the cylinders. The maximum load causing failure of the bond between the resin cylinders and zirconia was recorded for all samples.

After the measurement of microshear bond strength, the surface of all samples was inspected under a light microscope at ×25 magnification (Carl Zeiss, Oberkochen, Germany) to determine the mode of failure. The mode of failure was recorded for all samples and divided into 3 groups as follows:

- adhesive failure: fracture at the zirconia–resin cement interface;
- cohesive failure: fracture within the resin cement;
- mixed failure: a combination of adhesive and cohesive failures.

Table 1 shows the chemical composition of the materials used in this study.

The Shapiro–Wilk test was used to assess normal distribution of the data. Since the data was not normally distributed in 2 of the 4 subgroups ( $p < 0.05$ ), and the interaction effect of the type of adhesive and the storage time on bond strength was significant, the non-parametric Kruskal–Wallis test was used for comparing the bond strength of the 4 groups and the Mann–Whitney test was used for multiple comparisons (Fig. 1). Type I error was set at 0.05.

**Table 1.** Chemical composition of the materials used in the study

Material	Composition	Manufacturer
Prettau Zirconia	ZrO <sub>2</sub> (+HfO <sub>2</sub> ) 95%, Y <sub>2</sub> O <sub>3</sub> 4.95–5.26%, Al <sub>2</sub> O <sub>3</sub> 0.15–0.35%, SiO <sub>2</sub> max 0.02%, Na <sub>2</sub> O max 0.04%, Fe <sub>2</sub> O <sub>3</sub> max 0.01%	Zirkonzahn GmbH, Gais, Italy
Scotchbond Universal	10-MDP, dimethacrylate resin, HEMA, ethanol, water, poly(acrylic acid) copolymer, silane, fillers, initiators	3M ESPE, St. Paul, USA
All-Bond Universal	10-MDP, dimethacrylate resin, HEMA, ethanol, water, initiators	Bisco Inc., Schaumburg, USA
PANAVIA F 2.0	paste A: 10-MDP, BPEDEMA, aliphatic dimethacrylate; paste B: composite containing Al-Ba-B-Si glass/silica	Kuraray Noritake Dental Inc., Kurashiki, Japan

BPEDEMA – bisphenol-A polyethoxydimethacrylate; HEMA – hydroxyethylmethacrylate; 10-MDP – 10-methacryloyloxydecyl dihydrogen phosphate.

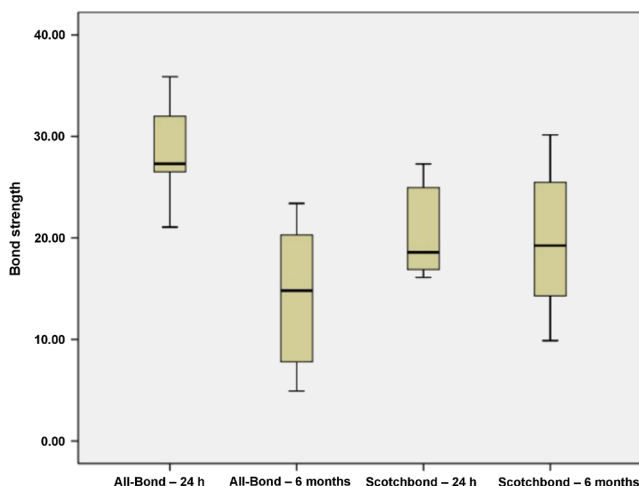


Fig. 1. Mean microshear bond strength according to the type of adhesive and the duration of storage

## Results

Table 2 shows the mean bond strength in the 4 subgroups. The results of the Kruskal–Wallis test showed that the 4 subgroups were significantly different in terms of bond strength ( $p < 0.001$ ). Pairwise comparisons using the Mann–Whitney test showed that the microshear bond strength of the All-Bond samples was significantly different after 24 h and 6 months of water storage, and it was significantly higher at 24 h ( $p < 0.001$ ). The bond strength of the Scotchbond samples was not significantly different at 24 h and 6 months ( $p = 0.603$ ). A significant difference was noted between the All-Bond and Scotchbond samples at 24 h – the microshear bond strength of All-Bond was higher than that of Scotchbond ( $p < 0.001$ ).

Table 2. Mean bond strength in the 4 subgroups (n = 14)

Groups	Mean [MPa]	SD	Minimum	Maximum
All-Bond – 24 h	28.52 <sup>a,d</sup>	4.40	21.06	35.88
All-Bond – 6 months	14.43 <sup>b,e</sup>	6.93	4.93	23.40
Scotchbond – 24 h	20.42 <sup>c,e</sup>	4.16	16.11	27.29
Scotchbond – 6 months	19.82 <sup>c,f</sup>	6.76	9.88	30.16

SD – standard deviation; values with a different superscript letter show statistical significance ( $p < 0.001$ ).

Figure 1 shows the comparison of All-Bond and Scotchbond. At 6 months, the Scotchbond samples proved to have higher microshear bond strength ( $p = 0.039$ ).

A significant difference was noted between the All-Bond samples stored for 24 h and the Scotchbond samples stored for 6 months, with the former having higher bond strength ( $p = 0.001$ ). No significant difference was noted between the All-Bond samples stored for 6 months and the Scotchbond samples stored for 24 h ( $p = 0.085$ ). The  $\chi^2$  test showed that the 4 groups were not significantly different in terms of mode of failure ( $p = 0.587$ ).

## Discussion

Yttrium-stabilized tetragonal zirconia is the most commonly used type of zirconia in dentistry.<sup>9</sup> Thus, this ceramic was used in this study. PANA VIA F 2.0 contains a functional phosphate monomer (10-MDP) that forms a stronger bond to metal oxides such as zirconia oxide. Many researchers believe that PANA VIA F 2.0 is the best choice of cement for bonding to zirconia.<sup>10,11</sup>

Bonding to zirconia can be mechanical or chemical. Numerous studies have assessed the effect of sandblasting with aluminum oxide particles on the zirconia surface. It causes the tetragonal-to-monoclinic phase transformation in zirconia and eventually affects the long-term function of zirconia restorations.<sup>12–14</sup> Phark et al. assessed the bond strength of different kinds of cement to zirconia, with and without sandblasting, and did not suggest the sandblasting of the zirconia surface to increase retention.<sup>15</sup> Reddy et al. showed that the application of a primer provides a stronger bond between zirconia and resin cement than sandblasting.<sup>16</sup> Thus, in this study, we did not perform sandblasting and only assessed the effect of the type of adhesive on the microshear bond strength of resin cement to zirconia.

Since single-step universal adhesives contain a combination of hydrophilic and hydrophobic resins as well as acid and water, hydrolysis occurs, and as a result, the shelf life and primary bond strength decrease. The presence of hydrophilic monomers in these adhesives interferes with polymerization. They serve as a semi-permeable membrane and allow the passage of liquids through the



interface. This increases water sorption, swelling and disintegration.<sup>6,17,18</sup> In 2-bottle universal adhesives such as All-Bond Universal, the components are separate, and thus the bond strength and shelf life of the adhesives increase. Hence, in the current study, we assessed the effect of these factors on microshear bond strength.

In many previous studies on the bond strength of adhesives, macro-tests have been used. Although conducting such a test and the sample preparation are easier, the rate of error and false failures increase due to the larger size of samples.<sup>19</sup> Therefore, to obtain more accurate results, a micro-test was used for the measurement of bond strength in this study. On the other hand, since most loads applied to the teeth, especially those requiring esthetic restorations, are shear forces, the microshear bond strength test was performed in this study.

The results showed that the mean bond strength of All-Bond was higher than that of Scotchbond after 24 h of water storage. This difference can result from several factors. The pH can play a role in this respect and if the pH of the adhesive is acidic, the compatibility of the adhesive and the resin cement decreases. This is mainly due to the inactivation of aromatic amines by acid. These amines play an important role in the chemical curing of materials.<sup>20</sup> Of universal adhesives, All-Bond has less acidic pH (3.2) compared to Scotchbond (2.7). The 10-MDP monomer, present in All-Bond and Scotchbond, also affects bond strength. This monomer is in the composition of several materials, such as a zirconia primer. There are studies that have assessed the microshear bond strength of these materials and all have indicated the important role of this monomer in achieving high bond strength.<sup>21,22</sup>

The 10-MDP monomer has a hydrophobic methacrylate group at one end, with the ability to bond to methacrylate-based restorations and cement, and a polar phosphate group at the other end, which can bond to dental surfaces, zirconia and metal. This property alone is responsible for the optimal efficacy of this monomer used in universal adhesives.<sup>23,24</sup> Research showed that materials with the same monomers do not necessarily possess similar properties.<sup>25</sup> Similarly, despite the presence of the 10-MDP monomer in the composition of both adhesives in our study, different bond strength values were obtained.

The presence of the silane monomer in the composition of Scotchbond Universal is another factor causing a reduction in the bond strength of this adhesive compared to All-Bond Universal, as the silane monomer in acidic conditions (due to the presence of the MDP acidic monomer in water and pH = 2.7) may be unstable because of the reactions of silanol groups. Moreover, the presence of the bisphenol A-glycidyl methacrylate (Bis-GMA) monomer in universal adhesives along with silane and MDP in 1 bottle interferes with the bond of silane and hydroxyl groups (-OH).<sup>26</sup> The new All-Bond Uni-

versal adhesive is supplied in 2 bottles and is dual-cure. Thus, it has a higher polymerization rate, even in the absence of adequate light.

Our study showed that after 6 months of water storage, the All-Bond Universal adhesive showed lower bond strength than Scotchbond Universal. This was in line with the results of Davis et al., who demonstrated that bond strength decreases over time and this reduction depends on the chemical composition of the adhesives.<sup>27</sup> One important factor affecting bond strength is the concentration of a solvent in the composition of the adhesive; higher amounts of the residual solvent dilute the monomer and limit the process of cross-linking of the resin. The solvent remaining in the polymer network forms areas of unreacted monomers that increase the susceptibility to solubility and water sorption.<sup>17,28</sup> According to the product brochure, the approximate percentage of a solvent is 10–15% in Scotchbond Universal and over 20% in All-Bond Universal. This difference in the amount of a solvent affects the clinical performance of the bond and bond strength decreases over time. This is more significant for All-Bond Universal, since it has a higher percentage of a solvent.

Evidence shows that saliva and aqueous environments negatively affect the bond strength of restorations. Ito et al. and Nishitani et al. reported that water sorption occurred in universal adhesives due to the presence of hydrophilic monomers in their structure, and as a result, bond degradation appeared over time.<sup>29,30</sup>

Universal adhesives are self-etching due to the presence of hydrophilic monomers. They contain adequate concentration of water for adequate ionization of acidic monomers with no reduction in the monomer concentration for adequate bond strength. Water causes the ionization of acidic groups and results in the formation of H<sub>3</sub>O<sup>+</sup> ions, which cause the etching of hydroxyapatite.<sup>31</sup> On the other hand, water enhances the elimination of the products of the etching reaction from the environment. An increase in the concentration of water decreases the concentration of acidic monomers, and consequently the strength and adequacy of the bond. An increase in the concentration of hydrophilic monomers increases water sorption over time and decreases bond strength.<sup>32</sup>


Also, there are some other explanations for the reduction of bond strength over time, such as the presence of the hydroxyethylmethacrylate (HEMA) molecule, which is small and liquid, and serves as a solvent in the structure of the bond. When the process of polymerization is almost complete, long-chain monomers in the structure of the polymer are limited. In such conditions, a low-molecular-weight molecule such as HEMA can move in the resin and react with unreacted C=C bonds. This hydrophilic molecule causes greater water sorption in bonds with monomers such as bis-GMA.<sup>24</sup> Scotchbond Universal showed higher stability after 6 months of water storage, which is probably due to the presence of 1–5% of the polyalkenoic acid monomer in its structure.


## Conclusions

The microshear bond strength of resin cement to zirconia depends on the type of adhesive and the duration of water storage. The bond strength of a single-component universal adhesive did not significantly change over time, but the bond strength of a 2-component universal adhesive decreased over time.

### ORCID iDs

Shila Emamieh  <https://orcid.org/0000-0003-0477-353X>

Mahya Elahi  <https://orcid.org/0000-0003-2419-8106>

Amir Ghasemi  <https://orcid.org/0000-0002-2748-1778>

### References

- Giordano R, Sabrosa CE. Zirconia: Material background and clinical application. *Compend Contin Educ Dent*. 2010;31(9):710–715.
- McLean JW. The science and art of dental ceramics. *Oper Dent*. 1991;16(4):149–156.
- Kohorst P, Borchers L, Stempel J, et al. Low-temperature degradation of different zirconia ceramics for dental applications. *Acta Biomater*. 2012;8(3):1213–1220.
- Amaral R, Ozcan M, Bottino MA, Valandro LF. Microtensile bond strength of a resin cement to glass-infiltrated zirconia-reinforced ceramic: The effect of surface conditioning. *Dent Mater*. 2006;22(3):283–290.
- Piasek JR, Wolter SD, Stoner BR. Development of a novel surface modification for improved bonding to zirconia. *Dent Mater*. 2011;27(5):e99–e105.
- Carvalho RF, Rippe MO, Melo RM, Bottino MA, Souza ROA. Resin bond strength to zirconia: Effects of surface treatments and resin cements. *Gen Dent*. 2019;67(1):71–77.
- Van Meerbeek B, De Munck J, Yoshida Y, et al. Buonocore memorial lecture. Adhesion to enamel and dentin: Current status and future challenges. *Oper Dent*. 2003;28(3):215–235.
- Perdigão J, Sezinando A, Monteiro PC. Laboratory bonding ability of a multi-purpose dentin adhesive. *Am J Dent*. 2012;25(3):153–158.
- Zarone F, Russo S, Sorrentino R. From porcelain-fused-to-metal to zirconia: Clinical and experimental considerations. *Dent Mater*. 2011;27(1):83–96.
- Tinschert J, Natt G, Mautsch W, Augthun M, Spiekermann H. Fracture resistance of lithium disilicate-, alumina- and zirconia-based three-unit flexed partial dentures: A laboratory study. *Int J Prosthodont*. 2001;14(3):231–238.
- Casucci A, Monticelli F, Goracci C, et al. Effect of surface pre-treatments on the zirconia ceramic-resin cement micro tensile bond strength. *Dent Mater*. 2011;27(10):1024–1030.
- Attia A, Lehmann F, Kern M. Influence of surface conditioning and cleaning methods on resin bonding to zirconia ceramic. *Dent Mater*. 2011;27(2):207–213.
- Magne P, Paranhos MP, Burnett LH Jr. New zirconia primer improves bond strength of resin-based cements. *Dent Mater*. 2010;26(4):345–352.
- de Castro HL, Corazza PH, Paes-Júnior Tde A, Della Bona A. Influence of Y-TZP ceramic treatment and different resin cements on bond strength to dentin. *Dent Mater*. 2012;28(11):1191–1197.
- Phark JH, Duarte S Jr, Blatz M, Sadan A. An in vitro evaluation of the long-term resin bond to a new densely sintered high-purity zirconium-oxide ceramic surface. *J Prosthet Dent*. 2009;101(1):29–38.
- Reddy SM, Vijitha D, Deepak T, Balasubramanian R, Satish A. Evaluation of shear bond strength of zirconia bonded to dentin after various surface treatments of zirconia. *J Indian Prosthodont Soc*. 2014;14(1):38–41.
- Emamieh S, Sadr A, Ghasemi A, Torabzadeh H, Akhavanzanjani V, Tagami J. Effects of solvent drying time on mass change of three adhesives. *J Conserv Dent*. 2013;16(5):418–422.
- Van Meerbeek B, Yoshihara K, Yoshida Y, Mine A, De Munck J, Van Landuyt KL. State of the art of self-etch adhesives. *Dent Mater*. 2011;27(1):17–28.
- Van Meerbeek B, Peumans M, Poitevin A, et al. Relationship between bond-strength tests and clinical outcomes. *Dent Mater*. 2010;26(2):e100–e121.
- Schittly E, Bouter D, Le Goff S, Degrange M, Attal JP. Compatibility of five self-etching adhesive systems with two resin luting cements. *J Adhes Dent*. 2010;12(2):137–142.
- Seabra B, Arantes-Oliveira S, Portugal J. Influence of multimode universal adhesives and zirconia primer application techniques on zirconia repair. *J Prosthet Dent*. 2014;112(2):182–187.
- Feitosa VP, Ogliaeri FA, Van Meerbeek B, et al. Can the hydrophilicity of functional monomers affect chemical interaction? *J Dent Res*. 2014;93(2):201–206.
- Muñoz MA, Luque-Martinez I, Malaquias P, et al. In vitro longevity of bonding properties of universal adhesives to dentin. *Oper Dent*. 2015;40(3):282–292.
- Lim MJ, Yu MK, Lee KW. The effect of continuous application of MDP-containing primer and luting resin cement on bond strength to tribochemical silica-coated Y-TZP. *Restor Dent Endod*. 2018;43(2):e19.
- Tauscher S, Angermann J, Catel Y, Moszner N. Evaluation of alternative monomers to HEMA for dental applications. *Dent Mater*. 2017;33(7):857–865.
- Lung CY, Matinlinna JP. Aspects of silane coupling agents and surface conditioning in dentistry: An overview. *Dent Mater*. 2012;28(5):467–477.
- Davis EL, Joynt RB, Yu X, Wiecekowsky G Jr. Dentin bonding system shelf life and bond strength. *Am J Dent*. 1993;6(5):229–231.
- Cadenaro M, Breschi L, Rueggeberg FA, et al. Effects of residual ethanol on the rate and degree of conversion of five experimental resins. *Dent Mater*. 2009;25(5):621–628.
- Ito S, Hashimoto M, Wadgaonkar B, et al. Effects of resin hydrophilicity on water sorption and changes in modulus of elasticity. *Biomaterials*. 2005;26(33):6449–6459.
- Nishitani Y, Yoshiyama M, Donnelly AM, et al. Effects of resin hydrophilicity on dentin bond strength. *J Dent Res*. 2006;85(11):1016–1021.
- Hosaka K, Nakajima M, Takahashi M, et al. Relationship between mechanical properties of one-step self-etch adhesives and water sorption. *Dent Mater*. 2010;26(4):360–367.
- Malacarne J, Carvalho RM, de Goes MF, et al. Water sorption/solubility of dental adhesive resins. *Dent Mater*. 2006;22(10):973–980.



# Effect of the interproximal contact level on the perception of smile esthetics

## Wpływ miejsca kontaktu międzyzębowego na odbiór estetyki uśmiechu

Mohammad Ramadan Rayyan<sup>A-F</sup>

Department of Prosthodontics, College of Dentistry, Riyadh Elm University, Saudi Arabia

A – research concept and design; B – collection and/or assembly of data; C – data analysis and interpretation; D – writing the article; E – critical revision of the article; F – final approval of the article

Dental and Medical Problems, ISSN 1644-387X (print), ISSN 2300-9020 (online)

*Dent Med Probl.* 2019;56(3):251–255

### Address for correspondence

Mohammad Ramadan Rayyan  
E-mail: mohammadrayyan1979@gmail.com

### Funding sources

None declared

### Conflict of interest

None declared

Received on February 13, 2019

Reviewed on March 15, 2019

Accepted on May 29, 2019

Published online on September 30, 2019

### Abstract

**Background.** Many dental and facial components affect smile esthetics, and dental professionals' opinions regarding dental esthetics may not always coincide with the perceptions and expectations of the patients.

**Objectives.** This work is designed to determine the dimensions of the interproximal contact areas that are considered the most or least attractive according to a group of laypersons, dentists and technicians.

**Material and methods.** Two photographs of female and male smiles showing a full smile were taken with a Nikon® camera and digitally altered using Adobe® Photoshop. The length of the interproximal contact areas was altered to generate 2 sets of images (3 images of the female and 3 images of the male smile in each set). A group of 40 laypersons, 40 dentists and 40 dental technicians were asked to select the most and the least attractive image in each set.

**Results.** An interproximal contact ratio of 50:40:30 [%] was the most attractive arrangement (40.00% and 38.33% for the female and male smiles, respectively). The 'reversed' ratio of 30:40:50 [%] was the least attractive to the participants (57.50% and 44.17% for the female and male smiles, respectively). There were differences in the rankings of the most and the least attractive smiles among the 3 groups of evaluators.

**Conclusions.** The 'ideal' interproximal contact ratio of 50:40:30 [%] is perceived to be the most attractive. However, the smile esthetics perception among dental professionals is not always in agreement with the perception of laypersons.

**Key words:** esthetics, dental, proximal, smile attractiveness

**Słowa kluczowe:** estetyka, zębowy, proksymalny, atrakcyjność uśmiechu

### Cite as

Rayyan MR. Effect of the interproximal contact level on the perception of smile esthetics. *Dent Med Probl.* 2019;56(3):251–255. doi:10.17219/dmp/109704

### DOI

10.17219/dmp/109704

### Copyright

© 2019 by Wrocław Medical University

This is an article distributed under the terms of the

Creative Commons Attribution 3.0 Unported License (CC BY 3.0)

(<https://creativecommons.org/licenses/by/3.0/>)

## Introduction

Smile is a significant determinant of dental and facial esthetics. Several dental and facial components affect smile esthetics, and a harmonizing esthetic smile requires the successful integration of dental and facial composition.<sup>1</sup> Esthetic treatment should always be preceded by a thorough analysis of both facial and dental composition.<sup>2</sup>

The perception of esthetics is influenced by one's social environment, culture and individual experiences. Considering dental professionals' scientific and professional background, their opinions regarding dental esthetics may differ from the expectations of their patients.<sup>3–11</sup> Thus, it is imperative for dental professionals to continuously study changes in the perception of smile esthetics in their communities.<sup>12</sup>

The length and sequence of the interproximal contact area – an area where 2 adjacent teeth appear to touch – in the maxillary anterior teeth have been considered important factors affecting dental esthetics.<sup>13</sup> Normally, the interproximal contact area between the 2 central incisors is located at the incisal third. The level of the interproximal contact area moves apically as we move posteriorly.<sup>14</sup> For the most attractive smile, the 50:40:30 rule has been proposed, in which the contact area between the maxillary central incisors constitutes 50% of the length of the central incisors; the contact area between the maxillary lateral incisor and the central incisor is 40% of the length of the central incisor; and the contact area between the maxillary canine and the maxillary lateral incisor is 30% of the length of the central incisor.<sup>15</sup> However, further studies are needed to investigate the impact of the length and sequence of the proximal contact area on the perception of smile esthetics.

Therefore, this study aimed to investigate which interproximal contact area dimensions are considered the most attractive among laypersons, dentists and techni-

cians. Furthermore, this study assessed whether there are any differences in the smile esthetic perception between dental professionals and laypersons.

## Material and methods

Ethical approval was obtained from the institutional review board of Riyadh Elm University, Saudi Arabia, before conducting the study (approval No. RC/IRP/2016/398). The sample size calculation was done using the free software G\*Power, v. 3.1.9.213 (<http://www.psychologie.hhu.de/arbeitsgruppen/allgemeine-psychologie-und-arbeitspsychologie/gpower.html>). Assuming the significance level of alpha at  $\leq 0.05$  and an effect size of 0.26, the sample size required to achieve 90% power was 120 subjects (40 in each group).

Two photos were taken with a professional Nikon® camera (D5200; Nikon Corp., Shinagawa, Tokyo, Japan), 1 for a male smile and 1 for a female smile. The photos were then altered digitally using the Adobe® Photoshop CS6 software (Adobe Systems Inc., San Jose, USA) to produce standard, bilaterally symmetrical images. The standard images were modified to produce 2 sets of smile images in order to evaluate the effect of the interproximal contact area on perceived smile esthetics.

In the 1<sup>st</sup> set, the levels of the interproximal contact areas of maxillary anterior teeth in the standard images were altered to produce 3 images for the female and 3 images for the male smiles with a different order of the proximal contact lengths (Fig. 1):

- ideal – the ratio of the interproximal contact areas followed the 50:40:30 rule;
- equal – the interproximal contact areas were equal (50:50:50);
- reversed – the ratio of the interproximal contact areas was reversed (30:40:50).

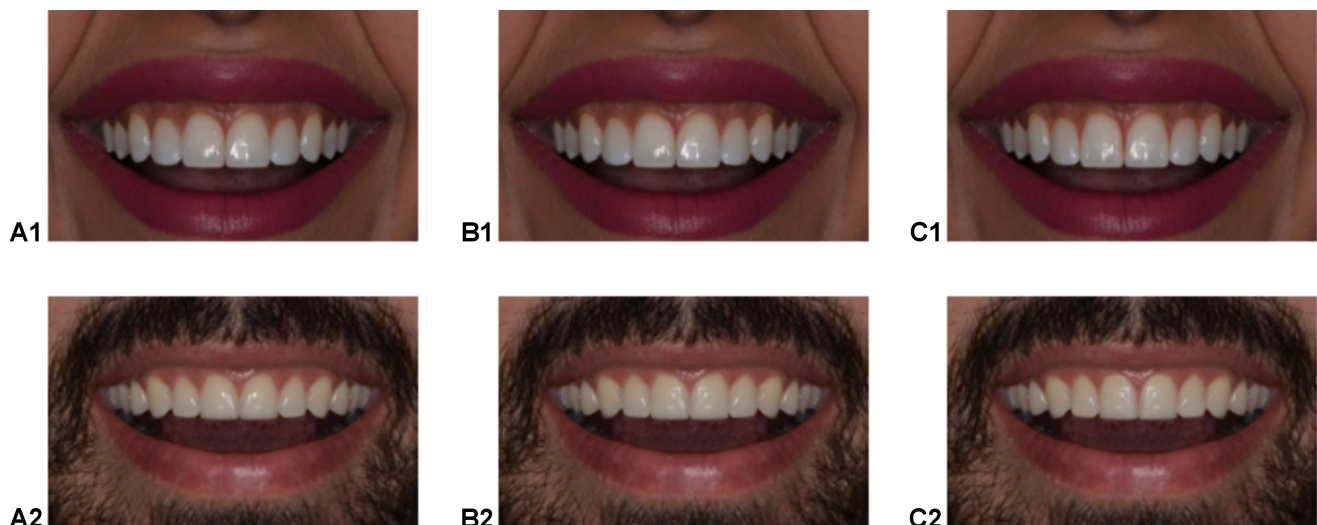

Fig. 1. The 1<sup>st</sup> set of images with a different order of the proximal contact lengths

A1 and A2 – 'ideal' 50:40:30 [%] ratio, female and male smiles, respectively; B1 and B2 – 'equal' 50:50:50 [%] ratio, female and male smiles, respectively; C1 and C2 – 'reversed' 30:40:50 [%] ratio, female and male smiles, respectively.

In the 2<sup>nd</sup> set, the levels of all interproximal contact areas in the standard images were modified apically or coronally to produce 3 images for the female and 3 images for the male smiles with different proximal contact lengths (Fig. 2):

- reduced – the ratio of the interproximal contact areas was decreased (40:30:20);
- ideal – the ratio of the interproximal contact areas followed the 50:40:30 rule;
- exaggerated – the ratio of the interproximal contact areas was increased (60:50:40).

The ratios of interproximal contact lengths in all images were based on the length of the left maxillary central incisor.

The images were presented to the participants as slides, with 3 smile images on each slide, on a Samsung tablet screen, 8.4 inches, LTE (Galaxy Tab S; Samsung, Seoul, South Korea). Data collection was conducted via a secured online research platform (<https://www.qualtrics.com>). One hundred and twenty participants consented to participate in the study. The participants were divided into 3 groups: 40 laypersons; 40 dentists; and 40 dental technicians. Among all participants, 79 were males (M) and 41 were females (F). Their age ranged between 20 and 60 years with a median age of 31 years. The group of laypersons consisted of adults undergoing prosthodontic or restorative esthetic treatment (veneers or crowns). Only dentists practicing esthetic dentistry were included in the 2<sup>nd</sup> group. The group of technicians comprised only ceramist technicians. Any participants complaining of visual impairment were excluded from the study.

The smile images were examined by each participant under adequate standard light and they were given enough time to render their final decision regarding their preference.

The statistical analysis of their responses was performed using the IBM SPSS Statistics for Windows software, v. 22.0 (IBM Corp., Armonk, USA). The  $\chi^2$  tests were carried out to test for significant differences between the groups. The significance level was set at  $p \leq 0.05$ .

## Results

For the 1<sup>st</sup> set of images, the order of the proximal contact ratios was changed. The results show that the ‘ideal’ 50:40:30 ratio was considered the most attractive to the majority of the participants (40.00% and 38.33% for the female and male smiles, respectively). The ‘reversed’ 30:40:50 ratio was the least attractive arrangement to the participants (57.50% and 44.17% for the female and male smiles, respectively) (Table 1).

The majority of the dentists and technicians selected the ‘ideal’ 50:40:30 ratio as the most attractive, both in the female and male smiles (F: 52.5%; M: 35.0% and F: 42.5%; M: 45.0%, respectively). However, more laypersons selected the ‘equal’ 50:50:50 ratio for the female smile (F: 42.5%) and the ‘reversed’ 30:40:50 ratio for the

Table 1. Smile esthetics perceived by the participants in terms of the interproximal contact area sequence ratio

Sequence ratio	Most attractive	Middle	Least attractive	Total
Female smile				
ideal 50:40:30 [%]	48 (40.00)	47 (39.17)	25 (20.83)	120
reversed 30:40:50 [%]	28 (23.33)	23 (19.17)	69 (57.50)	120
equal 50:50:50 [%]	44 (36.67)	50 (41.66)	26 (21.67)	120
Male smile				
ideal 50:40:30 [%]	46 (38.33)	44 (36.67)	30 (25.00)	120
reversed 30:40:50 [%]	40 (33.33)	27 (22.50)	53 (44.17)	120
equal 50:50:50 [%]	34 (28.34)	49 (40.83)	37 (30.83)	120

Data presented as number (percentage).

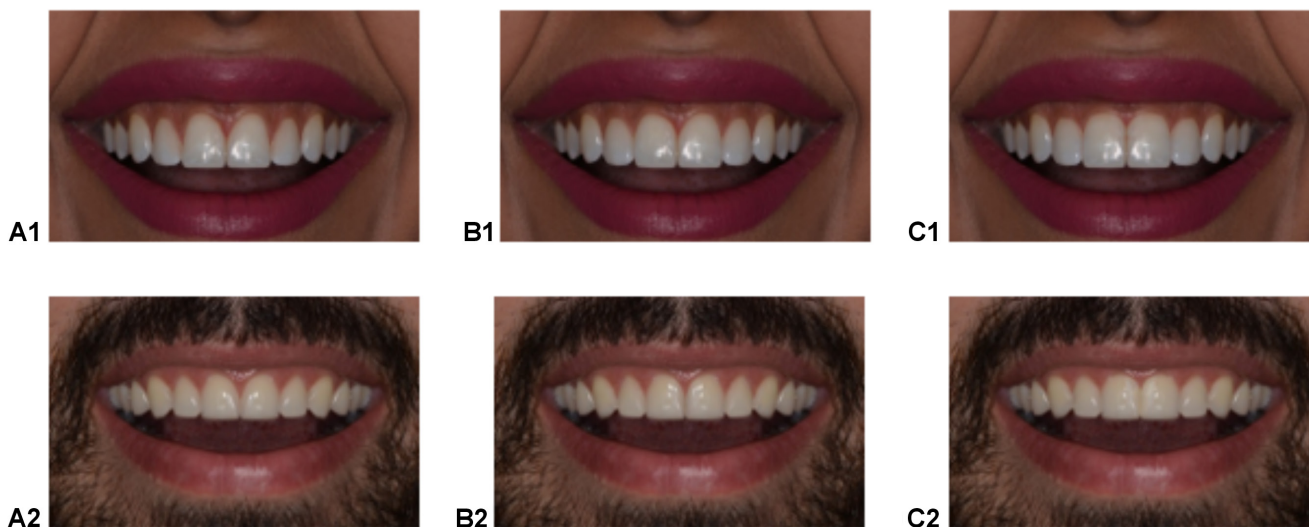

Fig. 2. The 2<sup>nd</sup> set of images with different proximal contact lengths

A1 and A2 – ‘reduced’ 40:30:20 [%] ratio, female and male smiles, respectively; B1 and B2 – ‘ideal’ 50:40:30 [%] ratio, female and male smiles, respectively; C1 and C2 – ‘exaggerated’ 60:50:40 [%] ratio, female and male smiles, respectively.

male smile (M: 42.5%) as the most attractive. On the other hand, the majority of the dentists perceived the 'reversed' 30:40:50 ratio as the least attractive (F: 70.0%; M: 55.0%), as did the majority of the technicians (F: 57.5%; M: 47.5%). However, a higher percentage of laypersons selected both the 'ideal' 50:40:30 and 'equal' 50:50:50 ratios as the least attractive male smile.

No statistically significant differences in the ranking were found among the 3 groups ( $p = 0.093$  for the female smiles;  $p = 0.507$  for the male smiles) (Table 2).

In the 2<sup>nd</sup> set of images, the length of the interproximal contact areas was different. The 'ideal' 50:40:30 contact area length was considered the most attractive by the majority of the participants (F: 50.83%; M: 38.33%). The 'exaggerated' 60:40:50 length was the least attractive arrangement for the female smile (F: 61.66%), whereas the 'reduced' 40:30:20 length was the least attractive for the male smile (M: 44.17%) (Table 3).

**Table 2.** Univariate analysis for the association between perceived smile esthetics in terms of various interproximal contact area ratios and the type of respondent

Factor	Respondent type			p-value
	dentist (n = 40)	layperson (n = 40)	technician (n = 40)	
MA (F)				
ideal 50:40:30 [%]	21 (52.5)	10 (25.0)	17 (42.5)	0.093
reversed 30:40:50 [%]	5 (12.5)	13 (32.5)	10 (25.0)	
equal 50:50:50 [%]	14 (35.0)	17 (42.5)	13 (32.5)	
MA (M)				
ideal 50:40:30 [%]	14 (35.0)	14 (35.0)	18 (45.0)	0.507
reversed 30:40:50 [%]	13 (32.5)	17 (42.5)	10 (25.0)	
equal 50:50:50 [%]	13 (32.5)	9 (22.5)	12 (30.0)	
LA (F)				
ideal 50:40:30 [%]	6 (15.0)	13 (32.5)	6 (15.0)	0.109
reversed 30:40:50 [%]	28 (70.0)	18 (45.0)	23 (57.5)	
equal 50:50:50 [%]	6 (15.0)	9 (22.5)	11 (27.5)	
LA (M)				
ideal 50:40:30 [%]	9 (22.5)	14 (35.0)	7 (17.5)	0.139
reversed 30:40:50 [%]	22 (55.0)	12 (30.0)	19 (47.5)	
equal 50:50:50 [%]	9 (22.5)	14 (35.0)	14 (35.0)	
MA (F)				
ideal 50:40:30 [%]	22 (55.0)	18 (45.0)	21 (52.5)	0.054
exaggerated 60:50:40 [%]	2 (5.0)	11 (27.5)	4 (10.0)	
reduced 40:30:20 [%]	16 (40.0)	11 (27.5)	15 (37.5)	
MA (M)				
ideal 50:40:30 [%]	14 (35.0)	14 (35.0)	18 (45.0)	0.507
exaggerated 60:50:40 [%]	13 (32.5)	9 (22.5)	12 (30.0)	
reduced 40:30:20 [%]	13 (32.5)	17 (42.5)	10 (25.0)	
LA (F)				
ideal 50:40:30 [%]	3 (7.5)	7 (17.5)	4 (10.0)	0.017*
exaggerated 60:50:40 [%]	29 (72.5)	16 (40.0)	29 (72.5)	
reduced 40:30:20 [%]	8 (20.0)	17 (42.5)	7 (17.5)	
LA (M)				
ideal 50:40:30 [%]	7 (17.5)	7 (17.5)	5 (12.5)	0.079
exaggerated 60:50:40 [%]	25 (62.5)	16 (40.0)	27 (67.5)	
reduced 40:30:20 [%]	8 (20.0)	17 (42.5)	8 (20.0)	

Data presented as number (percentage).

MA – most attractive; LA – least attractive; F – female smile; M – male smile;

\* statistically significant ( $p \leq 0.05$ ); the  $\chi^2$  test.

**Table 3.** Smile esthetics perceived by the participants in terms of the interproximal contact area length ratio

Sequence ratio	Most attractive	Middle	Least attractive	Total
Female smile				
ideal 50:40:30 [%]	61 (50.83)	45 (37.50)	14 (11.67)	120
exaggerated 60:50:40 [%]	17 (14.17)	29 (24.17)	74 (61.66)	120
reduced 40:30:20 [%]	42 (35.00)	46 (38.33)	32 (26.67)	120
Male smile				
ideal 50:40:30 [%]	46 (38.33)	44 (36.67)	30 (25.00)	120
exaggerated 60:50:40 [%]	34 (28.34)	49 (40.83)	37 (30.83)	120
reduced 40:30:20 [%]	40 (33.33)	27 (22.50)	53 (44.17)	120

Data presented as number (percentage).

The majority of the dentists and technicians selected the 'ideal' 50:40:30 ratio as the most attractive, both in the female and male smiles (F: 55.0%; M: 35.0% and F: 52.5%; M: 45.0%), whereas the majority of laypersons selected the 'ideal' 50:40:30 ratio in the female smile and the 'reduced' 40:30:20 ratio in the male smile as the most attractive (F: 45.0%; M: 42.5%). No statistically significant differences in the ranking were found between the 3 groups ( $p = 0.054$  for the female smiles;  $p = 0.507$  for the male smiles) (Table 2).

In terms of the least attractive smiles, the 'exaggerated' 60:40:50 length ratio was selected by both the dentists (F: 72.5%; M: 62.5%) and the technicians (F: 72.5%; M: 67.5%), whereas more laypersons selected the 'reduced' 40:30:20 length ratio as the least attractive (F: 42.5%; M: 42.5%). The analysis revealed statistically significant differences in the ranking of the 2<sup>nd</sup> set of images of the female smile between the 3 groups ( $p = 0.017$ ) (Table 2).

## Discussion

Presenting images of smiles to participants in order to investigate their perception of attractiveness regarding smile esthetics is a method which can be frequently found in the literature, though the specifics vary from study to study. In the current study, cropped images, showing only the subjects' smiles were used in order to eliminate the potential distraction of the evaluator's perception.<sup>16</sup>

The results show that the 'ideal' interproximal contact area ratio arrangement proposed by Morley and Eubank – 50:40:30 – is considered the most attractive among dentists and dental technicians.<sup>acc.15</sup> On the other hand, a higher percentage of laypersons selected the 'equal' arrangement for the female smile and the 'reversed' one for the male smile as the most attractive. Similarly, in examining the ratio of the length of the interproximal contact areas, the majority of the participants ranked the 'ideal' ratio (50:40:30) as the most attractive. One exception was the rating of the male smile by the layperson group, where a higher percentage found the 'reduced' ratio (40:30:20) to be the most attractive.

In agreement with previous studies, our findings revealed variations in the preferences of dental professionals and laypersons regarding smile esthetics.<sup>3,5,6,10,11</sup> These variations, although minor, highlight the need for effective communication between dentists and dental technicians to ensure that the planned esthetic treatment meets the individual patient's expectations.

The interproximal contact areas can be altered by esthetic gingival surgeries, orthodontic treatment, or designing and contouring dental restorations. Moreover, when replacing missing teeth, the interproximal contact area represents the connector that joins pontics and retainers. It is common practice to increase the length of the connector area to ensure the strength and rigidity of fixed dental prostheses and to compensate for the recession of the interproximal papilla, which often follows tooth extraction. However, these alterations in the proximal contact area must be carefully planned to make sure they are within the acceptable esthetic range.<sup>5</sup>

The perception of esthetics could be affected by the interaction of multiple variables. In the current study, as with similar ones which preceded it, standardized photographs were used and only 1 esthetic variable was changed per set of images. This was done to isolate each variable and to investigate its individual effect on the perception of smile esthetics. Nevertheless, this limitation should be taken into consideration when interpreting the results of the current study.

## Conclusions

The 'ideal' interproximal contact ratio (50:40:30) regarding the sequence and length is perceived as the most attractive arrangement, whereas the 'reversed' sequence ratio (30:40:50) and 'exaggerated' length ratio (60:50:40) are perceived as the least attractive arrangement. There are differences in perception between dental professionals and laypersons regarding the attractive order and length of proximal contact areas.

### ORCID iDs

Mohammad Ramadan Rayyan  <https://orcid.org/0000-0001-9677-1608>

### References

- Nomura S, Freitas KMS, Silva PPCD, et al. Evaluation of the attractiveness of different gingival zeniths in smile esthetics. *Dental Press J Orthod*. 2018;23(5):47–57.
- Omar H, Tai YT. Perception of smile esthetics among dental and nondental students. *J Educ Ethics Dent*. 2014;4(2):54–60.
- Carlsson GE, Wagner IV, Odman P, et al. An international comparative multicenter study of assessment of dental appearance using computer-aided image manipulation. *Int J Prosthodont*. 1998;11(3):246–254.
- Kokich VO Jr, Kiyak HA, Shapiro PA. Comparing the perception of dentists and lay people to altered dental esthetics. *J Esthet Dent*. 1999;11(6):311–324.
- Kokich VO, Kokich VG, Kiyak HA. Perceptions of dental professionals and laypersons to altered dental esthetics: Asymmetric and symmetric situations. *Am J Orthod Dentofacial Orthop*. 2006;130(2):141–151.
- Foulger TE, Tredwin CJ, Gill DS, Moles DR. The influence of varying maxillary incisal edge embrasure space and interproximal contact area dimensions on perceived smile aesthetics. *Br Dent J*. 2010;209(3):E4.
- Fonseca Jardim da Motta A, Nelson Mucha J, Gomes de Souza MM. Influence of certain tooth characteristics on the esthetic evaluation of a smile. *Dental Press J Orthod*. 2012;17(3):e1–e7.
- Cooper GE, Tredwin CJ, Cooper NT, Petrie A, Gill DS. The influence of maxillary central incisor height-to-width ratio on perceived smile aesthetics. *Br Dent J*. 2012;212(12):589–599.
- Assad Duarte ME, Martins Machado R, Fonseca Jardim da Motta A, Nelson Mucha J, Trindade Motta A. Morphological simulation of different incisal embrasures: Perception of laypersons, orthodontic patients, general dentists and orthodontists. *J Esthet Restor Dent*. 2017;29(1):68–78.
- Al Taki A, Hamdan AM, Mustafa Z, Hassan M, Abu-Alhuda S. Smile esthetics: Impact of variations in the vertical and horizontal dimensions of the maxillary lateral incisors. *Eur J Dent*. 2017;11(4):514–520.
- Sulikowski AV, Yoshida A. Three-dimensional management of dental proportions: A new aesthetic principle: "The frame of reference". *Quintessence Dent Technol*. 2002;25:8–20.
- Stappert CF, Tarnow DP, Tan JH, Chu SJ. Proximal contact areas of the maxillary anterior dentition. *Int J Periodontics Restorative Dent*. 2010;30(5):471–477.
- Morley J, Eubank J. Macroesthetic elements of smile design. *J Am Dent Assoc*. 2001;132(1):39–45.
- Krishnan V, Daniel ST, Lazar D, Asok A. Characterization of posed smile by using visual analog scale, smile arc, buccal corridor measures, and modified smile index. *Am J Orthod Dentofacial Orthop*. 2008;133(4):515–523.
- Mollabashi V, Abolvardi M, Akhlaghian M, Ghaffari MI. Smile attractiveness perception regarding buccal corridor size among different facial types. *Dent Med Probl*. 2018;55(3):305–312.
- Jørnung J, Fardal Ø. Perceptions of patients' smiles: A comparison of patients' and dentists' opinions. *J Am Dent Assoc*. 2007;138(12):1544–1553;quiz 1613–1614.





# Comparison of soft and hard tissue changes between symmetric and asymmetric extraction patterns in patients undergoing orthodontic extractions

## Porównanie zmian tkanek miękkich i twardych pomiędzy metodami ekstrakcji symetrycznej i asymetrycznej u pacjentów leczonych ekstrakcyjnie ze wskazań ortodontycznych

Sarah Irfan<sup>A–D</sup>, Mubassar Fida<sup>E,F</sup>

Section of Dentistry, Department of Surgery, Aga Khan University Hospital, Karachi, Pakistan

A – research concept and design; B – collection and/or assembly of data; C – data analysis and interpretation; D – writing the article; E – critical revision of the article; F – final approval of the article

Dental and Medical Problems, ISSN 1644-387X (print), ISSN 2300-9020 (online)

*Dent Med Probl.* 2019;56(3):257–263

### Address for correspondence

Sarah Irfan  
E-mail: sarahirfan88@yahoo.com

### Funding sources

None declared

### Conflict of interest

None declared

Received on March 29, 2019

Reviewed on April 26, 2019

Accepted on May 22, 2019

Published online on September 30, 2019

### Cite as

Irfan S, Fida M. Comparison of soft and hard tissue changes between symmetric and asymmetric extraction patterns in patients undergoing orthodontic extractions. *Dent Med Probl.* 2019;56(3):257–263. doi:10.17219/dmp/109568

### DOI

10.17219/dmp/109568

### Copyright

© 2019 by Wrocław Medical University

This is an article distributed under the terms of the Creative Commons Attribution 3.0 Unported License (CC BY 3.0) (<https://creativecommons.org/licenses/by/3.0/>)

## Abstract

**Background.** Orthodontic treatment modalities and biomechanics are important factors influencing soft and hard tissues.

**Objectives.** The aim of this study was to compare soft and hard tissue changes after implementing asymmetric and symmetric extraction patterns.

**Material and methods.** A retrospective cross-sectional study was conducted using the orthodontic files of 62 patients from the dental clinics of a tertiary care hospital. Patients were divided into 2 groups, each of 31 patients. Group 1 referred to the symmetric extraction patterns (SEP), whereas group 2 regarded the asymmetric extraction patterns (AEP). The Wilcoxon signed-rank test was used to determine differences between the initial and final cephalometric parameters. The Mann–Whitney *U*-test was used to compare the treatment changes between SEP and AEP. The SEP and AEP groups were divided into subgroups for further analyses. The Kruskal–Wallis test was used to determine significant differences in the cephalometric changes among the different subgroups. In order to further establish inter-group differences, a pairwise comparison between the subgroups was made using the Mann–Whitney *U*-test.

**Results.** In the symmetric group, the pre- and post-treatment values for all soft tissue variables, upper incisor-sella-nasion plane angle (UI-SN), lower incisor mandibular plane angle (L-IMPA), and Frankfurt-mandibular plane angle (FMA) showed significant differences ( $p \leq 0.05$ ). In the asymmetric group, none of the soft tissue parameters showed any significant difference in the pre- and post-treatment values; however, FMA and L-IMPA differed significantly ( $p \leq 0.05$ ). The parameters UI-SN and FMA as well as all soft tissue variables except Z-angle (Z), were significantly different between the SEP and AEP groups. The medians and interquartile ranges (IQRs) of the cephalometric changes among the subgroups were compared using the Kruskal–Wallis test. All soft tissues parameters except Z showed significant differences.

**Conclusions.** The symmetric extraction patterns leads to a greater change in the patient's profile, whereas asymmetric extractions can be carried out to remedy occlusal discrepancies without the risk of profile flattening. While employing premolar extractions aiming to reduce the facial height, due consideration with respect to biomechanics must be given.

**Key words:** tooth extraction, incisor, premolar

**Słowa kluczowe:** ekstrakcja zęba, siekacz, ząb przedtrzonowy

## Introduction

One of the most essential reasons why patients seek orthodontic treatment is to improve their facial appearance.<sup>1,2</sup> The patient's profile is predominantly associated with ideal facial esthetics. A convex profile with an unesthetic display of incisors at rest and procumbent lips is displeasing. In such a case, an orthodontist faces a dilemma whether to extract the teeth or not. The employment of either of the 2 treatment modalities (extraction or non-extraction) has been a debatable issue.<sup>3,4</sup> Treating patients with balanced soft tissue profiles becomes even more difficult. In such cases, discrepancies in dental parameters such as crowding, rotations or increased incisal inclinations may lead to an extraction decision for long-term stability.

Another leading reason for extractions is the dentoalveolar protrusion in patients with normal skeletal bases. Closing extraction spaces by retracting the anterior teeth can significantly improve dental inclinations and the soft tissue profile. The extractions of all first premolars, or upper first and lower second premolars are employed in the cases with the bimaxillary dental protrusion. Skeletal dysplasias, e.g., maxillary prognathism, may produce certain features, like procumbent soft tissues and protrusive anterior dentition, which leads to an excessive display of the gingivae, lip incompetency and the tension of the mentalis muscle on lip closure. Premolar extractions are often required to remedy such problems.<sup>5,6</sup>

Asymmetric extraction patterns (AEP) can be chosen when one or more teeth are congenitally missing,<sup>7,8</sup> an asymmetric molar relationship is present, the facial midline is deviated, or significant dental arch asymmetries are present.<sup>9</sup> Asymmetric extraction therapy in Class II malocclusion may require only 1 premolar extraction or 3 premolar extractions. Mandibular incisor extraction is an alternative option to the extraction of lower premolars in carefully selected cases, such as Class I malocclusion with moderate crowding in the lower anterior teeth and little or no crowding in the upper arch, cases with midline deviation, Bolton's discrepancy, increased lower incisor inclination, Class III incisal relationship, and cases with minimal overbite and overjet.<sup>10-12</sup> The important advantages of this option are as follows: a harmonious profile can be maintained; treatment time and cost may be reduced; and more stable results can be achieved.

Implementing treatment modalities that maintain the facial equilibrium while correcting occlusal disharmonies involves an unceasing learning process.<sup>13</sup> Differences in treatment modalities and biomechanics are important factors influencing soft tissues.<sup>14</sup> Changes in the soft-tissue contour result from the interplay between certain anatomical and functional variables, including lip length and thickness, the architecture and function of facial muscles, and ethnicity.<sup>15-17</sup> The change in dental inclinations and the resulting alteration of the lip position, achieved with orthodontic treatment, has been extensively studied.<sup>18-21</sup>

However, most studies have compared the profile changes in extraction vs non-extraction treatment modalities.<sup>22,23</sup> In the present study, we compared the changes in the hard and soft tissue parameters after implementing AEP and symmetric extraction patterns (SEP).

## Material and methods

This cross-sectional study was approved by the Ethical Review Committee of Aga Khan University Hospital in Karachi, Pakistan. The sample size was calculated considering 80% as power of the study at a significance level of 5%. This revealed that a minimum of 31 individuals were necessary in each of the 2 groups. Therefore, 62 patients of Pakistani origin reporting for orthodontic treatment were retrospectively selected from the files of the orthodontic department. These patients, treated between 2008 and 2014, were divided into 2 groups, according to their treatment approach. Group 1 consisted of 31 patients treated with SEP, whereas group 2 consisted of 31 patients treated with AEP. The symmetric group included patients with the extraction of all first premolars (all 4's), or upper first and lower second premolars (upper 4's, lower 5's). The asymmetric group included patients with the extraction of 3 premolars in any combination or a single lower incisor extraction.

The inclusion criteria comprised patients aged  $\geq 12$  years undergoing orthodontic treatment with planned extractions, presence of all maxillary and mandibular permanent teeth up to second molars, and complete orthodontic records. The exclusion criteria were the following: presence of any supernumerary or impacted tooth; any history of facial trauma or previous orthodontic treatment; and syndromic or isolated cleft lip and palate (CLP) patients.

All patients were treated with preadjusted fixed appliances ( $0.022 \times 0.028$ "), slotted by postgraduate students trained by the same supervisor. The wire sequence began with 0.012" nitinol (NiTi) archwires, followed by 0.014", 0.016" and 0.018" ones. Leveling was achieved using the accentuated and/or reversed curve of Spee archwires. In the cases of premolar extractions, the retraction of canines was carried out with 0.018" stainless steel (SS) archwires. After the canine retraction, the incisor retraction was done with  $0.017 \times 0.025$ " SS bull loop. Class II elastics were used for minor anteroposterior adjustments at the final stages with  $0.017 \times 0.025$ " SS archwires. Pre- and post-treatment cephalometric radiographs were taken, and tracings were done using transparent 0.003" acetate paper and 0.03 mm HB lead pencil. Each radiograph was manually traced by the same operator. The soft tissue parameters measured were as follows: E-line-upper and lower lip distance (EU and EL, respectively); S-line-upper and lower lip distance (SU and SL, respectively); Z-angle (Z); and nasolabial angle (NL). The skeletal parameters measured were as follows: sella-nasion plane-point A angle (SNA); sella-nasion plane-point B angle (SNB);

point A-point B angle (ANB); facial angle (FA); sella-nasion plane-gonion-gnathion plane angle (SN-GoGn); and Frankfurt-mandibular plane angle (FMA). The dental parameters measured were upper incisor-sella-nasion plane angle (UI-SN) and lower incisor-mandibular plane angle (L-IMPA). All angular measurements were made to the nearest 0.5° and the linear measurements – to 0.5 mm. To identify any intra-examiner error, 10 radiographs were randomly selected and retraced by the same investigator after an interval of 1 week. The intraclass correlation coefficient (ICC) was used to evaluate the level of agreement, which proved to be excellent (0.8–0.9) for all variables.

The data was analyzed using IBM SPSS Statistics for Windows, v. 19 (IBM Corp., Armonk, USA). Descriptive statistics, e.g., frequencies and proportions, were calculated. The applied Kolmogorov–Smirnov test showed that the data had a non-normal distribution. Medians and interquartile ranges (IQRs) for each variable were calculated for each group. To determine significant differences between the initial and final cephalometric parameters, the Wilcoxon signed-rank test was used. The Mann–Whitney *U*-test was applied to compare the treatment changes between the SEP and AEP groups.

The SEP and AEP groups were divided into subgroups for further analyses. The Kruskal–Wallis test was used to determine significant differences in the cephalometric parameters among the different subgroups. In order to further determine inter-group differences, a pairwise comparison between the subgroups was made using the Mann–Whitney *U*-test.

The difference in cephalometric parameters, calculated by subtracting the post-treatment cephalometric mea-

surements from the pre-treatment values, was appropriately indicated by signs + or –.

A *p*-value ≤0.05 was considered statistically significant.

## Results

The SEP group consisted of 31 patients with mean age of 18.62 ±7.64 years, whereas AEP group consisted of 31 patients with mean age of 16.80 ±4.40 years.

The frequency of different extraction patterns in the SEP and AEP group is shown in Table 1.

In the SEP group, the pre- and post-treatment values for all soft tissue variables, i.e., EU, EL, SU, SL, Z, and NL, were significantly different (*p* < 0.001). Both dental variables, i.e., UI-SN and L-IMPA, were also significantly different (*p* ≤ 0.05 and *p* ≤ 0.001, respectively), whereas among the skeletal variables, only FMA showed a statistically significant difference in the pre- and post-treatment assessment (*p* ≤ 0.001) (Table 2).

Table 1. Frequency of different extraction patterns in the symmetric and asymmetric groups

Extraction group	Extraction pattern	Frequency n (%)
Symmetric	all first premolars	27 (87.1)
	upper first and lower second premolars	4 (12.9)
	total	31 (100)
Asymmetric	single lower incisor	24 (77.4)
	3 premolars in any combination	7 (22.6)
	total	31 (100)

Data presented as number (percentage).

Table 2. Pre- and post-treatment changes in the cephalometric parameters in the symmetric extraction patterns (SEP) and asymmetric extraction patterns (AEP) groups

Parameter	Asymmetric extraction				<i>p</i> -value	Symmetric extraction				<i>p</i> -value
	pre-treatment		post-treatment			pre-treatment		post-treatment		
	median	IQR	median	IQR		median	IQR	median	IQR	
EU [mm]	–3.00	–6.00, –2.00	–3.00	–5.00, –2.00	0.586	–1.00	–3.00, 1.00	–4.00	–5.00, –2.00	0.000**
EL [mm]	1.00	–2.00, 2.00	0.00	–2.00, 2.00	0.854	2.00	–2.00, 4.00	–1.00	–3.00, 1.00	0.000**
SU [mm]	1.00	0.00, 2.00	0.00	–1.00, 2.00	0.161	2.00	0.00, 4.00	0.00	–2.00, 1.00	0.000**
SL [mm]	3.00	2.00, 4.00	3.00	1.00, 4.00	0.818	4.00	1.00, 6.00	1.00	–1.00, 3.00	0.000**
Z [°]	63.00	60.00, 72.00	68.00	62.00, 75.00	0.148	64.00	56.00, 72.00	68.00	64.00, 74.00	0.001**
NL [°]	105.00	95.00, 109.00	100.00	95.00, 107.00	0.553	97.00	90.00, 105.00	105.00	94.00, 114.00	0.001**
SNA [°]	80.00	78.00, 84.00	80.00	79.00, 83.00	0.171	82.00	79.00, 83.00	82.00	80.00, 83.00	0.388
SNB [°]	76.00	75.00, 80.00	77.00	75.00, 79.00	0.758	77.00	75.00, 79.00	77.00	74.00, 79.00	0.933
ANB [°]	3.00	2.00, 5.00	3.00	2.00, 5.00	0.283	4.00	3.00, 6.00	4.00	3.00, 5.00	0.951
FA [°]	87.00	85.00, 89.00	88.00	83.00, 91.00	0.535	85.00	82.00, 87.00	86.00	82.00, 87.00	0.908
SN-GoGn [°]	32.00	30.00, 34.00	32.00	29.00, 35.00	0.322	33.00	30.00, 36.00	32.00	28.00, 35.00	0.284
FMA [°]	23.00	22.00, 27.00	25.00	22.00, 29.00	0.021*	27.00	26.00, 31.00	28.00	25.00, 30.00	0.000**
UI-SN [°]	105.00	102.00, 111.00	107.00	100.00, 108.00	0.930	110.00	105.00, 117.00	102.00	96.00, 105.00	0.002*
L-IMPA [°]	101.00	96.00, 103.00	96.00	90.00, 105.50	0.029*	101.00	95.00, 105.00	95.00	92.00, 100.00	0.000**

IQR – interquartile range; EU – E-line-upper lip distance; EL – E-line-lower lip distance; SU – S-line-upper lip distance; SL – S-line-lower lip distance; Z – Z-angle; NL – nasolabial angle; SNA – sella-nasion plane-point A angle; SNB – sella-nasion plane-point B angle; ANB – point A-point B angle; FA – facial angle; SN-GoGn – sella-nasion plane-gonion-gnathion plane angle; FMA – Frankfurt-mandibular plane angle; UI-SN – upper incisor-sella-nasion plane angle; L-IMPA – lower incisor-mandibular plane angle; \* *p* ≤ 0.05; \*\* *p* ≤ 0.001; the Wilcoxon signed-rank test.

In the AEP group, none of the soft tissue parameters showed any significant difference in the pre- and post-treatment values. In the pre- and post-treatment assessment, a statistically significant difference was found in FMA among the skeletal variables and in L-IMPA among the dental variables ( $p \leq 0.05$ ) (Table 2).

To compare the differences in the pre- and post-treatment values of all variables between the SEP and AEP groups, the Mann–Whitney  $U$ -test was applied and it showed that all soft tissue parameters except Z were significantly different between the SEP and AEP

**Table 3.** Comparison of the cephalometric changes between the symmetric extraction patterns (SEP) and asymmetric extraction patterns (AEP) groups

Parameter	Asymmetric extraction		Symmetric extraction		$p$ -value
	median	IQR	median	IQR	
EU [mm]	0.00	–1.00, 1.50	2.00	0.00, 3.00	0.003*
EL [mm]	0.00	–1.00, 2.00	2.00	0.00, 4.00	0.001**
SU [mm]	0.00	–1.00, 2.00	2.00	1.00, 4.00	0.002*
SL [mm]	0.00	–1.00, 2.50	3.00	1.00, 4.00	0.000**
Z [°]	–1.00	–4.00, 1.00	–3.00	–9.00, 0.00	0.150
NL [°]	0.00	–4.50, 4.50	–8.00	–12.00, 0.00	0.001**
SNA [°]	0.00	–1.00, 0.00	1.00	–1.00, 3.00	0.070
SNB [°]	0.00	–1.50, 1.00	0.00	–1.00, 1.00	0.977
ANB [°]	0.00	–1.00, 0.00	0.00	0.00, 1.00	0.007*
FA [°]	0.00	–2.50, 1.00	0.00	–1.00, 2.00	0.593
SN-GoGn [°]	–1.00	–2.50, 2.00	0.00	–1.00, 1.00	0.518
FMA [°]	–3.00	–3.00, 0.50	0.00	–1.00, 3.00	0.026*
UI-SN [°]	3.00	–7.50, 7.00	12.00	2.00, 14.00	0.000**
L-IMPA [°]	2.00	–1.50, 8.50	5.00	0.00, 9.00	0.544

\*  $p \leq 0.05$ ; \*\*  $p \leq 0.001$ ; the Mann–Whitney  $U$ -test.

**Table 4.** Comparison of the cephalometric changes among different subgroups

Parameter	SEP		AEP		$p$ -value
	all 4's	upper 4's, lower 5's	lower incisor	3 premolars	
	median (IQR)		median (IQR)		
EU [mm]	2.00 (2.00, 3.00)	4.50 (1.50, 6.00)	0.00 (–1.00, 0.75)	2.00 (–1.00, 4.00)	0.002*
EL [mm]	2.00 (1.00, 4.00)	3.00 (0.50, 5.00)	0.00 (–1.75, 1.00)	2.00 (2.00, 2.00)	0.004*
SU [mm]	2.00 (1.00, 4.00)	3.50 (0.50, 5.00)	0.00 (–2.00, 1.00)	0.00 (0.00, 3.00)	0.001**
SL [mm]	3.00 (1.00, 4.00)	5.50 (0.25, 7.00)	0.50 (–2.00, 1.00)	2.00 (–1.00, 3.00)	0.001**
Z [°]	–3.00 (–9.00, 0.00)	–12.50 (–18.00, –1.75)	–1.00 (–4.00, 0.00)	–3.00 (–4.00, 4.00)	0.172
NL [°]	–7.00 (–12.00, –7.00)	–12.00 (–13.50, –11.25)	1.50 (0.00, 10.00)	–8.00 (–10.00, –4.00)	0.000**
SNA [°]	1.00 (–1.00, 3.00)	1.00 (0.25, 2.20)	0.00 (–1.00, 0.00)	1.00 (0.00, 1.00)	0.053
SNB [°]	0.00 (–1.00, 1.00)	1.50 (–2.25, 3.00)	0.00 (–2.75, 1.00)	0.00 (–1.00, 2.00)	0.771
ANB [°]	0.00 (0.00, 1.00)	1.50 (0.00, 3.00)	–1.00 (–1.00, 0.00)	0.00 (–1.00, 1.00)	0.009*
FA [°]	0.00 (–1.00, 2.00)	–5.00 (–5.00, –1.25)	0.00 (–3.75, 1.00)	0.00 (–1.00, 10.00)	0.063
SN-GoGn [°]	0.00 (–1.00, 1.00)	–1.50 (–3.00, 1.50)	0.00 (–3.00, 2.00)	0.00 (–4.00, 1.00)	0.647
FMA [°]	0.00 (–1.00, 2.00)	4.50 (0.00, 6.00)	–1.00 (–3.00, 1.75)	0.00 (–1.00, 0.00)	0.042*
UI-SN [°]	12.00 (2.00, 14.00)	25.00 (25.00, 32.00)	–3.00 (–9.50, 5.00)	9.00 (5.00, 10.00)	0.000**
L-IMPA [°]	5.00 (1.00, 9.00)	–6.00 (–11.25, –1.50)	3.50 (–1.00, 7.25)	5.00 (–6.00, 10.00)	0.047

SEP – symmetric extraction patterns; AEP – asymmetric extraction patterns; \*  $p \leq 0.05$ ; \*\*  $p \leq 0.001$ ; the Kruskal–Wallis test.

groups. Among the skeletal parameters, FMA and ANB, whereas among the dental parameters, UI-SN showed a significant difference between the SEP and AEP groups (Table 3).

The medians and IQRs of the cephalometric changes among the subgroups were compared using the Kruskal–Wallis test (Table 4). All soft tissues parameters except Z showed significant differences. Other parameters that differed significantly among the subgroups include ANB, FMA and UI-SN.

Table 5 shows a pairwise comparison of the cephalometric changes between the particular subgroups.

## Discussion

The present study determined the soft as well as hard tissue alterations after different extraction patterns. Apart from the treatment modality, other factors, such as head posture, muscle function, weight, age, and gender, may also affect the interpretation of real soft tissue displacement.<sup>24,25</sup> Careful diagnosis and treatment planning can eliminate undesirable changes in the soft tissue profile post-treatment. A relaxed lip posture during performing the cephalograms may reduce the variability and the strategic employment of technological advances, such as digital photography and videography, may help better determine the modality of choice.<sup>26</sup>

In a previous study of Class II cases, a greater reduction in maxillary incisor inclination was noticed in patients who were treated by extracting maxillary first premolars only as compared to those who were treated with all first premolar extractions.<sup>27</sup>

Table 5. Pairwise comparison of the cephalometric changes between the subgroups

Parameter	Treatment modalities					
	all 4's vs U 4's, L 5's	all 4's vs lower incisor	all 4's vs 3 premolars	U 4's, L 5's vs lower incisor	3 premolars vs lower incisor	3 premolars vs U 4's, L 5's
	<i>p</i> -values					
EU	0.114	0.001*	0.667	0.005*	0.256	0.153
EL	0.721	<0.001**	0.076	0.230	0.280	0.557
SU	0.570	<0.001**	0.167	0.043*	0.195	0.174
SL	0.246	<0.001**	0.218	0.044*	0.105	0.122
Z	0.147	0.154	0.564	0.063	0.668	0.128
NL	0.076	<0.001**	0.701	0.001*	0.002*	0.022*
SNA	0.473	0.068	1.000	0.018*	0.026*	0.298
SNB	0.450	0.817	0.539	0.386	0.532	0.564
ANB	0.238	0.062	0.722	0.015*	0.113	0.242
FA	0.050*	0.136	0.401	0.134	0.113	0.033*
SN-GoGn	0.341	0.676	0.343	0.571	0.352	0.848
FMA	0.098	0.062	0.282	0.015*	0.615	0.082
UI-SN	0.124	<0.001**	0.701	0.019*	0.005*	0.183
L-IMPA	0.005*	0.248	0.814	0.025*	0.686	0.086

U – upper; L – lower; \*  $p \leq 0.05$ ; \*\*  $p \leq 0.001$ ; the Mann–Whitney *U*-test.

In the study conducted by Janson et al., the extraction of a single maxillary premolar was compared with the extraction of 2 maxillary and 1 mandibular premolars.<sup>28</sup> The latter group showed increased palatal tipping and dentoalveolar height of incisors after the treatment.<sup>28</sup> In our results, UI-SN showed a significant variance between the SEP and AEP groups. A reduction in UI-SN was noted in the SEP group, whereas in the AEP group, an increase in the UI-SN inclination was found. This was due to the non-extraction approach in the upper arch, which resolved crowding in the maxilla at the expense of inclination.

In a similar study by Janson et al., the group which underwent the extraction of 2 maxillary and 1 mandibular premolars showed a reduction in L-IMPA, whereas the group in which the extraction of only 1 premolar was carried out showed the proclination of lower incisors.<sup>28</sup> This could be attributed to the fact that crowding and the curve of Spee were managed without any mandibular extraction in that group.<sup>29,30</sup> In our study, L-IMPA showed a significant reduction in the post-treatment assessment of both groups and no significant difference was observed amid the SEP and AEP groups, as lower incisors were retracted in both groups. However, further SEP subgroup analysis showed that L-IMPA significantly differed between the “all 4’s” and “upper 4’s, lower 5’s” extraction subgroups. The former group showed a decrease in L-IMPA, whereas an increase in L-IMPA was noted in the latter. This could be due to the fact that the “upper 4’s, lower 5’s” extraction pattern was employed in Class II molar cases, where the extraction spaces were predominantly utilized to correct the molar relationship rather than to affect L-IMPA.

Weyrich and Lisson noted that both EU and EL increased in both 4 premolars and 2 maxillary premolars extraction groups.<sup>27</sup> Also, NL became obtuse, but the result was not significant. However, Janson et al. reported that EU decreased to a greater extent in the cases where 3 premolars had been extracted.<sup>28</sup> Our results showed a significant reduction in both EU and EL in the SEP group, whereas no significant change was noticed in the AEP group. The reason is that the asymmetric extractions, e.g., single maxillary premolar, 3 premolars in different quadrants or lower incisor are aimed to correct the occlusal discrepancies and the associated soft tissues remain unaffected.<sup>31</sup>

Scott Conley and Jernigan attained a reduction of 8 mm in the overjet, associated with a significant decrease in dental inclination and the lip profile, leading to an increase in NL.<sup>32</sup> However, it was stated that the response of the lip contour was not consistent with the change in dental inclination; therefore, the possible alterations of the soft tissue profile should not cause any concern in the cases with dental discrepancies but with balanced soft tissues.<sup>32</sup> Katsaros and Katsaros et al. also emphasized that the nasal and chin growth affect soft tissues, and those changes are more imperative than the effects of extraction patterns.<sup>33,34</sup>

Kirschneck et al. in their study of all first premolars extraction in borderline cases reported a significant decrease in SNA along with a reduction in incisor inclination, and no significant change in SNB<sup>35</sup>; our study showed no significant change in either.

Orthodoxy, one of the aims of premolar extraction may be to decrease the vertical facial height. However, in our study, we found that FMA significantly increased in both groups

in the post-treatment assessment. While comparing the SEP and AEP groups, the difference was also significant and showed a greater increase in the asymmetric group. These findings are in concordance with the study conducted by Zafarmand and Zafarmand, where the bicuspid extraction theory (neither 2 nor 4 premolar extractions) for reducing the facial height did not provide any significant changes post-treatment.<sup>36</sup> The vertical angle and the lower anterior facial height increased in both of their groups. This was also highlighted in a study conducted by Staggers, according to whom the biomechanical justification for this could be the intrinsic extrusive effect of most orthodontic modalities, e.g., the protraction of posterior teeth, which can unfavorably compensate any reduction in the facial height.<sup>37</sup>


This study was based primarily on the changes in soft and hard tissue parameters assessed on cephalometric images. It is now advocated that soft tissue changes should be evaluated with three-dimensional (3D) imaging techniques, both pre- and post-treatment, to correctly assess the treatment changes. There was an unequal distribution of extraction patterns in our groups, which could affect the results. A small sample size indicates that further studies need to be conducted to ensure that the results are generalizable to the population and that alternate treatment mechanics produce variable results.

## Conclusions

The present study determined the alterations in soft and hard tissues after different extraction patterns. It can be concluded that a significant change in soft tissue parameters in the SEP group led to a greater improvement in the patient's profile. The inclinations of the upper and lower dentition can be improved in both the SEP and AEP groups, which may help position the teeth over the basal bone and enhance long-term stability. Asymmetric extractions can be carried out to remedy occlusal discrepancies without any risk of profile flattening. While employing premolar extractions aiming to reduce the facial height, due consideration with respect to biomechanics must be given.

### ORCID iDs

Sarah Irfan  <https://orcid.org/0000-0003-2598-052X>

Mubassar Fida  <https://orcid.org/0000-0003-4842-9896>

### References

1. Holdaway RA. A soft-tissue cephalometric analysis and its use in orthodontic treatment planning. Part I. *Am J Orthod.* 1983;84(1):1–28.
2. Peck H, Peck S. A concept of facial esthetics. *Angle Orthod.* 1970;40(4):284–318.
3. Holdaway RA. A soft tissue cephalometric analysis and its use in orthodontic treatment planning, Part II. *Am J Orthod.* 1984;85(4):279–293.
4. Young TM, Smith RJ. Effects of orthodontics on the facial profile: A comparison of changes during nonextraction and four premolar extraction treatment. *Am J Orthod Dentofacial Orthop.* 1993;103(5):452–458.
5. Beattie JR, Paquette DE, Johnston LE. The functional impact of extraction and non-extraction treatments: A long-term comparison in patients with “borderline”, equally susceptible Class II malocclusions. *Am J Orthod Dentofacial Orthop.* 1994;105(5):444–449.
6. Hayashida H, Ioi H, Nakata S, Takahashi I, Counts AL. Effects of retraction of anterior teeth and initial soft tissue variables on lip changes in Japanese adults. *Eur J Orthod.* 2011;33(4):419–426.
7. Faerovig E, Zachrisson BU. Effects of mandibular incisor extraction on anterior occlusion in adults with Class III malocclusion and reduced overbite. *Am J Orthod Dentofacial Orthop.* 1999;115(2):113–124.
8. Proffit WR. *Contemporary Orthodontics.* 3<sup>rd</sup> ed. St. Louis, MO: Mosby; 2000:251.
9. Melgaço CA, Araújo MTS. Asymmetric extractions in orthodontics. *Dental Press J Orthod.* 2012;17(2):151–156.
10. Bahreman AA. Lower incisor extraction in orthodontic treatment. *Am J Orthod.* 1977;72(5):560–567.
11. Kokich VG, Shapiro PA. Lower incisor extraction in orthodontic treatment. Four clinical reports. *Angle Orthod.* 1984;54(2):139–153.
12. Valinoti JR. Mandibular incisor extraction therapy. *Am J Orthod Dentofacial Orthop.* 1994;105(2):107–116.
13. Yogosawa F. Predicting soft tissue profile changes concurrent with orthodontic treatment. *Angle Orthod.* 1990;60(3):199–206.
14. Bishara SE, Cummins DM, Jakobsen JR, Zaher AR. Dentofacial and soft tissue changes in Class II, division 1 cases treated with and without extractions. *Am J Orthod Dentofacial Orthop.* 1995;107(1):28–37.
15. Kasai K. Soft tissue adaptability to hard tissues in facial profiles. *Am J Orthod Dentofacial Orthop.* 1998;113(6):674–684.
16. Subtelny JD, Sakuda M. Muscle function, oral malformation, and growth changes. *Am J Orthod.* 1966;52(7):495–517.
17. Oliver BM. The influence of lip thickness and strain on upper lip response to incisor retraction. *Am J Orthod.* 1982;82(2):141–149.
18. Drobocky OB, Smith RJ. Changes in facial profile during orthodontic treatment with extraction of four first premolars. *Am J Orthod Dentofacial Orthop.* 1989;95(3):220–230.
19. Talass MF, Talass L, Baker RC. Soft-tissue profile changes resulting from retraction of maxillary incisors. *Am J Orthod Dentofacial Orthop.* 1987;91(5):385–394.
20. Mamandras AH. Linear changes of the maxillary and mandibular lips. *Am J Orthod Dentofacial Orthop.* 1988;94(5):405–410.
21. Guo Y, Han X, Xu H, Ai D, Zeng H, Bai D. Morphological characteristics influencing the orthodontic extraction strategies for Angle's class II division 1 malocclusions. *Prog Orthod.* 2014;15(1):44.
22. Lim HJ, Ko KT, Hwang HS. Esthetic impact of premolar extraction and nonextraction treatments on Korean borderline patients. *Am J Orthod Dentofacial Orthop.* 2008;133(4):524–531.
23. Moseling KP, Woods MG. Lip curve changes in females with premolar extraction or nonextraction treatment. *Angle Orthod.* 2004;74(1):51–62.
24. Burstone CJ. Lip posture and its significance in treatment planning. *Am J Orthod.* 1967;53(4):262–284.
25. Zierhut EC, Joondeph DR, Artun J, Little RM. Long-term profile changes associated with successfully treated extraction and nonextraction Class II Division 1 malocclusions. *Angle Orthod.* 2000;70(3):208–219.
26. Maetevorakul S, Viteporn S. Factors influencing soft tissue profile changes following orthodontic treatment in patients with Class II Division 1 malocclusion. *Prog Orthod.* 2016;17:13.
27. Weyrich C, Lisson JA. The effect of premolar extractions on incisor position and soft tissue profile in patients with Class II, Division 1 malocclusion. *J Orofac Orthop.* 2009;70(2):128–138.
28. Janson G, Lenza EB, Francisco R, Aliaga-Del Castillo A, Garib D, Lenza MA. Dentoskeletal and soft tissue changes in class II subdivision treatment with asymmetric extraction protocols. *Prog Orthod.* 2017;18(1):39.
29. Bernstein RL, Preston CB, Lampasso J. Leveling the curve of Spee with a continuous archwire technique: A long term cephalometric study. *Am J Orthod Dentofacial Orthop.* 2007;131(3):363–371.
30. Millett DT, Cunningham SJ, O'Brien KD, Benson PE, de Oliveira CM. Treatment and stability of class II division 2 malocclusion in children and adolescents: A systematic review. *Am J Orthod Dentofacial Orthop.* 2012;142(2):159–169.

31. Janson G, Carvalho PE, Cançado RH, de Freitas MR, Henriques JF. Cephalometric evaluation of symmetric and asymmetric extraction treatment for patients with Class II subdivision malocclusions. *Am J Orthod Dentofacial Orthop.* 2007;132(1):28–35.
32. Scott Conley R, Jernigan C. Soft tissue changes after upper premolar extraction in Class II camouflage therapy. *Angle Orthod.* 2006;76(1):59–65.
33. Katsaros C. Profile changes following extraction vs nonextraction orthodontic treatment in a pair of identical twins. *J Orofac Orthop.* 1996;57(1):56–59.
34. Katsaros C, Ripplinger B, Högel A, Berg R. The influence of extraction versus non-extraction orthodontic treatment on the soft tissue profile. *J Orofac Orthop.* 1996;57(6):354–365.
35. Kirschneck C, Proff P, Reicheneder C, Lippold C. Short-term effects of systematic premolar extraction on lip profile, vertical dimension and cephalometric parameters in borderline patients for extraction therapy – a retrospective cohort study. *Clin Oral Investig.* 2016;20(4):865–874.
36. Zafarmand AH, Zafarmand MM. Premolar extraction in orthodontics: Does it have any effect on patient's facial height? *J Int Soc Prev Community Dent.* 2015;5(1):64–68.
37. Staggers JA. Vertical changes following first premolar extraction. *Am J Orthod Dentofacial Orthop.* 1994;105(1):19–24.





# Management of patients with disk displacement without reduction of the temporomandibular joint by arthrocentesis alone, plus hyaluronic acid or plus platelet-rich plasma

## Leczenie pacjentów z przemieszczeniem krążka stawowego z zablokowaniem stawu skroniowo-żuchwowego wyłącznie przez artrocentezę lub dodatkowo z kwasem hialuronowym lub osoczem bogatopłytkowym

Mahmood Hasan Toameh<sup>1,A,D,F</sup>, Issam Alkhouri<sup>1,A,F</sup>, Mohammed Ammar Karman<sup>2,A-C</sup>

<sup>1</sup> Department of Oral and Maxillofacial Surgery, Faculty of Dental Medicine, University of Damascus, Syria

<sup>2</sup> National Dental Center for Syrian board and specialization, Damascus, Syria

A – research concept and design; B – collection and/or assembly of data; C – data analysis and interpretation; D – writing the article; E – critical revision of the article; F – final approval of the article

Dental and Medical Problems, ISSN 1644-387X (print), ISSN 2300-9020 (online)

Dent Med Probl. 2019;56(3):265–272

### Address for correspondence

Mahmood Hasan Toameh  
E-mail: mahtoameh@gmail.com

### Funding sources

None declared

### Conflict of interest

None declared

Received on March 13, 2019

Reviewed on April 24, 2019

Accepted on May 13, 2019

Published online on September 30, 2019

### Cite as

Toameh MH, Alkhouri I, Karman MA. Management of patients with disk displacement without reduction of the temporomandibular joint by arthrocentesis alone, plus hyaluronic acid or plus platelet-rich plasma. *Dent Med Probl.* 2019;56(3):265–272. doi:10.17219/dmp/109329

### DOI

10.17219/dmp/109329

### Copyright

© 2019 by Wrocław Medical University

This is an article distributed under the terms of the Creative Commons Attribution 3.0 Unported License (CC BY 3.0) (<https://creativecommons.org/licenses/by/3.0/>)

## Abstract

**Background.** Disk displacement without reduction (DDwoR) is one of the most common temporomandibular joint disorders (TMDs); it can manifest itself in joint pain and limited mouth opening. Nowadays, many arthrocentesis techniques are used with no consensus on which technique is optimal.

**Objectives.** The aim of this study was to investigate the efficacy of 3 techniques in the treatment of TMD known as DDwoR and to compare them in order to determine whether one is superior to the others.

**Material and methods.** A prospective study was conducted between May 2015 and June 2018. The sample consisted of 30 adult patients (6 males and 24 females; mean age: 38.87 ± 6.40 years) with DDwoR, confirmed with magnetic resonance imaging (MRI). The patients were randomly divided into 3 groups according to the treatment technique applied: arthrocentesis only (control); arthrocentesis plus hyaluronic acid (HA); and arthrocentesis plus platelet-rich plasma (PRP). The maximum mouth opening (MMO) as well as pain intensity and masticatory efficiency on a visual analog scale (VAS) were measured at the time of diagnosis (baseline) and at 1-month, 3-month, 6-month, and 9-month follow-up appointments. The significance level was set at 0.05 for all statistical tests.

**Results.** The 3 techniques resulted in significant improvement in MMO and all VAS parameters. The one-way analysis of variance (ANOVA) revealed significant differences ( $p < 0.05$ ) in the variables between the 3 groups. The increase in MMO in the PRP and HA groups was significantly greater than in the case of the control group, whereas no significant difference was found between the PRP and HA groups. The pain intensity and masticatory efficiency results were significantly better in the PRP group than in the HA group or the control group; at the same time, no significant differences were noted between the HA group and the control group.

**Conclusions.** Despite the fact that patients benefited from all of the 3 techniques, arthrocentesis plus PRP appeared to be superior to arthrocentesis plus HA or arthrocentesis alone.

**Key words:** temporomandibular joint disorders, temporomandibular joint arthrocentesis, platelet-rich plasma, hyaluronic acid

**Słowa kluczowe:** zaburzenia stawu skroniowo-żuchwowego, artrocenteza stawu skroniowo-żuchwowego, osocze bogatopłytkowe, kwas hialuronowy

## Introduction

Disc displacement without reduction (DDwoR) accounts for 35.7% of temporomandibular joint disorders (TMDs).<sup>1</sup> The articular disc is displaced relative to the condyle when the mouth is open or closed, and the symptoms include severe pain in the temporomandibular joint (TMJ), limitation of mouth opening and, in unilateral displacements, deviation of the mandible to the painful side.<sup>2</sup>

The pathogenesis of this temporomandibular joint dysfunction has pointed to biochemical factors, separate from the disc displacement theory.<sup>3</sup> For example, inflammatory reactions that occur in TMJ are essential for the development and progression of the disease, including high levels of inflammatory mediators in the synovial fluid, such as interleukin 1 beta (IL-1 $\beta$ ), tumor necrosis factor alpha (TNF- $\alpha$ ) and others. Furthermore, the disintegration of the important component of the synovial fluid – hyaluronic acid (HA) – leads to a decrease in the viscosity of the synovial fluid and the deterioration of the joint proteoglycan matrix.<sup>4</sup>

Additionally, many researchers have stated that increased friction of the articulating surfaces might be a pivotal cause of the articular disk displacement. Therefore, in any suggested procedure, the abovementioned pathologies must be taken into consideration.<sup>5</sup>

Many conservative approaches have been proposed throughout the years, including occlusal splint therapy,<sup>6</sup> physical therapy,<sup>7</sup> pharmacotherapy,<sup>8</sup> and arthrocentesis. Nitzan et al. first described TMJ arthrocentesis as the simplest form of surgery aiming to remove the inflamed synovial fluid from the joint space, restore the viscosity of the synovial fluid and get rid of the adhesions by applying hydraulic pressure.<sup>9</sup> It is considered the first surgical choice in patients who do not respond to conservative treatment.<sup>10</sup>

Later, many arthrocentesis techniques have been developed; some studies have mentioned the benefit of additional medication following arthrocentesis, e.g., with corticosteroids, HA and platelet-rich plasma (PRP).

Intra-articular HA preparations are widely used in orthopedics for their curative effects, such as reducing pain,<sup>11</sup> lubricating the joint surfaces, preventing degeneration by decreasing friction, and providing cushioning to absorb pressure and vibration.<sup>12</sup>

On the other hand, the primary advantage of PRP treatment is the topical administration of platelet-derived growth factors (PDGFs), which are involved in healing and regenerating the damaged tissue as well as regulating inflammatory mediators<sup>13</sup> and stimulating the HA synthesis.<sup>14</sup>

The medical literature is abundant in studies on the optimal procedure for dealing with TMDs. Therefore, the aim of the present study was not just to evaluate the efficacy of 3 techniques in the treatment of TMJ DDwoR, but also to compare them in order to determine whether arthrocentesis plus PRP is superior to arthrocentesis plus HA or arthrocentesis only.

## Material and methods

### Study design

A prospective study with a 9-month follow-up period was conducted between May 2015 and June 2018 at the Department of Oral and Maxillofacial Surgery, Faculty of Dental Medicine of the University of Damascus, Syria.

This study was carried out with the approval of the university Ethics Committee at the Ministry of Higher Education of Syria (protocol No. 1394), and written informed consent was obtained from all the patients.

### Sample size estimation

The required sample size was calculated using the G\* power software v. 3.1.8 (Heinrich Heine University, Düsseldorf, Germany) using the following assumptions in accordance with a study by Hegab et al.<sup>15</sup>:  $\alpha = 0.05$ ; study power: 90%; and effect size: 0.85. Twenty-seven patients were required, so 30 patients (10 patients in each group) were enrolled in the current study to avoid attrition affecting the results.

### Patient selection

Patients were selected from a large group admitted to the Department of Oral and Maxillofacial Surgery, Faculty of Dental Medicine of the University of Damascus, Syria, who had been clinically and radiologically (magnetic resonance imaging – MRI) diagnosed with unilateral TMJ DDwoR. All patients had been unsuccessfully treated using conservative therapies (pharmacotherapy, soft diet, jaw exercises, or occlusal splint therapy) for at least 3 months.

The study sample included 30 adult patients – 6 males (20%) and 24 females (80%) – and their mean age was  $38.87 \pm 6.40$  years.

The inclusion into the study was based on the diagnosis of DDwoR with limited mouth opening according to the Diagnostic Criteria for Temporomandibular Disorders (DC/TMD)<sup>16</sup> as follows:

– clinical criteria:

- the jaw locked so that the mouth does not open wholly,
- the limitation in jaw opening severe enough to interfere with the ability to eat,
- the maximum assisted opening (passive stretch) movement, including vertical incisal overlap, <40 mm;

– radiological criteria:

- in the maximum intercuspal position, the posterior band of the disk located anterior to the 11:30 position and the intermediate zone of the disk anterior to the condylar head,
- at full opening, the intermediate zone of the disk located anterior to the condylar head.

The exclusion criteria comprised patients with systemic diseases (rheumatoid arthritis, psoriatic arthritis and juvenile arthritis) or who had received treatment with anticoagulants.

According to the undertaken arthrocentesis technique, the patients were randomly assigned to 1 of the 3 following equal groups (Table 1):

- group I – patients receiving arthrocentesis with 100 mL of Ringer’s lactate solution only (control group);
- group II – patients receiving an intra-articular injection of 1 mL of HA following arthrocentesis with 100 mL of Ringer’s lactate (HA group);
- group III – patients receiving an intra-articular injection of 1 mL of PRP following arthrocentesis with 100 mL of Ringer’s lactate (PRP group).

## Outcome measurements

The preoperative maximum mouth opening (MMO) was measured in mm as the distance between the incisal edge of the upper and lower central incisors. The visual analog scale (VAS; range: 0–10) values for pain intensity and mastication efficiency were recorded. For the pain intensity assessment, the scale ranged from 0, representing no pain, to 10, representing the worst imaginable pain. For masticatory efficiency, the scale ranged from 0 – eating only liquid foods, to 10 – eating any solid and/or hard foods.<sup>17</sup> These clinical parameters were assessed by the same operator at the time of diagnosis (baseline) and at each follow-up appointment (1-month, 3-month, 6-month, and 9-month).

## Injection technique

Intravenous sedation was performed in order to gain complete control of the pain, and then the skin surface was disinfected with povidone iodine. Once the joint was locally anesthetized, 2 points were marked over the glenoid fossa and the articular eminence along the canthal–tragus line (Holmlund–Helsing line), similar to the entry points used for arthroscopic procedures (Fig. 1).<sup>18,19</sup>

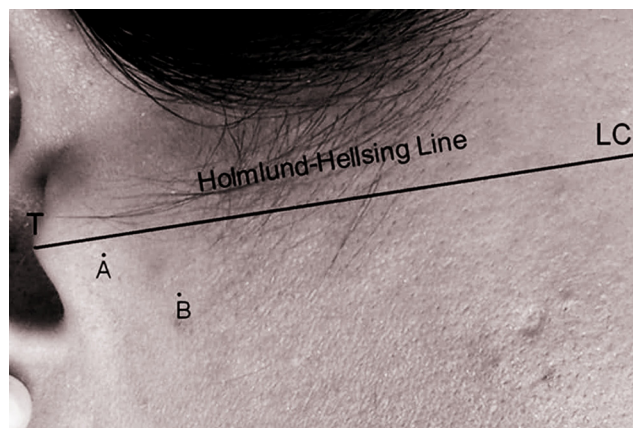


Fig. 1. Technique used for injections into the temporomandibular joint (TMJ) LC – lateral canthus; T – tragus; A – 10 mm from the middle of the tragus and 2 mm below the canthotragal line; B – 10 mm further along the canthotragal line and 10 mm below it.

A 19-gauge needle was then inserted into the upper joint cavity (UJC) at the glenoid fossa (point A), approx. 5 mL of Ringer’s lactate was injected to distend UJC and some movements of the patient’s mandible were performed for several minutes in order to mix Ringer’s lactate with the synovial fluid (in our practice, we have found this to be a very important step, since without the proper mixing of the synovial fluid and Ringer’s lactate solution, arthrocentesis does not proceed easily and effectively). Then, another 19-gauge needle was slowly and carefully inserted into the area of the articular eminence (point B) until the solution appeared in order to establish a free flow of the irrigation solution through UJC. The joint was irrigated with 100 mL of Ringer’s lactate solution. The outflow needle was intermittently blocked in an attempt to get rid of the adhesions and to distend UJC by injecting under pressure, and the patient’s mandible was gently moved to release the disk if it was stuck. At the end of lavage, the needles were removed in group I; 1 mL of HA was injected into the joint before removing the needles in group II and 1 mL of PRP was injected into the joint before removing the needles in group III.

During the follow-up phase, we did not administer any physical therapy or splint therapy.

Table 1. Comparison of the baseline values of the outcome variables between the study groups

Variable	Control	HA group	PRP group	p-value
Sample size	n = 10	n = 10	n = 10	1.000
Sex				
female	8	7	9	0.945
male	2	3	1	
Age [years]	40.53	38.26	37.82	0.910
MMO [mm]	33.30 ± 3.71	31.60 ± 4.55	32.30 ± 8.68	0.960
Pain intensity [VAS]	6.40 ± 1.57	5.60 ± 1.43	6.10 ± 1.59	0.897
Masticatory efficiency [VAS]	3.60 ± 1.38	4.40 ± 1.65	3.90 ± 1.48	0.955

Data for MMO, pain intensity and masticatory efficiency presented as mean ± standard deviation (SD).

Control group – arthrocentesis only; HA group – arthrocentesis plus hyaluronic acid (HA); PRP group – arthrocentesis plus platelet-rich plasma (PRP); MMO – maximum mouth opening; VAS – visual analog scale.

## Platelet-rich plasma preparation

Platelet-rich plasma was prepared according to the following protocol:

1.5 cm<sup>3</sup> of anticoagulant (3.8% sodium citrate) was drawn into a 20-cubic centimeter syringe prior to taking blood and the inside walls were coated with the anticoagulant; 13.5 cm<sup>3</sup> of venous blood was then drawn; afterward, the blood and the anticoagulant were mixed by slowly swinging the syringe and the gathered blood was transfused into a Ycellbio™ tube (Ycellbio Medical Co. Ltd., Seoul, South Korea).

The tube was then centrifuged with the following parameters: 3400 rpm for 4 min; and relative centrifugal force (RCF) of 1.888 × g.

After separation, 1 mL of pure platelet-rich plasma (P-PRP), without any leukocytes, was carefully aspirated into a separate syringe; immediately before injecting it into the joint, it was activated with 0.1 mL of 10% calcium chloride.

## Statistical analysis

The software SPSS Statistics for Windows, v. 17.0 (SPSS Inc., Chicago, USA) was used for the data management and statistical analysis. The level of significance was set at 0.05 for all statistical tests.

The data fit normal distribution, as confirmed by the Shapiro–Wilk tests. The paired sample *t*-test was used to compare the mean values of the variables (MMO, pain intensity and masticatory efficiency) over time.

The one-way analysis of variance (ANOVA) was used to determine any differences in the mean values and standard deviations (*SD*) of the variables (MMO, pain intensity and masticatory efficiency) between the 3 groups. When there was a significant difference among the means, the Šidák significant difference post-hoc test ( $\alpha = 0.05$ ) was applied.

## Results

In general, from a descriptive point of view, it was evident that the mean values of MMO, pain intensity and masticatory efficiency increased during the 9 months of follow-up for each of the 3 arthrocentesis techniques (Table 2).

No adverse effects or major complications were reported except for some minor complications associated with arthrocentesis, such as swelling of the preauricular region, caused by lateral extravasation of the irrigation fluid, which disappeared spontaneously after 2 or 3 days.

Statistically significant differences between the 2 periods (before treatment and at the 9-month follow-up) were observed for each of the values: MMO, pain intensity and masticatory efficiency. In the control group, they were 9.3 mm, –3.8 and 3.6, respectively; in the HA group – 13.8 mm, –4.4 and 4.0, respectively, and in the PRP group – 15.9 mm, –5.4 and 5.1, respectively.

The one-way ANOVA revealed significant differences ( $p < 0.05$ ) in the variables (MMO, pain intensity and masticatory efficiency) between the 3 groups (Fig. 2–4).

**Table 2.** Comparison of the mean values of maximum mouth opening (MMO), pain intensity and masticatory efficiency before the treatment and after 9 months of observation between the study groups

Variable	Group	Period	Mean	SD	Mean difference	<i>p</i> -value
MMO [mm]	control	before treatment	33.30	3.71	9.300	0.002*
		after 9 months	42.60	4.32		
	HA group	before treatment	31.60	4.55	13.800	0.000*
		after 9 months	45.40	3.53		
	PRP group	before treatment	32.30	8.68	15.900	0.000*
		after 9 months	48.20	5.11		
Pain intensity [VAS]	control	before treatment	6.40	1.57	–3.800	0.000*
		after 9 months	2.60	2.91		
	HA group	before treatment	5.60	1.43	–4.400	0.000*
		after 9 months	1.20	2.39		
	PRP group	before treatment	6.10	1.59	–5.400	0.000*
		after 9 months	0.70	0.82		
Masticatory efficiency [VAS]	control	before treatment	3.60	1.38	3.600	0.000*
		after 9 months	7.20	2.74		
	HA group	before treatment	4.40	1.65	4.000	0.000*
		after 9 months	8.40	2.22		
	PRP group	before treatment	3.90	1.48	5.100	0.000*
		after 9 months	9.00	0.66		

\* statistically significant.

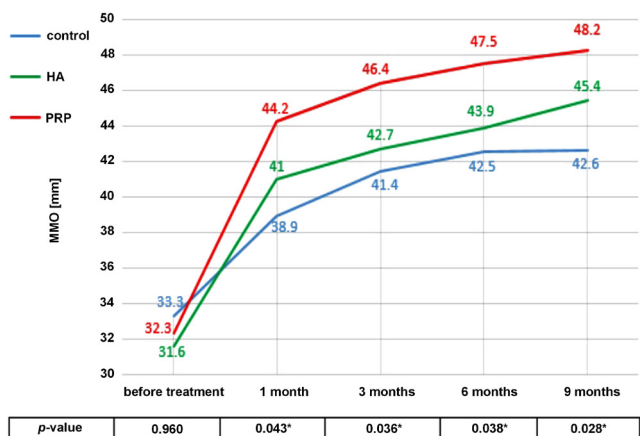


Fig. 2. Mean of maximum mouth opening at the time of the study

\* statistically significant.

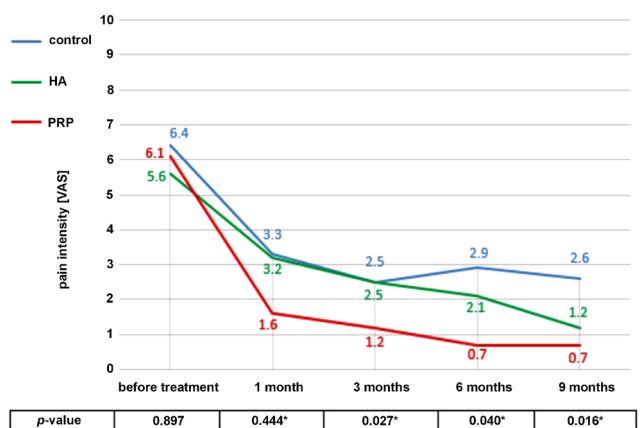


Fig. 3. Mean of pain intensity at the time of the study

\* statistically significant.

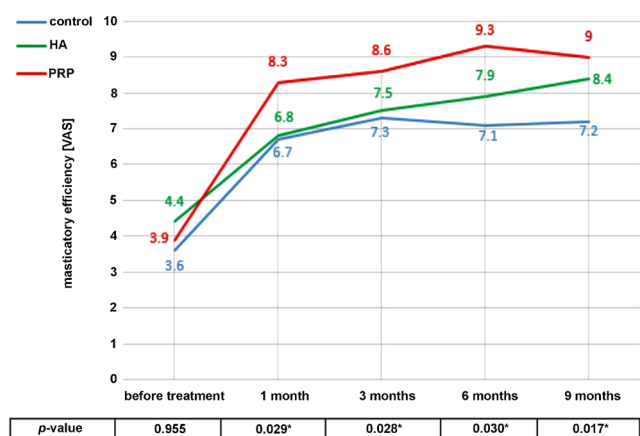


Fig. 4. Mean of masticatory efficiency at the time of the study

\* statistically significant.

The increase in MMO in the PRP and HA groups was significantly greater than that in the control group ( $p < 0.05$ ), whereas no significant difference was found between the PRP and HA group ( $p = 0.970$ ) (Table 3).

The pain intensity and masticatory efficiency results were significantly better in the PRP group than in the HA group or the control group ( $p < 0.05$ ); at the same time, no significant differences were noted between the HA group and the control group ( $p = 0.700$  and  $p = 0.560$ , respectively) (Table 3).

Overall, within the competitive framework, there has been improvement and consistency in the outcomes of the 3 techniques during the 9 months of follow-up.

## Discussion

The substantial development of biochemical studies has drawn attention away from disk displacement theory<sup>20</sup> to focus instead on the role of increasing friction between the contiguous parts of the joint in the incidence and exacerbation of TMDs.<sup>5</sup>

In the past, various kinds of conservative treatment were suggested to deal with TMDs, and when they failed, surgical disk repair and repositioning was the only available choice.<sup>21</sup> However, there has been increased interest in arthrocentesis since improvement was observed in the clinical parameters of patients who had arthroscopy, even though their articular disks had not been operated on.<sup>9</sup> In order to improve the results of arthrocentesis, the HA injection at the end of lavage was suggested due to the role of HA in the joint stabilization and nutrition, so this treatment might be useful in healing the lubrication system.<sup>22</sup> The same is also true for PRP, which has recently been used as in orthobiologic adjuvant treatment.<sup>15</sup>

Thus, there was a need to clearly determine whether there was any benefit from injecting any drug after arthrocentesis or not, and which substance was the most effective.

In the present study, there were no statistical differences in age, sex or any of the baseline values of the outcome variables (Table 1). Consequently, the treatment technique used remained the main affecting variable. All treatment techniques resulted in significant clinical improvement in both VAS parameters (pain intensity and masticatory efficiency) and MMO. The mean differences for these values in the control group were  $-3.8$ ,  $3.6$  and  $9.3$  mm, respectively; in the HA group, they were  $-4.4$ ,  $4.0$  and  $13.8$  mm, respectively, and in the PRP group, they were  $-5.4$ ,  $5.1$  and  $15.9$  mm, respectively (Table 2). The improvement was gradual throughout the observation period. Two studies described minor adverse effects after the PRP application, such as pain during the injection, postoperative discomfort,<sup>15</sup> or temporary swelling and soreness over TMJ,<sup>23</sup> but in the present study, no adverse effects were recorded.

These results are consistent with the results of most previous studies. The positive outcomes might be explained by the direct effect of arthrocentesis, since washing out UJC eliminates inflammation mediators from the synovial fluid and causes a reduction in pain. Furthermore, the hydraulic distention during arthrocentesis increases

**Table 3.** Comparison of the mean differences of the studied variables between the study groups during the observation period

Variable	Group	Mean difference	SE	Absolute value	p-value
MMO [mm]	control	9.300	1.955	4.500	0.000*
	HA group	13.800			
	control	9.300	1.955	6.600	0.000*
	PRP group	15.900			
	HA group	13.800			
	PRP group	15.900	1.955	2.100	0.970
Pain intensity [VAS]	control	-3.800	0.997	0.600	0.700
	HA group	-4.400			
	control	-3.800	0.997	1.600	0.000*
	PRP group	-5.400			
	HA group	-4.400			
	PRP group	-5.400	0.997	1.000	0.000*
Masticatory efficiency [VAS]	control	3.600	0.997	0.400	0.560
	HA group	4.000			
	control	3.600	0.997	1.500	0.000*
	PRP group	5.100			
	HA group	4.000			
	PRP group	5.100	0.997	1.100	0.000*

SE – standard error; \* – statistically significant.

the mandibular mobility by removing the intra-articular adhesions, getting rid of the negative pressure within the joint between the disk and the fossa space (vacuum effect), and thus reducing the mechanical obstruction.

Two things made it difficult to compare the results of our research with those of other studies. Firstly, it is a new study, since no previous ones have dealt with these 3 techniques simultaneously. Secondly, there is a wide variety of arthrocentesis techniques being used, in addition to different target groups for these techniques, such as patients with osteoarthritis, disk displacement, etc. Therefore, we tried to approach this discussion with the studies that most closely matched our study.

There are some discrepancies in the literature regarding the addition of medication after arthrocentesis. Alpaslan and Alpaslan examined the efficacy of arthrocentesis with and without the injection of sodium hyaluronate (SH) in the treatment of TMJ internal derangements.<sup>24</sup> Although they found that both techniques improved the outcome parameters, arthrocentesis with the SH injection seemed to be superior to arthrocentesis alone.<sup>24</sup> Cömert Kiliç et al. conducted a randomized clinical trial on adult patients with temporomandibular joint osteoarthritis (TMJ-OA).<sup>25</sup> The patients were randomly treated with arthrocentesis alone (control group) or with initial arthrocentesis plus the PRP injection followed by 4 consecutive PRP injections (experimental group). Painless interincisal opening and lateral motion increased significantly only in the experimental group. Cömert Kiliç et al. suggested that arthrocentesis plus the PRP injection is superior to arthrocentesis alone.<sup>25</sup>

Lin et al. compared the efficacy of 2 approaches – arthrocentesis plus PRP and PRP alone – and concluded that arthrocentesis plus PRP demonstrated superior improvement in the jaw range of motion <6 mm and pain when chewing foods.<sup>26</sup>

Zotti et al. presented a narrative review on the effects of arthrocentesis with PRP and PRP injections in the management of TMDs and compared them to those of arthrocentesis alone or with HA. They found encouraging results in terms of the effectiveness of the PRP therapy.<sup>27</sup>

In the present study, the increased MMO in the HA group was significantly greater than in the control group; our results for this parameter were similar to those obtained by Alpaslan and Alpaslan.<sup>24</sup> This might be explained by the lubricating properties of HA, described in many studies by the term viscosupplementation – HA allows smoother movements within the joint with less friction, which results in improved mouth opening. This effect was not observed by Bergstrand et al., who compared arthrocentesis alone to arthrocentesis with the HA injection.<sup>28</sup> They did not find a statistically significant difference between those groups. However, the results of that study cannot be thoroughly evaluated, as one very important issue was omitted, namely, the lavage volume of the perfusate for arthrocentesis was not mentioned in the study.<sup>28</sup>

Additionally, we found a significant increase in MMO in the PRP group as compared to the control group – a result which is consistent with that of Cömert Kiliç et al.<sup>25</sup> This could be interpreted by the positive impact of growth factors, which restore the viscosity of the synovial fluid and lead to improvement in the jaw movement.

On the other hand, we found that although the MMO result in the PRP group was better than in the HA group, there was no significant difference between the MMO values. This resembles the results obtained by Cömert Kiliç and Güngörmüş in their later randomized clinical trial conducted on adult patients with TMJ-OA.<sup>17</sup> The patients were randomly divided into 2 groups: the PRP group patients underwent initial arthrocentesis plus the PRP injection followed by 4 consecutive PRP injections, whereas the HA group patients underwent 1 session of arthrocentesis plus the HA injection. No statistically significant differences were observed between the groups, so the researchers suggested that arthrocentesis plus PRP injections is not superior to arthrocentesis plus a single HA injection.<sup>17</sup> Contradictory results were presented by Hegab et al., who enrolled patients with TMJ-OA in their study.<sup>15</sup> One group received 3 injections of 1 mL of PRP, whereas the other received 3 injections of 1 mL of low-molecular-weight HA. The PRP group exhibited better outcomes than the HA group in terms of the recurrence of pain and joint sounds, and an increased interincisal distance.<sup>15</sup> This discrepancy may result from the different sample sizes — if our sample had been larger, we may have found a significant difference — and from the different arthrocentesis technique, since repeated PRP injections may be more effective than the single injection we applied, particularly because the target group in that study had degenerative joint disease.

The present study demonstrated that the pain intensity and masticatory efficiency scores among the PRP group were better than among the HA group and the control group. Only in this parameter did we find a consensus between our results and the findings of Hegab et al.<sup>15</sup>

There was no difference between the HA group and the control group in this respect; this is contrary to the results of Alpaslan and Alpaslan<sup>24</sup> and may be due to the different solutions applied in the 2 studies. We used Ringer's lactate solution, whereas Alpaslan and Alpaslan applied a saline solution. Shinjo et al. suggested that Ringer's lactate solution is more compatible with the articular tissues than isotonic saline<sup>29</sup>; in addition, we think that Ringer's lactate solution makes the synovial fluid more viscous, which facilitates arthrocentesis and increases its effectiveness. Therefore, arthrocentesis in our study may have been more effective.

Based on the abovementioned results, we think that arthrocentesis plus PRP yields better outcomes in patients with arthralgia and dysfunction as the major complaint. When limited mouth opening is the primary symptom, there is no preference between PRP and HA as an additive after arthrocentesis. This agrees to a large extent with the results reported by Fernández-Ferro et al.<sup>30</sup>

Finally, it should be noted that the present study has some limitations. Firstly, our sample size was too small to achieve definitive conclusions. Secondly, our study included subjective estimations and observational compo-

nents. Thirdly, our study was not designed as a double-blind study, since the operator cannot be blinded to the material injected into the joint after arthrocentesis.

With the above limitations in mind, the present study has tried to shed some light on how to deal with TMDs, being one of the most difficult problems that oral and maxillofacial surgeons may encounter.


## Conclusions

There is a preference for techniques including the injection of some agent, regardless of the agent used. Arthrocentesis plus PRP seemed to be superior to arthrocentesis plus HA or arthrocentesis alone, especially in patients with intense pain along with a regression in masticatory efficiency. However, additional studies with larger sample sizes may be valuable in determining the optimal technique for the treatment of TMJ disk displacement.

### ORCID iDs

Mahmood Hasan Toameh  <https://orcid.org/0000-0002-3733-3517>

Issam Alkhouri  <https://orcid.org/0000-0003-1957-6651>

Mohammed Ammar Karman  <https://orcid.org/0000-0001-5745-2540>

### References

1. Lazarin Rd, Previdelli IT, Silva Rd, et al. Correlation of gender and age with magnetic resonance imaging findings in patients with arthrogenic temporomandibular disorders: A cross-sectional study. *Int J Oral Maxillofac Surg.* 2016;45(10):1222–1228.
2. Young AL. Internal derangements of the temporomandibular joint: A review of the anatomy, diagnosis, and management. *J Indian Prosthodont Soc.* 2015;15(1):2–7.
3. Yeung RW, Chow RL, Samman N, Chiu K. Short-term therapeutic outcome of intra-articular high molecular weight hyaluronic acid injection for nonreducing disc displacement of the temporomandibular joint. *Oral Surg Oral Med Oral Pathol Oral Radiol Endod.* 2006;102(4):453–461.
4. Iturriaga V, Bornhardt T, Manterola C, Brebi P. Effect of hyaluronic acid on the regulation of inflammatory mediators in osteoarthritis of the temporomandibular joint: A systematic review. *Int J Oral Maxillofac Surg.* 2017;46(5):590–595.
5. Nitzan DW. The process of lubrication impairment and its involvement in temporomandibular joint disc displacement: A theoretical concept. *J Oral Maxillofac Surg.* 2001;59(1):36–45.
6. Türp JC, Komine F, Hugger A. Efficacy of stabilization splints for the management of patients with masticatory muscle pain: A qualitative systematic review. *Clin Oral Investig.* 2004;8(4):179–195.
7. Nicolakis P, Erdogmus CB, Kopf A, Nicolakis M, Piehslinger E, Fialka-Moser V. Effectiveness of exercise therapy in patients with myofascial pain dysfunction syndrome. *J Oral Rehabil.* 2002;29(4):362–368.
8. Dionne RA. Pharmacologic treatments for temporomandibular disorders. *Oral Surg Oral Med Oral Pathol Oral Radiol Endod.* 1997;83(1):134–142.
9. Nitzan DW, Dolwick MF, Martinez GA. Temporomandibular joint arthrocentesis: A simplified treatment for severe, limited mouth opening. *J Oral Maxillofac Surg.* 1991;49(11):1163–1170.
10. Dimitroulis G, Dolwick MF, Martinez A. Temporomandibular joint arthrocentesis and lavage for the treatment of closed lock: A follow-up study. *Br J Maxillofac Surg.* 1995;33(1):23–27.
11. Salwowska NM, Bebenek KA, Żądło DA, Wcisło-Dziadecka DL. Physicochemical properties and application of hyaluronic acid: A systematic review. *J Cosmet Dermatol.* 2016;15(4):520–526.



12. Altman RD, Manjoo A, Fierlinger A, Niazi F, Nicholls M. The mechanism of action for hyaluronic acid treatment in the osteoarthritic knee: A systematic review. *BMC Musculoskelet Disord*. 2015;16:321.
13. Fortier LA, Barker JU, Strauss EJ, McCarrel TM, Cole BJ. The role of growth factors in cartilage repair. *Clin Orthop Relat Res*. 2011;469(10):2706–2715.
14. Anitua E, Sánchez M, Nurden AT, et al. Platelet-released growth factors enhance the secretion of hyaluronic acid and induce hepatocyte growth factor production by synovial fibroblasts from arthritic patients. *Rheumatology (Oxford)*. 2007;46(12):1769–1772.
15. Hegab AF, Ali HE, Elmasry M, Khallaf MG. Platelet-rich plasma injection as an effective treatment for temporomandibular joint osteoarthritis. *J Oral Maxillofac Surg*. 2015;73(9):1706–1713.
16. Schiffman E, Ohrbach R, Truelove E, et al.; International RDC/TMD Consortium Network, International Association for Dental Research, Orofacial Pain Special Interest Group, International Association for the Study of Pain. Diagnostic Criteria for Temporomandibular Disorders (DC/TMD) for clinical and research applications: Recommendations of the International RDC/TMD Consortium Network and Orofacial Pain Special Interest Group. *J Oral Facial Pain Headache*. 2014;28(1):6–27.
17. Cömert Kiliç S, Güngörmüş M. Is arthrocentesis plus platelet-rich plasma superior to arthrocentesis plus hyaluronic acid for the treatment of temporomandibular joint osteoarthritis: A randomized clinical trial. *Int J Oral Maxillofac Surg*. 2016;45(12):1538–1544.
18. McCain JP, de la Rua H, LeBlanc WG. Puncture technique and portals of entry for diagnostic and operative arthroscopy of the temporomandibular joint. *Arthroscopy*. 1991;7(2):221–232.
19. Tozoglu S, Al-Belasy FA, Dolwick MF. A review of techniques of lysis and lavage of the TMJ. *Br J Oral Maxillofac Surg*. 2011;49(4):302–309.
20. Stegenga B, de Bont LG, Boering G, van Willigen JD. Tissue responses to degenerative changes in the temporomandibular joint: A review. *J Oral Maxillofac Surg*. 1991;49(10):1079–1088.
21. Poliotis C, Stoelinga PJW, Gerritsen GW, Heyboer A. Long-term results of surgical intervention on the temporomandibular joint. *Cranio*. 1989;7(4):319–330.
22. Nitzan DW, Kreiner B, Zeltser B. TMJ lubrication system: Its effect on the joint function, dysfunction, and treatment approach. *Compend Contin Educ Dent*. 2004;25(6):437–438.
23. Hanci M, Karamese M, Tosun Z, Aktan TM, Duman S, Savaci N. Intra-articular platelet-rich plasma injection for the treatment of temporomandibular disorders and a comparison with arthrocentesis. *J Craniomaxillofac Surg*. 2015;43(1):162–166.
24. Alpaslan GH, Alpaslan C. Efficacy of temporomandibular joint arthrocentesis with and without injection of sodium hyaluronate in treatment of internal derangements. *J Oral Maxillofac Surg*. 2001;59(6):613–619.
25. Cömert Kiliç S, Güngörmüş M, Sümbüllü MA. Is arthrocentesis plus platelet-rich plasma superior to arthrocentesis alone in the treatment of temporomandibular joint osteoarthritis? A randomized clinical trial. *J Oral Maxillofac Surg*. 2015;73(8):1473–1483.
26. Lin SL, Tsai CC, Wu SL, Ko SY, Chiang WF, Yang JW. Effect of arthrocentesis plus platelet-rich plasma and platelet-rich plasma alone in the treatment of temporomandibular joint osteoarthritis: A retrospective matched cohort study (A STROBE-compliant article). *Medicine (Baltimore)*. 2018;97(16):e0477.
27. Zotti F, Albanese M, Rodella LF, Nocini PF. Platelet-rich plasma in treatment of temporomandibular joint dysfunctions: Narrative review. *Int J Mol Sci*. 2019;20(2):277.
28. Bergstrand S, Ingstad HK, Møystad A, Bjørnland T. Long-term effectiveness of arthrocentesis with and without hyaluronic acid injection for treatment of temporomandibular joint osteoarthritis. *J Oral Sci*. 2019;61(1):82–88.
29. Shinjo H, Nakata K, Shino K, et al. Effect of irrigation solutions for arthroscopic surgery on intraarticular tissue: Comparison in human meniscus-derived primary cell culture between lactate Ringer's solution and saline solution. *J Orthop Res*. 2002;20(6):1305–1310.
30. Fernández-Ferro M, Fernández-Sanromán J, Blanco-Carrión A, et al. Comparison of intra-articular injection of plasma rich in growth factors versus hyaluronic acid following arthroscopy in the treatment of temporomandibular dysfunction: A randomised prospective study. *J Craniomaxillofac Surg*. 2017;45(4):449–454.

# Evaluation of the fracture strength of porcelain sectional veneers made from different sintered feldspathic porcelains: An in vitro study

## Ocena wytrzymałości na złamanie częściowych licówek porcelanowych otrzymanych z różnych spiekanych ceramik skaleniovych – badanie in vitro

Rami Shurbaji Mozayek<sup>1,A–F</sup>, Manar Ali Alkhalil<sup>1,A–F</sup>, Mirza Allaf<sup>1,A,E,F</sup>, Suleiman Dayoub<sup>2,A,E,F</sup>

<sup>1</sup> Department of Fixed Prosthodontics, Faculty of Dentistry, Damascus University, Syria

<sup>2</sup> Department of Periodontology, Faculty of Dentistry, Damascus University, Syria

A – research concept and design; B – collection and/or assembly of data; C – data analysis and interpretation; D – writing the article; E – critical revision of the article; F – final approval of the article

Dental and Medical Problems, ISSN 1644-387X (print), ISSN 2300-9020 (online)

*Dent Med Probl.* 2019;56(3):273–278

### Address for correspondence

Manar Ali Alkhalil

E-mail: manarkhl@hotmail.com

### Funding sources

None declared

### Conflict of interest

None declared

Received on December 26, 2018

Reviewed on February 28, 2019

Accepted on April 23, 2019

Published online on September 30, 2019

### Cite as

Shurbaji Mozayek R, Ali Alkhalil M, Allaf M, Dayoub M. Evaluation of the fracture strength of porcelain sectional veneers made from different sintered feldspathic porcelains: An in vitro study. *Dent Med Probl.* 2019;56(3):273–278. doi:10.17219/dmp/108852

### DOI

10.17219/dmp/108852

### Copyright

© 2019 by Wrocław Medical University

This is an article distributed under the terms of the

Creative Commons Attribution 3.0 Unported License (CC BY 3.0)

(<https://creativecommons.org/licenses/by/3.0/>)

## Abstract

**Background.** Porcelain sectional veneers with no preparation (no-prep) are an ultra-conservative choice for the esthetic treatment of the anterior teeth. They can be made from a sintered feldspathic porcelain, which gives a great appearance with small thickness, but there are still concerns about the fracture strength of this material.

**Objectives.** The aim of this study was to evaluate the fracture strength of porcelain sectional veneers made from 2 different sintered feldspathic porcelains.

**Material and methods.** Twenty recently extracted human incisors were randomly divided into 2 groups according to the porcelain material ( $n = 10$ ). The 1<sup>st</sup> group was applied the IPS Style<sup>®</sup> Ceram feldspathic porcelain and the 2<sup>nd</sup> group – GC Initial<sup>™</sup> MC. The porcelain sectional veneers were fabricated following the manufacturers' instructions. After the veneers bonded with resin cement (Variolink<sup>®</sup> N), the fracture strength was measured using a universal testing machine (Instron<sup>®</sup>1195) at 1 mm/min until failure occurred. Failure modes were determined under a stereomicroscope.

**Results.** The mean fracture strength for group IPS Style Ceram was higher than that for group GC Initial MC (182.7 N and 155.7 N, respectively). The lowest value was observed in group IPS Style Ceram (78 N) and the highest value – also in the group IPS Style Ceram (294 N). Student's *t*-test demonstrated no statistically significant differences between the 2 groups ( $p > 0.05$ ).

**Conclusions.** There was no difference in the fracture strength of the porcelain sectional veneers for the 2 types of sintered porcelain used in this study. Cohesive failure within the porcelain sectional veneer was the most common mode of failure.

**Key words:** fracture strength, porcelain sectional veneers, no-prep, feldspathic porcelain, ultra-thin veneers

**Słowa kluczowe:** wytrzymałość na złamanie, częściowe licówki porcelanowe, no-prep, ceramika skaleniovowa, ultracienkie licówki

## Introduction

Demands for esthetic and conservative treatment are increasing nowadays, especially with regard to the anterior region for malpositioned teeth and diastema.<sup>1,2</sup> Progress in adhesive technologies has led to a variety of more conservative restoration techniques. For example, ultra-thin veneers with minimal or no preparation (no-prep),<sup>3-7</sup> and recently porcelain sectional veneers, which are ultra-thin pieces that partially cover the teeth, and can be etched and adhered to the enamel to restore only the defected area while being ultra-conservative. These restorations can have biologically healthy and optically beautiful margins and emergence profiles if properly selected and managed to avoid overcontouring.<sup>8</sup> Sectional veneers were an acceptable solution for patients, with high survival rates in several case reports.<sup>9-11</sup>

Composite resin can be used to restore the defects in the anterior teeth. It has the advantage of direct placement at 1 appointment. It is also easily modified and repaired as well as inexpensive. However, low wear resistance and durability, discoloration, surface staining, and polymerization shrinkage are still the disadvantages of this material.<sup>12,13</sup>

Dental porcelain is usually characterized by color stability, clinical longevity, esthetic appearance, and compatibility with periodontal tissues<sup>14</sup>; these characteristics make porcelain a good choice for such treatment. In addition, it can be thinned to less than 0.3 mm, which distinguishes sectional veneers from traditional 0.3–1-millimeter-thick laminate veneers.<sup>3,15,16</sup>

Porcelain sectional veneers can be made from hot-pressed ceramic, but it does not yield the same esthetic results as build-up feldspathic porcelain, which closely resembles the natural tooth, and due to the presence of fluoroapatite crystals, this kind of porcelain gains a polychromatic appearance and high translucency.<sup>14,17,18</sup> Many in-vivo studies revealed good survival rates for veneers made from feldspathic porcelain.<sup>18-20</sup> The main limitation of sintered feldspathic porcelain is its fragile nature, especially in the case of low thicknesses as in sectional veneers,<sup>14</sup> so there are still concerns about the fracture strength of this material and its ability to be used for fabricating sectional veneers. In addition, in vitro studies on sectional veneers are not available, so the aim of this study was to evaluate the fracture strength of porcelain sectional veneers made from 2 different sintered feldspathic porcelains.

## Material and methods

Twenty recently extracted caries-free human incisors of similar dimensions were randomly selected for this study, and adhering soft tissues and calculus deposits were removed with a hand scaler. The teeth were stored

in 0.5% chloramine-T solution for a week and then in distilled water. Chloramine-T solution was chosen to store the extracted teeth according to the ISO recommendations.<sup>21</sup>

The teeth were divided into 2 groups (n = 10) according to the type of feldspathic porcelain used: the 1<sup>st</sup> group was applied sectional veneers made from the IPS Style<sup>®</sup> Ceram (Ivoclar Vivadent, Schaan, Liechtenstein) porcelain and the 2<sup>nd</sup> group – the GC Initial<sup>™</sup> MC (GC Nordic AB, Stockholm, Sweden) porcelain. Then, the teeth were embedded perpendicularly in self-cure acrylic resin blocks (18 mm × 18 mm × 18 mm), 2 mm below the cemento-enamel junction, using a dental surveyor so that during the loading test, the load could be applied parallel to the long axis of the tooth.

## Fabrication of the porcelain sectional veneers

No preparation was made for the teeth. Customized trays were used for making the impressions with a polyvinyl siloxane impression material (Elite<sup>®</sup> HD+; Zhermack SpA, Badia Polesine, Italy).

The veneers were fabricated from a sintered feldspathic porcelain material using the conventional refractory die technique according to the manufacturer's recommendations. The sectional veneers extended gingivally to the cemento-enamel junction, buccally to the bucco-proximal line angle and lingually to the lingual-proximal line angle; the incisal edge was extended by 1 mm with a sectional veneer following the same natural incisal thickness of the tooth without covering it. The bucco-lingual thickness of the tooth was measured before and after bonding the sectional veneers. The difference between the 2 measurements resembled the sectional veneer thickness and was limited to 0.1 mm.

The impressions were cast in an investment material (G-Cera<sup>®</sup> Orbit Vest; GC America Inc., Alsip, USA) using a dental vibrator. After an hour, the cast dies were carefully separated from the impressions. A degassing process was performed for the dies in 2 stages; firstly, the temperature was gradually raised to 700°C over 1 h in a heating furnace, secondly, the dies were placed in a porcelain furnace with the temperature being raised from 700°C to 1,050°C and maintained for 5 min at this temperature. A thin layer of connector paste was applied on the dies using a brush. Then, the dies were placed again in a porcelain furnace, heated up to 950°C, removed, and cooled to room temperature. The porcelain sectional veneers were built up on refractory dies using the conventional technique (powder/liquid), shade A1 for GC Initial MC and A3.5 for IPS Style Ceram. Then, the veneers were fired in a furnace according to the manufacturers' instructions. The veneers were gently sandblasted to remove the residual investment material using aluminous oxide 50 µm from a distance of 10 mm at a pressure of 1 bar.

## Bonding of the porcelain sectional veneers

The enamel was etched for 30 s using a 37% phosphoric acid etching gel (Total Etch®; Ivoclar Vivadent). Then, the tooth surface was rinsed with water for 20 s and gently air-dried. One layer of a bonding agent (Tetric® N-Bond Universal; Ivoclar Vivadent) was applied and light-cured for 20 s. The inner surface of the sectional veneer was etched with 5% hydrofluoric acid (IPS® Ceramic Etching Gel; Ivoclar Vivadent) for 60 s, rinsed thoroughly and air-dried. One thin layer of a silane coupling agent (Monobond® S; Ivoclar Vivadent) was applied for 60 s.

The porcelain sectional veneers were bonded using light-cure translucent resin cement (Variolink® N; Ivoclar Vivadent). The veneers were positioned on the teeth, held in place with finger pressure and light-cured with LED curing light (Guilin Woodpecker Medical Instrument Co., Ltd., Guilin, China) for 5 s at light intensity of 800 mW/cm<sup>2</sup>. The excess cement was removed with blade 12. Then, the veneer was light-cured from the lingual, facial and incisal sides for 40 s. The margins were finished with a diamond bur and rubber disks. Figure 1 shows the final sectional veneers after bonding. The specimens were stored in distilled water at room temperature for 24 h before being subjected to mechanical tests.

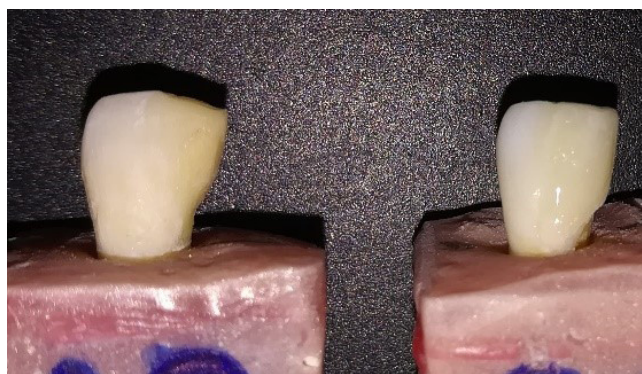


Fig. 1. Final sectional veneers

On the left – IPS Style Ceram porcelain; on the right – GC Initial MC porcelain.

## Fracture strength test

A fracture strength test was performed by applying progressive load to the specimen until fracture occurred. A universal testing machine (Instron® 1195; Instron, High Wycombe, UK) was used (Fig. 2). The load was applied at a crosshead with a speed of 1 mm/min at the incisal edge of the porcelain sectional veneer parallel to the long axis of the tooth. The maximum force that produced failure was recorded in newtons. The failure mode was categorized as cohesive (failure within the porcelain sectional

veneers or teeth), adhesive (failure between the porcelain sectional veneer and the tooth) or mixed. The failure mode was examined under a stereomicroscope at  $\times 20$  magnification.



Fig. 2. Load applied at the incisal edge using the Instron testing machine

## Statistical analysis

The data was analyzed statistically using SPSS Statistics for Windows v. 17 (SPSS Inc., Chicago, USA). Student's *t*-test was used to compare the mean values of fracture strength between the 2 groups at a significance level of 95% ( $p < 0.05$ ).

## Results

Figure 3 and Table 1 show the mean values of fracture load and standard deviations (*SD*) for each group. Although the IPS Style Ceram group presented higher fracture strength, Student's *t*-test showed no significant differences between the sectional veneers made from GC Initial MC and IPS Style Ceram porcelain. The use of different sintered feldspathic materials did not affect the fracture strength at the significance level ( $p > 0.05$ ) (Table 2).

Figure 4 shows the failure modes for the 2 groups. Cohesive failure of the porcelain sectional veneer occurred in most specimens, whereas a tooth fractured in only 3 specimens. There was no adhesive failure.

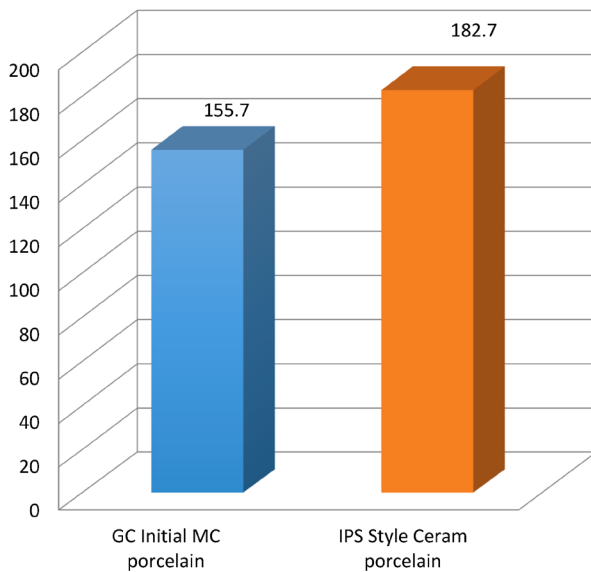


Fig. 3. Means of fracture strength [N] for the materials tested

Table 1. Descriptive data for the fracture strength values [N] for the test groups

Group	SD	SEM	Minimum	Maximum
IPS Style Ceram (n = 10)	76.4	28.9	78	294
GC Initial MC (n = 10)	86.7	28.9	78.4	284.2

SD – standard deviation; SEM – standard error of the mean.

Table 2. Results of paired comparisons using Student's *t*-test

Statistical data	Value
<i>t</i>	0.6499
<i>df</i>	18
difference between the means	27
SE of the difference	41.5
<i>p</i> -value	0.5263*

*df* – degrees of freedom; *SE* – standard error;  
\* statistically non-significant ( $p > 0.05$ ).

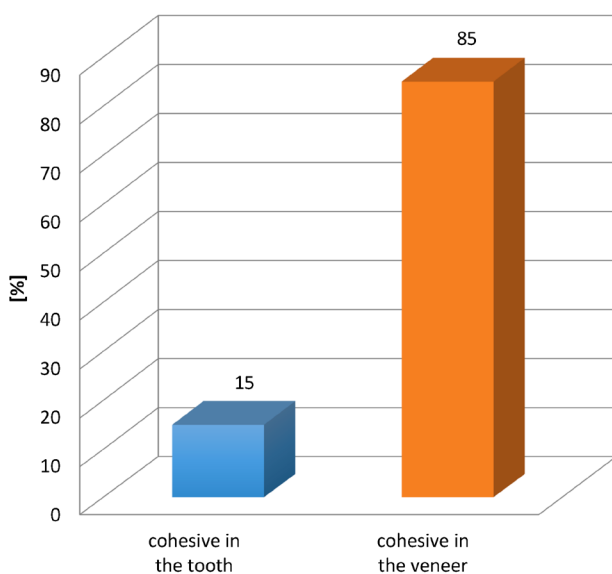


Fig. 4. Incidence of fracture modes

## Discussion

The present study investigated the difference in fracture strength of 2 types of sintered feldspathic porcelain used to fabricate porcelain sectional veneers. This type of restorations is an esthetic and conservative option that requires no tooth preparation and is ultra-thin, which makes the bonding remain on the enamel, consequently ensuring the best adhesion possible. Sectional veneers have many advantages, such as the needlessness of provisional restorations, no post-operative sensitivity and a simplified impression technique. The advantages of using sintered feldspathic porcelain include esthetics, low laboratory cost and excellent mechanical retention after bonding with resin cement.

Fracture is an important clinical problem. The most frequent kinds of failure associated with feldspathic porcelain veneers are fracture, debonding and microleakage,<sup>22</sup> so the fracture strength of these materials must be taken into consideration.

In the present study, natural anterior teeth were used instead of acrylic or metallic dies, because they differ in elasticity and strength compared to the teeth. Besides, the study aimed to mimic the clinical situation as much as possible with respect to the adhesive bonding protocol.

In the present investigation, the teeth were embedded in acrylic resin blocks to facilitate testing procedures, such as preparing the impressions and bonding, and the specimens were later put into a testing machine. All specimens were embedded in acrylic resin without a simulated periodontal ligament that is usually used as a shock-absorbing layer. Currently, there is no consensus in the dental literature whether or not to use it; it may be of no importance in the case of progressive load like in this study.<sup>23–25</sup> This research was conducted with regard to exact laboratory and clinical procedures, such as preparing impressions, casting with investment, sandblasting, and bonding to the teeth with resin cement, which make the results more clinically relevant.

Different load direction and placement were observed in the literature. In some studies, the teeth were loaded at the palatal surface,<sup>23,26,27</sup> whereas in most other studies, the force was applied at the incisal edge parallel to the long axis of the tooth.<sup>24,28–33</sup> Loading the force at the palatal surface would lead to the failure of the tooth structure itself. This angle might also cause the Instron crosshead to slide along the palatal surface of the tooth. Therefore, in the present study the load was applied at the incisal edge and according to the longitudinal axis of the specimens.

The sample size involved 10 teeth in each group like in many previous studies.<sup>23,27,29,31,32</sup> When dividing *SD* by the mean (which is called the coefficient of variation), the result is  $<1$ . Such a large deviation can be considered low variance and statistically correct.

There were no statistically significant differences in the fracture strength of the porcelain sectional veneers between the 2 studied materials.

No previous *in vitro* or *in vivo* studies on sectional veneers were found in the literature except for a few case reports. However, 1 study found that minimally invasive tooth preparation (0.2 mm) allowed higher fracture resistance in the case of restorations with lithium disilicate ceramic veneers.<sup>34</sup> Another study compared the fracture strength and other properties of the veneers fabricated using different techniques and materials, and concluded that there were fewer marginal discrepancies with feldspathic porcelain and that the fracture strength decreased when more covering to the dental tissue was applied.<sup>24</sup> Yet another study showed that more preparation for the dental tissue could be associated with a decreased shear strength of lithium disilicate laminate veneers.<sup>35</sup>

The results of this study showed that the mean fracture strength of the IPS Style Ceram porcelain was 182.7 N and in the case of the GC Initial MC porcelain, it was 155.7 N. This result is close to that obtained by Alghazzawi et al., who found that the mean fracture strength was 161 N,<sup>36</sup> whereas Zarone et al. found that it was 220 N.<sup>37</sup> In the study conducted by Lin et al., laminate veneers fractured at 450 N.<sup>24</sup> They investigated the fracture load of feldspathic porcelain veneers using standardized composite resin dies, which may have affected their results.<sup>24</sup> However, Turkaslan et al. reported higher results (800 N),<sup>31</sup>

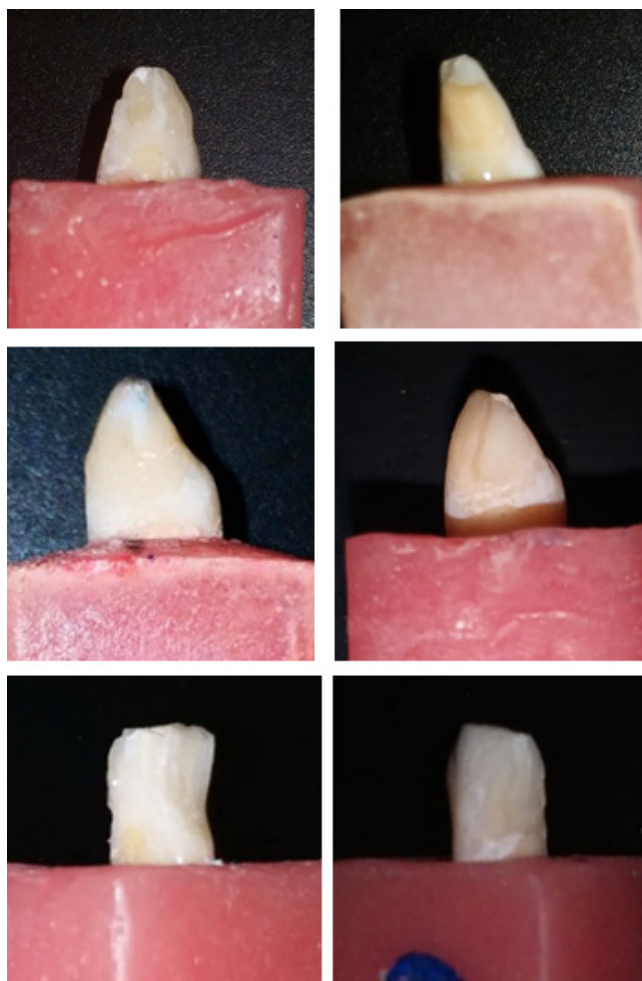

Fig. 5. Different modes for fractured sectional veneers

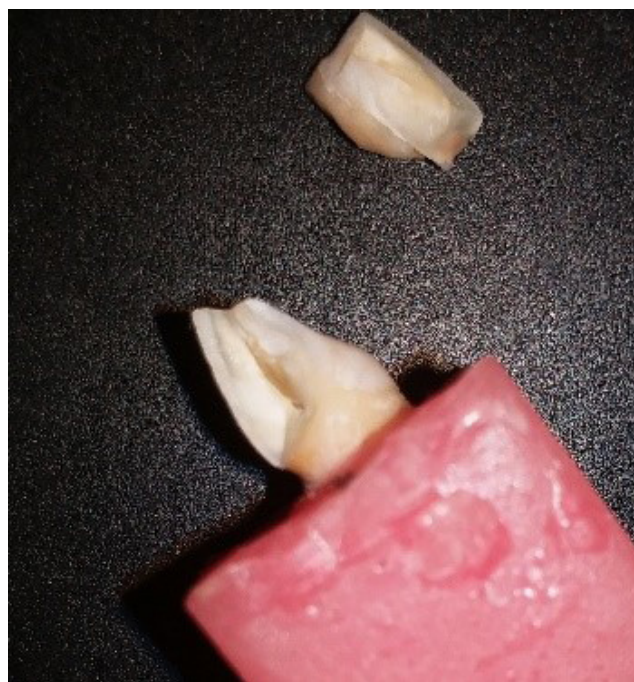

Fig. 6. Cohesive failure of the tooth

which might be due to the use of full veneers as well as the differences in the thickness of porcelain and the fabrication technique (computer-aided design and computer-aided manufacturing (CAD CAM)).

This study showed no adhesive failure; the main failure mode was the cohesive failure of the porcelain veneers (Fig. 5) followed by the tooth fracture. This finding may imply that the bond strength was high enough to withstand loading and eventually failure would occur cohesively within the veneer or the tooth itself. This result coincides with previous studies.<sup>24,32,36,38–40</sup> However, different failure modes were reported by other researchers,<sup>29,30,37</sup> which could be explained by the differences in the load direction, type of ceramic, adhesive cement, and bonding procedure. Three specimens showed cohesive failure in the tooth structure (Fig. 6). A possible reason for this could be that the load was high enough to exceed the proportional limit of the tooth,<sup>33–39</sup> especially in the teeth with thin roots. In general, extracted human teeth vary in quality and standardizing this factor is difficult.



The average masticatory force reaches 130 N in the anterior teeth and the mean value of fracture strength in the present study was higher than the average masticatory force.<sup>41</sup>

Some limitations of this study need to be mentioned. Extracted human teeth greatly vary in size, shape and quality, which may influence the results, so it is better to use a larger sample size. Further studies involving other types of ceramic should be performed. This study was conducted under dry and static conditions, therefore not exactly mimicking the wet and cyclic nature of the oral environment. Apart from that, porcelain in the oral environment is subjected to thermal and chemical factors, which is why *in vivo* studies are needed.

## Conclusions

Within the limitations of this in vitro study, it can be concluded that sintered feldspathic porcelain used for sectional veneers did not affect the fracture strength. The fracture of the porcelain sectional veneer was the most common failure mode.

### ORCID iDs

Rami Shurbaji Mozayek  <https://orcid.org/0000-0002-8399-4025>  
 Manar Ali Alkhalil  <https://orcid.org/0000-0001-6176-1792>  
 Mirza Allaf  <https://orcid.org/0000-0003-1974-1995>  
 Suleiman Dayoub  <https://orcid.org/0000-0003-0671-9473>

### References

- Kamble VD, Parkhedkar RD. Esthetic rehabilitation of discolored anterior teeth with porcelain veneers. *Contemp Clin Dent*. 2013;4(1):124–126.
- Peumans M, Van Meerbeek B, Lambrechts P, Vanherle G. Porcelain veneers: A review of the literature. *J Dent*. 2000;28(3):163–177.
- Akan E, Bagis B. Midline diastema closure with partial laminate veneers: A case report. *Balk J Dent Med*. 2016;20(1):59–62.
- Savi A, Crescini A, Tinti C, Manfredi M. Ultra-thin veneers without tooth preparation in extensive oligodontia. *Int J Periodontics Restorative Dent*. 2015;35(6):e97–e103.
- Nosti J. “Thin is in” the art of minimal & no prep veneer. *J N J Dent Assoc*. 2009;80(4):30–31.
- Agustín-Panadero R, Ausina-Escrihuela D, Fernández-Estevan L, Román-Rodríguez JL, Faus-López J, Solá-Ruiz MF. Dental-gingival remodeling with BOPT no-prep veneers. *J Clin Exp Dent*. 2017;9(12):e1496–e1500.
- Magne P, Hanna J, Magne M. The case for moderate ‘guided prep’ indirect porcelain veneers in the anterior dentition. The pendulum of porcelain veneer preparations: From almost no-prep to over-prep to no-prep. *Eur J Esthet Dent*. 2013;8(3):376–388.
- D’Arcangelo C, Vadini M, D’Amaro M, Chiavaroli Z, De Angelis F. Protocol for a new concept of no prep ultrathin ceramic veneers. *J Esthet Restorat Dent*. 2018;30(3):173–179.
- Okida RC, Filho AJV, Barão VAR, dos Santos DM, Goiato MC. The use of fragments of thin veneers as a restorative therapy for anterior teeth disharmony: A case report with 3 years of follow-up. *J Contemp Dent Pract*. 2012;13(3):416–420.
- Signore A, Kaitsas V, Tonoli A, Angiero F, Silvestrini-Biavati A, Benedicenti S. Sectional porcelain veneers for a maxillary midline diastema closure: A case report. *Quintessence Int*. 2013;44(3):201–206.
- Horvath S, Schulz CP. Minimally invasive restoration of a maxillary central incisor with a partial veneer. *Eur J Esthet Dent*. 2012;7(1):6–16.
- Koczarski M. Smile makeover utilizing direct composite resin veneers. *Dent Today*. 2008;27(12):76,78–79.
- Vadini M, D’Amaro M, De Angelis F, Falco A, D’Arcangelo C. No-prep rehabilitation of fractured maxillary incisors with partial veneers. *J Esthet Restorat Dent*. 2016;28(6):351–358.
- Pini NP, Aguiar FHB, Lima DANL, Lovadino JR, Terada RSS, Pascotto RC. Advances in dental veneers: Materials, applications, and techniques. *Clin Cosmet Investig Dent*. 2012;4:9–16.
- Radz GM. Minimum thickness anterior porcelain restorations. *Dent Clin North Am*. 2011;55(2):353–370.
- Sari T, Ural C, Yüzbasioğlu E, Duran I, Cengiz S, Kavut I. Color match of a feldspathic ceramic CAD-CAM material for ultrathin laminate veneers as a function of substrate shade, restoration color, and thickness. *J Prosthodont*. 2018;119(3):455–460.
- McLaren EA, LeSage B. Feldspathic veneers: What are their indications? *Compend Contin Educ Dent*. 2011;32(3):44–49.
- Zarone F, Leone R, Di Mauro MI, Ferrari M, Sorrentino R. No-preparation ceramic veneers: A systematic review. *J Osseointegrat*. 2018;10(1):17–22.
- Federizzi L, Gomes ÉA, Báratro SS, Baratto-Filho F, Bacchi A, Spazzini AO. Use of feldspathic porcelain veneers to improve smile harmony: A 3-year follow-up report. *Braz Dent J*. 2016;27(6):767–774.
- Layton DM, Walton TR. The up to 21-year clinical outcome and survival of feldspathic porcelain veneers: Accounting for clustering. *Int J Prosthodont*. 2012;25(6):604–612.
- International Organization for Standardization Technical Specification Report (ISO/TS 11405:2003).
- Morimoto S, Albanesi RB, Sesma N, Agra CM, Braga MM. Main clinical outcomes of feldspathic porcelain and glass-ceramic laminate veneers: A systematic review and meta-analysis of survival and complication rates. *Int J Prosthodont*. 2016;29(1):38–49.
- Castelnuovo J, Tjan AH, Phillips K, Nicholls JI, Kois JC. Fracture load and mode of failure of ceramic veneers with different preparations. *J Prosthet Dent*. 2000;83(2):171–180.
- Lin TM, Liu PR, Ramp LC, Essig ME, Givan DA, Pan YH. Fracture resistance and marginal discrepancy of porcelain laminate veneers influenced by preparation design and restorative material in vitro. *J Dent*. 2012;40(3):202–209.
- Gresnigt MM, Özcan M, Kalk W, Galhano G. Effect of static and cyclic loading on ceramic laminate veneers adhered to teeth with and without aged composite restorations. *J Adhes Dent*. 2011;13(6):569–577.
- Garoushi SK, Lassila LV, Vallittu PK. Fatigue strength of fragmented incisal edges restored with a fiber reinforced restorative material. *J Contemp Dent Pract*. 2007;8(2):9–16.
- Sarabi N, Ghavamnasiri M, Forooghbaksh A. The influence of adhesive luting systems on bond strength and failure mode of an indirect micro ceramic resin-based composite veneer. *J Contemp Dent Pract*. 2009;10(1):33–40.
- Hahn P, Gustav M, Hellwig E. An in vitro assessment of the strength of porcelain veneers dependent on tooth preparation. *J Oral Rehabil*. 2000;27(12):1024–1029.
- Gresnigt MM, Cune MS, de Roos JG, Özcan M. Effect of immediate and delayed dentin sealing on the fracture strength, failure type and Weibull characteristics of lithium disilicate laminate veneers. *Dent Mat*. 2016;32(4):e73–e81.
- Sadighpour L, Geramipannah F, Rasaei V, Kharazi Fard MJ. Fracture resistance of ceramic laminate veneers bonded to teeth with class V composite fillings after cyclic loading. *Int J Dent*. 2018;2018:1456745.
- Turkaslan S, Bagis B, Akan E, Mutluay M, Vallittu PK. Fracture strengths of chair-side-generated veneers cemented with glass fibers. *Niger J Clin Pract*. 2015;18(2):240–246.
- Gresnigt MMM, Özcan M, Carvalho M, Lazari P, Cune MS, Razavi P. Effect of luting agent on the load to failure and accelerated-fatigue resistance of lithium disilicate laminate veneers. *Dent Mat*. 2017;33(12):1392–1401.
- Stappert CF, Ozden U, Gerds T, Strub JR. Longevity and failure load of ceramic veneers with different preparation designs after exposure to masticatory simulation. *J Prosthodont*. 2005;94(2):132–139.
- Linhares LA, Pottmaier LF, Lopes GC. Fracture resistance of veneers in premolars. *Eur J Dent*. 2018;12(2):191–198.
- Alavi AA, Behrooz Z, Eghbal FN. The shear bond strength of porcelain laminate to prepared and unprepared anterior teeth. *J Dent (Shiraz)*. 2017;18(1):50–55.
- Alghazzawi TF, Lemons J, Liu PR, Essig ME, Janowski GM. The failure load of CAD/CAM generated zirconia and glass-ceramic laminate veneers with different preparation designs. *J Prosthet Dent*. 2012;108(6):386–393.
- Zarone F, Epifania E, Leone G, Sorrentino R, Ferrari M. Dynamometric assessment of the mechanical resistance of porcelain veneers related to tooth preparation: A comparison between two techniques. *J Prosthet Dent*. 2006;95(5):354–363.
- Gresnigt MMM, Özcan M. Fracture strength of direct versus indirect laminates with and without fiber application at the cementation interface. *Dent Mat*. 2007;23(8):927–933.
- Schmidt KK, Chiayabutr Y, Phillips KM, Kois JC. Influence of preparation design and existing condition of tooth structure on load to failure of ceramic laminate veneers. *J Prosthet Dent*. 2011;105(6):374–382.
- Batalocco G, Lee H, Ercoli C, Feng C, Malmstrom H. Fracture resistance of composite resin restorations and porcelain veneers in relation to residual tooth structure in fractured incisors. *Dent Traumatol*. 2012;28(1):75–80.
- Kumagai H, Suzuki T, Hamada T, Sondang P, Fujitani M, Nikawa H. Occlusal force distribution on the dental arch during various levels of clenching. *J Oral Rehabil*. 1999;26(12):932–935.

# Evaluation of the effect of the inversion filter on enhancing the visibility of the mandibular incisive canal in comparison with the original images

## Ocena widoczności kanału przysiecznego żuchwy po zastosowaniu filtra inwersyjnego w odniesieniu do oryginalnego obrazowania radiologicznego

Farzaneh Ostovarrad<sup>1,A</sup>, Somayeh Nemati<sup>1,A</sup>, Abbas Shokri<sup>2,E</sup>, Elaheh Baghizadeh<sup>3,B</sup>, Zahra Yousefi<sup>1,D</sup>

<sup>1</sup> Department of Oral and Maxillofacial Radiology, Dental Sciences Research Center, School of Dentistry, Guilan University of Medical Sciences, Rasht, Iran

<sup>2</sup> Department of Oral and Maxillofacial Radiology, Dental Research Center, Faculty of Dentistry, Hamadan University of Medical Sciences, Iran

<sup>3</sup> Department of Oral and Maxillofacial Radiology, School of Dentistry, Guilan University of Medical Sciences, Rasht, Iran

A – research concept and design; B – collection and/or assembly of data; C – data analysis and interpretation; D – writing the article; E – critical revision of the article; F – final approval of the article

Dental and Medical Problems, ISSN 1644-387X (print), ISSN 2300-9020 (online)

*Dent Med Probl.* 2019;56(3):279–283

### Address for correspondence

Zahra Yousefi  
E-mail: zahra\_yousefi\_sh@yahoo.com

### Funding sources

None declared

### Conflict of interest

None declared

### Acknowledgements

The authors would like to thank Dr. Ehsan Kazemnezhad, Associate Professor of Biostatistics, from Guilan University of Medical Sciences, Rasht, Iran, for his statistical analysis.

Received on December 26, 2018

Reviewed on February 8, 2019

Accepted on April 17, 2019

Published online on September 30, 2019

### Cite as

Ostovarrad F, Nemati S, Shokri A, Baghizadeh E, Yousefi Z. Evaluation of the effect of the inversion filter on enhancing the visibility of the mandibular incisive canal in comparison with original images. *Dent Med Probl.* 2019;56(3):279–283. doi:10.17219/dmp/108596

### DOI

10.17219/dmp/108596

### Copyright

© 2019 by Wrocław Medical University

This is an article distributed under the terms of the Creative Commons Attribution 3.0 Unported License (CC BY 3.0) (<https://creativecommons.org/licenses/by/3.0/>)

## Abstract

**Background.** The mandibular incisive canal (MIC) is a neural canal containing one of the lower branches of the inferior alveolar nerve, called the mandibular incisive nerve, which can get damaged and cause complications during the removal of bone from the interforaminal region.

**Objectives.** The aim of this study was to determine the effect of the inversion filter (IF) on improving the visibility of MIC as compared to the original images.

**Material and methods.** In this retrospective, descriptive, analytical study, 343 samples of digital panoramic radiography were examined. The images were analyzed with and without IF. The frequency and confidence intervals (CIs) of identifying MIC were used to determine its visibility, both with IF and in the original images. Besides, the difference between the maximum and minimum diameters of the canal as well as the distance from MIC to the alveolar crest and to the mental foramen were examined. For statistical analysis, McNemar's test and the paired *t*-test were used, and the concordance was calculated using the kappa coefficient.

**Results.** No significant differences were found in the prevalence of the incisive canal, or in its unilateral or bilateral visibility between the original and filtered radiography in this study ( $p = 0.42$  and  $p = 0.67$ , respectively). The absolute values of the interval difference between MIC and the mental foramen, the maximum and minimum diameters of MIC, and the distance from MIC to the alveolar crest were statistically significant between the filtered and original radiography, although the difference was clinically unimportant.

**Conclusions.** The use of IF produced results similar to the original radiography; its application neither increased the clarity nor improved the visibility of the incisive canal.

**Key words:** mandible, software, digital dental radiography, mandibular nerve

**Słowa kluczowe:** żuchwa, oprogramowanie, cyfrowa radiografia stomatologiczna, nerw żuchwowy



## Introduction

The mandibular incisive canal (MIC) is a neural canal containing one of the lower branches of the inferior alveolar nerve, called the mandibular incisive nerve.<sup>1</sup> It was Olivier who first described it as an extension of the lower alveolar canal.<sup>acc.2</sup> The mandibular incisive canal, which supplies the nerves of the anterior teeth of the mandible,<sup>3</sup> sometimes extends to the midline, and in some cases, ends up between the canine region and the premolar region.<sup>4</sup> Various studies reported different frequencies for the observation of MIC.<sup>2,5-7</sup> In certain studies, MIC was detectable in only 15% of panoramic images, and only 1% of the images had good resolution, whereas in cone-beam computed tomography (CBCT), it was detectable in 93% of cases.<sup>5</sup>

Although CBCT is considered to be more accurate than panoramic imaging for observing anatomical structures in the oral cavity,<sup>8</sup> its radiation dosage and costs are higher than in the case of panoramic radiography,<sup>9-11</sup> so it would be very practical to develop a technique to improve the observation of MIC in panoramic radiography. Nowadays, digital filters are used to improve the quality of radiography and the inversion filter (IF) is one of them.<sup>12</sup> It reverses the grayscale of the image by exchanging low-density pixels (black) with high-density pixels (white), thus turning radio-opaque structures into radiolucent ones, and vice versa.<sup>13</sup> This filter improves the optical contrast of images and shows objects with better contours.<sup>14</sup>

Given that the mandibular anterior region is one of the less problematic zones in oral surgery, the results of some studies suggest that panoramic radiography is sufficient for this zone and that more advanced imaging techniques such as CBCT are unnecessary. On the other hand, damaging the mandibular incisive nerve may cause complications in the interforaminal area, although these are less frequent anyway.<sup>3</sup> Since panoramic radiography is related to a lower dosage and cost, the aim of this study was to investigate the visibility of MIC in panoramic radiography using IF in comparison with the original images in order to determine the effect of IF.

## Material and methods

In this retrospective, descriptive, analytical study, 343 digital panoramic radiography images were selected from the medical records of patients referred to a private oral-maxillofacial radiology clinic in Rasht, Iran (the study was approved by the Ethics Committee of Guilan University of Medical Sciences with Code of Ethics IR.GUMS.REC.1396.384).

The exclusion criteria used in the study were as follows: low-quality radiography, technical errors in the patients' head position, radiography with artifacts or of patients with fractures, surgery, pathological lesions, impacted or unerupted teeth in the interforaminal region, and, finally, edentulous patients.

All panoramic radiographs were prepared with the CRANEX<sup>®</sup> D digital device (SOREDEX, Tuusula, Finland) at 75–85 kVp, 10 mA and 11–17 s. All images were studied by 2 experienced oral-maxillofacial radiologists on a 22-inch LED monitor using the SCANORA<sup>®</sup> software v. 5.1.2 by SOREDEX.

Initially, the images were evaluated without any digital manipulations. Then, they were re-evaluated after 10 days, applying IF under similar conditions (Fig. 1). If either or both of the upper or lower edges of the canal were visible, they were considered visible; if neither of the edges were visible, they were considered invisible. In the case when both upper and lower edges were visible, the diameter of the canal as well as the distance from MIC to the mental foramen and to the alveolar crest were measured in millimeters (if MIC was in the region between the 2 mental foramina without any interruption, the diameter was examined in the middle of the canal region). The results were decided based on the agreement of both observers, and in the event of disagreement between the 2 observers, the radiograph was excluded from the study. In order to measure the intra-observation reliability, the test–retest reliability was assessed on 10 samples at the 2 stages, 10 days apart. The achieved reliability was >96% for all measurements.

The data was entered into the IBM SPSS Statistics for Widows software v. 21 (IBM Corp., Armonk, USA).

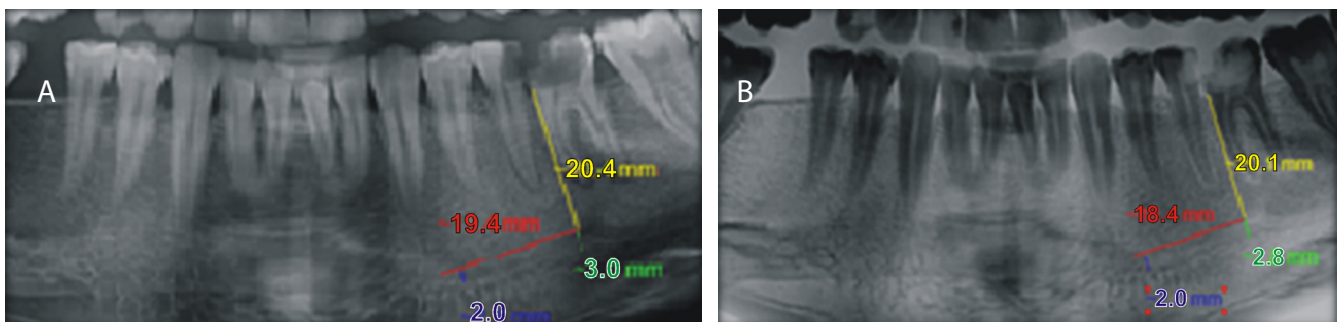


Fig. 1. Cropped panoramic images showing inversion filter (IF) modification

A – without IF; B – with IF.

MIC – mandibular incisive canal; red line – distance from MIC to the mental foramen; yellow line – distance from MIC to the alveolar crest; green line – maximum diameter of MIC; blue line – minimum diameter of MIC.

To determine the visibility of MIC, the frequency and confidence intervals (CIs) were evaluated; to determine the occurrence of MIC, McNemar's test was implemented. In order to figure out the differences between the quantitative measurements (the maximum and minimum diameters of the canal, the distance from MIC to the crest and the mental foramen), the mean CI was calculated using the paired *t*-test. If the assumptions were not met through that, the Wilcoxon test was used. The kappa coefficient was used to determine the percentage agreement. The significance level of the tests in this study was set at  $p < 0.05$ .

## Results

Out of the 343 radiography images, 143 (41.7%) belonged to men and 200 (58.3%) to women. Overall, through filtered radiography, the incisive canal was detected in 54 cases (15.7%), whereas this number was 62 cases (18.1%) for the original radiographs. However, these 2 methods did not show a statistically significant difference. It is worth mentioning that MIC was not found to significantly correlate with sex or age.

Regarding the unilateral or bilateral aspect of the canal, out of the 62 original radiographs where the incisive canal was identified, 18 were detected as bilateral (5.2%) and 44 as unilateral (12.8%). The other 281 cases had undetected incisive canals.

In the case of filtered radiography, out of the 54 incisive canals, 14 cases (4.1%) were detected as bilateral and the remaining 40 as unilateral (11.7%). The mandibular incisive canal was not found in 289 of the images.

The difference between the unilateral and bilateral figures regarding the observation of MIC in the original and filtered radiography was not statistically significant (Table 1).

Based on the one-sample *t*-test, the absolute value of the interval difference between the observation of MIC and the mental foramen compared to zero was significant in both the original and filtered radiographs (test value = 0).

Likewise, the absolute values of the interval difference between MIC and the alveolar ridge, and the difference between the maximum and minimum diameters of MIC were statistically significant in both methods used in the study (Table 2).

**Table 1.** Comparison of the frequency of the visibility of the mandibular incisive canal (MIC) and its unilateral or bilateral appearance in the original and filtered radiography

Canal status	IF	Original	<i>p</i> -value
MIC visibility	54 (15.7)	62 (18.1)	0.42
Unilateral	40 (11.7)	18 (5.2)	0.67
Bilateral	14 (4.1)	44 (12.8)	

Data presented as number (percentage).

IF – inversion filter; McNemar's test.

**Table 2.** Comparison of the absolute values of the interval differences between the mandibular incisive canal (MIC) and the alveolar ridge and the mental foramen, and the difference between the maximum and minimum diameters of MIC in the original and filtered radiography

Parameter	Mean $\pm$ SD	<i>p</i> -value
Absolute value of the interval difference between MIC and the mental foramen	1.16 $\pm$ 1.49	0.0001*
Absolute value of the interval difference between MIC and the alveolar ridge	0.37 $\pm$ 0.52	0.0001*
Absolute value of the difference in the maximum MIC diameter	0.08 $\pm$ 0.17	0.021*
Absolute value of the difference in the minimum MIC diameter	0.08 $\pm$ 0.15	0.017*

SD – standard deviation; \* statistically significant.

## Discussion

Although the effect of different filters on the visual improvement of digital images is not yet completely clear, several studies reported using some software modifications.<sup>12,13,15</sup> The inversion filter is one of the tools enabling such a modification and it works by reversing radiographic density.<sup>13</sup> In this study, the effect of using IF to improve the visibility of MIC was investigated by comparing it to the original images. Out of 343 digital panoramic radiographs, 41% belonged to men and 58% to women; the subjects' age ranged between 10 and 82 years.

This study found the frequency of the visibility of MIC to be 18.1% in the original images and 15.7% in the filtered radiographs. These results were higher than those obtained by Romanos et al. (2.7%),<sup>2</sup> but lower than in the studies by Jalili et al. (51.7%),<sup>6</sup> Sahman et al. (61.8%)<sup>4</sup> and Abesi et al. (31.8%).<sup>12</sup> Regarding the distribution of frequency in panoramic radiography, the results of the current study were close to those of Jacobs et al. (15%).<sup>8</sup> This discrepancy may be due to various conditions of observation, the differences in the devices used or in the study population. In the present study, similarly as in the one conducted by Abesi et al.,<sup>12</sup> dentulous cases were taken into consideration.

It must also be mentioned that the visibility of MIC in CBCT was 91% in the study by Makris et al.<sup>1</sup>; this rate was 98.3% in the research by Sahman et al.<sup>4</sup> The latter study reported a rate of 61.8% for the visibility of MIC in panoramic radiography. This could be due to higher accuracy of CBCT as compared to panoramic imaging. In this study, the frequency of MIC in panoramic radiography was 16.9%, of which 12.2% were unilateral (in both the original and filtered images; the left canal was observed more often than the right one) and 4.7% were bilateral. No significant differences between the 2 methods were found. In the study by Romanos et al., 21.4% of the radiographs in which MIC was visible were bilateral and the rest were unilateral: 21.4% of them were observed on the right side and 57.1% on the left side.<sup>2</sup> In the study by Abesi et al., however, MIC was observed more often

bilaterally than unilaterally in both the original and filtered radiography.<sup>12</sup> The difference between left- and right-side observation has only been reported in studies using panoramic radiography, and no differences have been reported in CBCT studies. That being said, according to Sahman et al., there were no significant differences in the diameter of the canal on either side when using CBCT.<sup>4</sup> Thus, the difference between the left and right sides in panoramic images may be related to the weakness of the said technique.

In the present study, the mean intervals from the mental foramen (the canal length) in the original and filtered radiography were  $13.94 \pm 5.24$  mm and  $13.61 \pm 5.14$  mm, respectively. The absolute value of the difference in the canal length was statistically significant in both methods, though this difference was not clinically meaningful. The mean length of the canal in the study by Makris et al. was 15.13 mm (using CBCT) and in the study by Romanos et al., it was 10.7 mm (using panoramic radiography).<sup>1,2</sup> Those results were higher and lower, respectively, than these of the current study. This difference may be attributed to the measurement methods and the study group. In this study, the mean maximum diameters of the canal in the original and filtered radiographs were equal ( $2.16 \pm 0.65$  mm), whereas the mean minimum diameter in the original radiographs was  $1.77 \pm 0.69$  mm and in the filtered radiography –  $1.7 \pm 0.65$  mm. Although these absolute value differences were statistically significant, they were not clinically important. In the study by Sahman et al., the diameter of the canal was generally larger than the diameter measured in the current study; it could be due to their observation on CBCT, which is more accurate than panoramic radiography, or to the differences in the measurement group.<sup>4</sup> In the study by Romanos et al., the diameter of the canal (an average of the maximum and minimum diameter) was reported to be 1.4 mm using panoramic radiography, which is less than in the present study.<sup>2</sup>

Out of the studies reviewed, only Romanos et al. reported the distance from MIC distance to the alveolar crest (as in this study).<sup>2</sup> In the present study, this distance in the original radiographs was  $20.03 \pm 2.48$  mm and  $19.86 \pm 2.58$  mm in the filtered ones. The effect of filtration on MIC was not investigated in the research by Romanos et al. However, considering the fact that both of the mentioned studies were carried out using panoramic radiography, the difference in the distance from MIC to the alveolar crest in the 2 studies could be due to the effect of the racial background on the location of MIC in different populations.

In the present study, the visibility of MIC was similar in men and women, and no significant differences were found between them. Romanos et al. reported that 75% of the MICs found belonged to women and 25% to men.<sup>2</sup> In the studies by Jalili et al. and Jacobs et al., gender had no effect on the clarity of MIC and other anatomical structures

in the interforaminal zone.<sup>6,8</sup> In the present study, there was a significant agreement regarding the clarity of MIC between the 2 methods and in all age groups, which means that in the studied case, the frequency of the visibility of MIC did not change with increasing age in either of the methods. In the study by Jalili et al., patients in the 3<sup>rd</sup> and 4<sup>th</sup> decade of life demonstrated the highest clarity, whereas those in the 1<sup>st</sup> and 2<sup>nd</sup> decade showed the least structural clarity.<sup>6</sup> The latter finding can be attributed to the coexistence of deciduous teeth and permanent teeth buds in both jaws. According to Jacobs et al., however, age had no effect on the clarity of MIC.<sup>8</sup> The reason for such differences in various studies might be the variations in the study groups' age and ethnic background.

## Conclusions

Based on the findings of this study, the use of IF produced similar results to the original radiography and its application did not increase the clarity and would not improve the visibility of the incisive canal over the original images. Moreover, the interval difference between the MIC and the mental foramen, the differences in the maximum and minimum diameters of MIC, and the interval difference between MIC and the alveolar crest were not clinically important, either.

In general, according to the results of the present study, the use of IF did not affect the detection of the incisive canal in digital radiographic images. Thus, if a more precise method for such a task is required, a more advanced imaging technique such as CBCT is suggested.

## ORCID iDs

Farzaneh Ostovarrad  <https://orcid.org/0000-0002-2618-6056>  
Somayeh Nemati  <https://orcid.org/0000-0002-0442-4359>  
Abbas Shokri  <https://orcid.org/0000-0002-3434-3672>  
Elaheh Baghizadeh  <https://orcid.org/0000-0003-3450-1973>  
Zahra Yousefi  <https://orcid.org/0000-0001-7598-0478>

## References

1. Makris N, Stamatakis H, Syriopoulos K, Tsiklakis K, van der Stelt PF. Evaluation of the visibility and the course of the mandibular incisive canal and the lingual foramen using cone-beam computed tomography. *Clin Oral Implants Res.* 2010;21(7):766–771.
2. Romanos GE, Papadimitriou DE, Royer K, et al. The presence of the mandibular incisive canal: A panoramic radiographic examination. *Implant Dent.* 2012;21(3):202–206.
3. Kütük N, Demirbaş AE, Gönen ZB, et al. Anterior mandibular zone safe for implants. *J Craniofac Surg.* 2013;24(4):e405–e408.
4. Sahman H, Sekerci AE, Sisman Y, Payveren M. Assessment of the visibility and characteristics of the mandibular incisive canal: Cone-beam computed tomography versus panoramic radiography. *Int J Oral Maxillofac Surg.* 2014;29(1):71–78.
5. Jacobs R, Mraiwa N, van Steenberghe D, Gijbels F, Quirynen M. Appearance, location, course, and morphology of the mandibular incisive canal: An assessment on spiral CT scan. *Dentomaxillofac Radiol.* 2002;31(5):322–327.
6. Jalili MR, Esmaeelinejad M, Bayat M, Aghdasi MM. Appearance of anatomical structures of mandible on panoramic radiographs in Iranian population. *Acta Odontol Scand.* 2012;70(5):384–389.

7. Pires CA, Bissada NF, Becker JJ, Kanawati A, Landers MA. Mandibular incisive canal: Cone-beam computed tomography. *Clin Implant Dent Relat Res*. 2012;14(1):67–73.
8. Jacobs R, Mraiwa N, van Steenberghe D, Sanderink G, Quirynen M. Appearance of the mandibular incisive canal on panoramic radiographs. *Surg Radiol Anat*. 2004;26(4):329–333.
9. Miresmaeili A, Basafa M, Shamsabadi RM, Farhadian N, Moghymbeigi A, Mollabashi V. Treatment decision analysis for palatally-displaced canines based on orthodontists' opinion and CBCT. *Int Orthod*. 2017;15(4):625–639.
10. Miresmaeili A, Farhadian N, Mollabashi V, Yousefi F. Web-based evaluation of experts' opinions on impacted maxillary canines forced eruption using CBCT. *Dental Press J Orthod*. 2015;20(2):90–99.
11. Eskandarloo A, Mirshekari A, Poorolajal J, Mohammadi Z, Shokri A. Comparison of cone-beam computed tomography with intraoral photostimulable phosphor imaging plate for diagnosis of endodontic complications: A simulation study. *Oral Surg Oral Med Oral Pathol Oral Radiol*. 2012;114(6):e54–e61.
12. Abesi F, Nikafshar N, Haghanifar S, Khafri S, Hamzeh M. Can the inversion filter improve the visibility of the mandibular incisive canal? *Iran J Radiol*. 2016;13(1):e22698.
13. van der Stelt PF. Filmless imaging: The uses of digital radiography in dental practice. *J Am Dent Assoc*. 2005;136(10):1379–1387.
14. Hildebolt CF, Couture RA, Whiting BR. Dental photostimulable phosphor radiography. *Dent Clin North Am*. 2000;44(2):273–297.
15. Sparavigna AC. An image processing approach based on GNU Image Manipulation Program GIMP to the panoramic radiography. *Int J Sci*. 2015;4(5):57–67.



# Comparison of the radiopacity of selected materials used for vital pulp therapy: An in vitro assessment

## Porównanie pochłaniania promieni rentgenowskich przez wybrane materiały stosowane w leczeniu biologicznym miazgi – ocena in vitro

Elżbieta Łuczaj-Cepowicz<sup>1,A–E</sup>, Grażyna Marczuk-Kolada<sup>1,A–E</sup>, Małgorzata Pawińska<sup>2,D,E</sup>, Janusz Różycki<sup>3,B,C</sup>, Ewa Chorzewska<sup>1,E</sup>

<sup>1</sup> Department of Pedodontics, Medical University of Białystok, Poland

<sup>2</sup> Department of Integrated Dentistry, Medical University of Białystok, Poland

<sup>3</sup> Department of Radiology, Medical University of Białystok, Poland

A – research concept and design; B – collection and/or assembly of data; C – data analysis and interpretation; D – writing the article; E – critical revision of the article; F – final approval of the article

Dental and Medical Problems, ISSN 1644-387X (print), ISSN 2300-9020 (online)

*Dent Med Probl.* 2019;56(3):285–290

### Address for correspondence

Grażyna Marczuk-Kolada  
E-mail: grazyna.kolada@umb.edu.pl

### Funding sources

None declared

### Conflict of interest

None declared

Received on February 5, 2019

Reviewed on April 9, 2019

Accepted on May 21, 2019

Published online on August 7, 2019

### Cite as

Łuczaj-Cepowicz E, Marczuk-Kolada G, Pawińska M, Różycki J, Chorzewska E. Comparison of the radiopacity of selected materials used for vital pulp therapy: An in vitro assessment. *Dent Med Probl.* 2019;56(3):285–290. doi:10.17219/dmp/109550

### DOI

10.17219/dmp/109550

### Copyright

© 2019 by Wrocław Medical University

This is an article distributed under the terms of the

Creative Commons Attribution 3.0 Unported License (CC BY 3.0)

(<https://creativecommons.org/licenses/by/3.0/>)

## Abstract

**Background.** An assessment of the therapeutic effects of vital pulp treatment is based on both clinical and radiological evaluation.

**Objectives.** The aim of the research was a long-term (after 1, 2, 4, 6, and 8 weeks) radiological assessment of X-ray absorption by 8 selected materials used for the vital treatment of dental pulp.

**Material and methods.** The materials, prepared in accordance with the manufacturers' recommendations, were placed in molds measuring 10 mm in diameter and 2 mm in thickness. The molds with the samples were placed on an occlusal film with an aluminum step wedge, and then X-rayed using an intraoral X-ray unit. After processing, an X-ray image with varying degrees of opacity was obtained. The radiological density of the samples, the step wedge and the background was measured 6 times using a densitometer. The tests were repeated at the following intervals: after 7 days, and after 2, 4, 6, and 8 weeks. The molds with the material samples were stored in an incubator at 37°C and 95% humidity.

**Results.** The obtained results were statistically analyzed. The mineral trioxide aggregate (MTA) materials exhibited the highest degree of contrast, whereas the lowest radiopacity was shown for the non-setting calcium hydroxide preparations ( $p < 0.0001$ ). Calcium hydroxide cements presented medium radiopacity values.

**Conclusions.** The radiopacity of all the evaluated materials showed a statistically insignificant increasing tendency with regard to the duration of the experiment. All the tested preparations showed acceptable radiopacity, enabling radiological detection in the course of vital pulp therapy.

**Key words:** mineral trioxide aggregate, densitometry, calcium hydroxide, X-ray absorption, vital dental pulp therapy

**Słowa kluczowe:** agregat trójtlenków mineralnych, densytometria, wodorotlenek wapnia, pochłanianie promieni rentgenowskich, leczenie biologiczne miazgi zębów

## Introduction

The aim of conservative dental pulp treatment is to maintain the function of the dentin pulp complex, which enables healing and dentin bridge formation. Additionally, in the case of teeth with incomplete root development, viable, healthy crown and root pulp ensures normal apexogenesis.<sup>1</sup> Although viable pulp preservation in carious pulp exposure is controversial, such management is commonly accepted in teeth with incomplete root development.<sup>1,2</sup>

The use of pulp-coating materials, marked by biocompatibility, insolubility in tissue fluids, antibacterial activity, long-term sealing ability, and mechanical strength as well as the ability to stimulate and form mineralized tissues, is one of the conditions for successful vital pulp treatment. Until recently, non-setting calcium hydroxide preparations were conventionally used for this purpose. However, due to some defects of these materials, such as poor adhesion to dentin, rapid loss of sealing ability, high solubility, low mechanical strength, and tunnel defects in dentin bridges, research has been conducted to develop other preparations.<sup>1,3</sup> In order to eliminate these defects, setting calcium hydroxide cements were developed. Although improved dentin adherence, higher mechanical strength and lower solubility were achieved, tunnel defects in dentin bridges have still not been eliminated.<sup>4,5</sup> In the 1990s, mineral trioxide aggregate (MTA), which showed very good sealing properties, mechanical strength and low solubility, was introduced into the vital treatment of dental pulp.<sup>6</sup> It was also observed that the reparative dentin formed upon contact with MTA was homogeneous.<sup>4</sup>

An assessment of the therapeutic effects of vital pulp treatment is based on both clinical and radiological evaluation. Only radiological evaluation allows tracing the formation of mineralized tissues at the site of contact with the therapeutic material as well as the progress of apexogenesis in the case of teeth with incomplete root development. The degree of X-ray absorption seems to be an important characteristic of these preparations, enabling their differentiation from mineralized dental tissues. The process of formation of these tissues is of varying duration due to the effects of odontotropic medication.<sup>7</sup> In the case of calcium hydroxide, mineralized barrier formation was observed not earlier than after 30 days, although most authors report longer periods, i.e., at least 60 days.<sup>8</sup> The use of MTA accelerates the healing process with a hard tissue bridge being formed, which, according to Parolia et al., becomes noticeable after 15–45 days.<sup>9</sup>

Therefore, a long-term radiological assessment of X-ray absorption by the abovementioned materials seems to be of importance.

## Material and methods

### Preparation of test specimens

The 8 materials included in this study were: MTA Angelus White® (Angelus Indústria de Produtos Odontológicos S/A, Londrina, Brazil); MTA Angelus Grey® (Angelus Indústria de Produtos Odontológicos S/A);

Table 1. Composition of evaluated materials as provided by the manufacturers

Material	Composition	Manufacturer	Batch number
MTA Angelus White	tricalcium silicate, dicalcium silicate, tricalcium aluminate, bismuth oxide, calcium oxide	Angelus Indústria de Produtos Odontológicos S/A, Londrina, Brazil	9874
MTA Angelus Grey	tricalcium silicate, dicalcium silicate, tricalcium aluminate, bismuth oxide, calcium oxide, tetracalcium aluminoferrite	Angelus Indústria de Produtos Odontológicos S/A, Londrina, Brazil	12872
ProRoot MTA	tricalcium silicate, dicalcium silicate, tricalcium aluminate, bismuth oxide, calcium sulfate dihydrate	Dentsply International Inc., Johnson City, USA	10003598
Biopulp	calcium dihydroxide, dibasic calcium phosphate, magnesium oxide, sodium chloride, anhydrous calcium chloride, potassium chloride, anhydrous sodium carbonate	Chema-Elektromet, Rzeszów, Poland	090903
Calcipro	calcium dihydroxide, barium sulfate	lege artis Pharma GmbH + Co. KG, Dettenhausen, Germany	0940907
Calcipulpe	calcium dihydroxide, barium sulfate, carboxymethylcellulose, excipients	Septodont, Saint-Maur-des-Fossés, France	42698AE
Dycal	base: 1,3-butylene glycol disalicylate, zinc oxide, calcium phosphate, calcium tungstate, iron oxide pigments; catalyst: calcium dihydroxide, N-ethyl-o/p-toluene sulfonamide, zinc oxide, titanium dioxide, zinc stearate, iron oxide pigments	Dentsply DeTrey GmbH, Konstanz, Germany	070821
Life	base: calcium dihydroxide, N-ethyl-o/p-toluene sulfonamide, zinc oxide, calcium oxide; catalyst: methyl salicylate, barium sulfate, titanium dioxide, 2-2-dimethylpropane-1,3-diol	Kerr Italia S.r.l., Scafati, Italy	3628677

MTA – mineral trioxide aggregate.

ProRoot® MTA (Dentsply International Inc., Johnson City, USA); Biopulp® (Chema-Elektromet, Rzeszów, Poland); Calcipro® (Ige artis Pharma GmbH + Co. KG, Dettenhausen, Germany); Calcipulpe® (Septodont, Saint-Maur-des-Fossés, France); Dycal® (Dentsply DeTrey GmbH, Konstanz, Germany); and Life® (Kerr Italia S.r.l., Scafati, Italy). The main components of each material are described in Table 1. The materials were placed in molds, which allowed obtaining samples that were 10 mm in diameter and 2 mm in thickness.

## Evaluation of the radiopacity of the tested materials

The molds with the samples were placed on a Kodak occlusal film, size 4, with D speed (Carestream Health France, Noisy-le-Grand, France) with an aluminum step wedge, and then X-rayed using a Planmeca Intra® intraoral X-ray unit (Planmeca Oy, Helsinki, Finland) with the following exposure parameters: 70 kV and 8 mA. The distance between the tube and the film surface was 30 cm. The exposure time was selected experimentally using a step wedge filter. The aluminum step wedge, made of 99% pure aluminum, with 16 incremental steps, each 1-millimeter-thick, was used as a standard for comparing the radiodensity of the tested materials and controlling for any variations in exposure and processing (Fig. 1).

After irradiation, the films were processed in an XR 25S automatic imager (Dürr Dental SE, Bietigheim-Bissingen, Germany). Processing was done using freshly prepared original chemical reagents. This way, an X-ray image with varying degrees of opacity was obtained. The radiological density of the samples, the step wedge and the background was measured 6 times using a Duolight A densitometer, v. 2.47 (IBA Dosimetry GmbH, Schwartzenbruck, Germany), choosing places with a homogeneous structure.




Fig. 1. Radiograph with sample disks of the freshly prepared study materials and the aluminum step wedge

The obtained results were presented in a numerical form as mean radiodensity. The tests were repeated at the following intervals: after 7 days, and after 2, 4, 6, and 8 weeks. The molds with the material samples were stored between the subsequent tests in an incubator at 37°C and 95% humidity.

In order to determine the radiopacity of the 2-millimeter-thick samples of the tested materials, a calibration curve for the step wedge was generated (creating a regression curve for the aluminum step wedge). The radiopacity of the specimens was expressed in terms of the equivalent thickness of aluminum, according to the methodology presented by other authors.<sup>10–12</sup> The comparison of the numerical values obtained during the irradiation of the tested materials and from the step wedge filter made it possible to determine the degree of X-ray absorption by evaluating the preparations relative to the thickness of the X-rayed aluminum.

## Statistical analysis

The statistical analysis was performed using the Statistica, v. 8.0 (StatSoft Inc., Tulsa, USA) software package. The data was analyzed by means of the analysis of variance (ANOVA) and the post hoc Tukey test. The level of significance was set at  $p < 0.05$ .

## Results

The mean values and standard deviations of radiopacity, expressed in mm of aluminum thickness, for all materials at 6 time points are shown in Fig. 2.

Mineral trioxide aggregate exhibited the highest degree of radiopacity. Among the MTA products, MTA Angelus Grey showed significantly higher radiopacity at all time points ( $p < 0.0001$ ). No significant differences were found in the radiopacity of MTA Angelus White and ProRoot MTA after 2, 4 and 6 weeks only.

The lowest radiopacity was shown for the non-setting calcium hydroxide preparations. No significant differences were found between Biopulp and Calcipro at any time points. Calcipulpe showed higher radiopacity compared to other non-setting calcium hydroxide materials, but only at 2 and 4 weeks after preparation. Calcium hydroxide cements – Life and Dycal – had medium radiopacity values compared to the previously described groups. No statistically significant differences were found between Life and Dycal at any study time points. All other differences in radiopacity at different study time points were highly significant ( $p < 0.0001$ ).

The changes in the radiopacity of the study materials throughout the experiment are shown in Fig. 3. The radiopacity of all the evaluated materials showed a statistically insignificant increasing tendency.



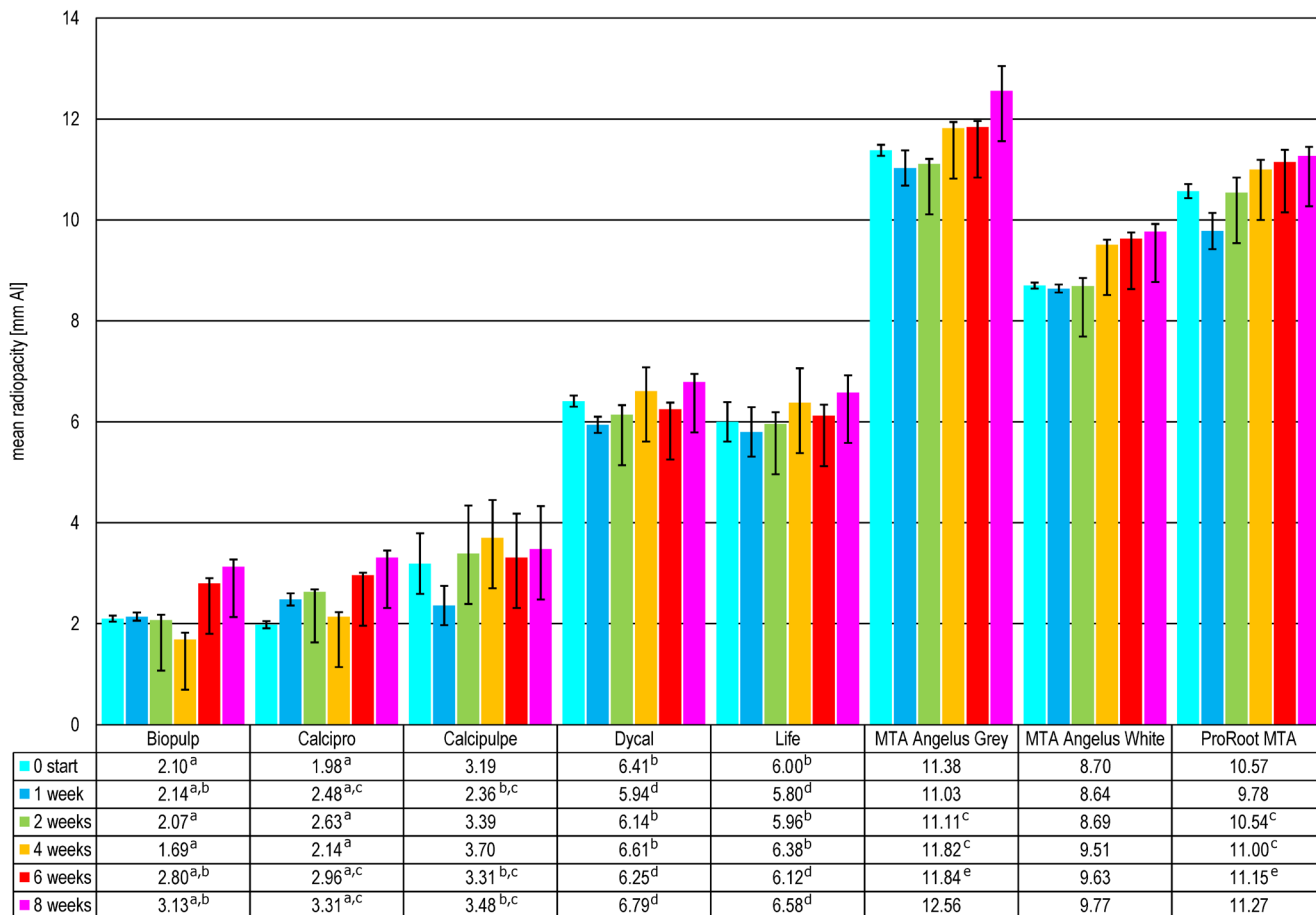


Fig. 2. Mean values and standard deviations of radiopacity for all materials at 6 time points

Values which have not been tagged with identical superscript letters in the same line indicate statistically significant differences at  $p < 0.0001$ ; values which have been tagged with identical superscript letters in the same line show statistically insignificant differences ( $p > 0.05$ ).

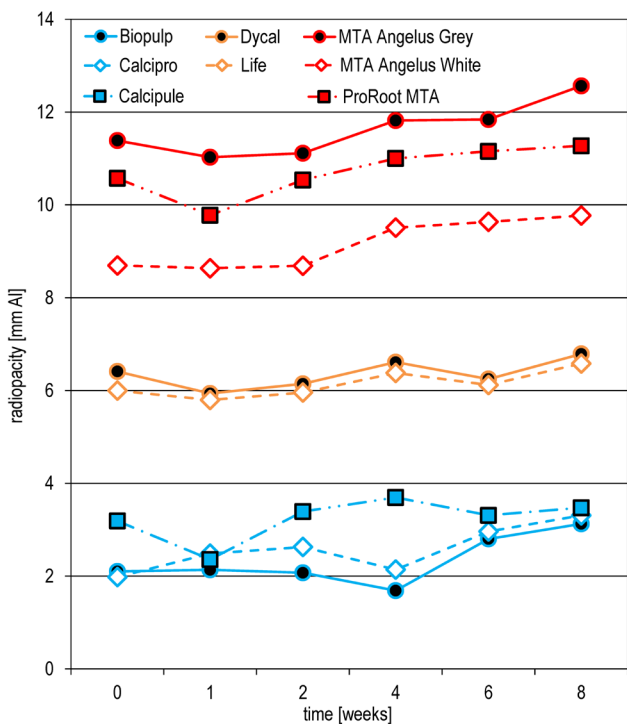


Fig. 3. Radiopacity of the study materials throughout the duration of the experiment

## Discussion

The ability to absorb X-rays – radiopacity – is an important and required feature of materials used in dental treatment. The use of an aluminum step wedge is recommended as a reference standard. According to ISO 6876/2001 specifications, a step wedge should have a purity of at least 98% aluminum.<sup>13</sup> It has been used with an occlusal film in most published studies to determine the optical density of materials.<sup>10,11,14,15</sup> We used this method in our experiment to determine the radiopacity of materials used in the vital treatment of dental pulp.

Some authors have compared the radiopacity of materials to that of mineralized dental tissues (enamel and dentin).<sup>16–18</sup> However, the optical density of both enamel and dentin is variable. It depends on the patient’s age and the individual degree of tissue mineralization. The storage method for the removed tooth used for comparisons also seems important.<sup>16</sup> Furthermore, it has been demonstrated that the radiopacity of pure aluminum is similar to that of human dentin.<sup>12</sup> Thus, we only used a step wedge in our study.

However, studies on the radiopacity of dental materials conducted by other authors are not unanimous regarding the thickness of the analyzed samples. Samples

of a thickness from 0.5 up to 2.5 mm have been evaluated.<sup>11,15,19–21</sup> According to Watts and McCabe, using 2-millimeter-thick samples is one of the ways to obtain good contrast in relation to the degree of shading of the film background.<sup>12</sup> We used the same sample thickness in our study, similarly to other authors.<sup>19</sup>

According to ISO standards, the radiopacity of dental cements should be equal to or higher than that of aluminum of the same thickness.<sup>16</sup> We found no studies in the available literature comparing the groups of materials or observing the time points described in our experiment. In our study, we evaluated the radiopacity of fresh samples at baseline, and then 5 times – after 1, 2, 4, 6, and 8 weeks. We believe that a long-term radiopacity assessment of the materials used in vital pulp treatment is important from a clinical practice point of view. According to the literature, the duration of hard tissue bridge mineralization is from 21 to 60 days.<sup>8,9,22</sup> This depends on the type of material used. In our experiment, we used 3 groups of materials, and therefore, the observation period was prolonged to 8 weeks. In the available literature, only Cutajar et al. presented the radiopacity observations of MTA 7 and 28 days after preparation.<sup>23</sup> In other studies, the materials were evaluated once, immediately after preparation<sup>18,24–26</sup> or after setting.<sup>11</sup> However, Islam et al.<sup>27</sup> and Chng et al.<sup>28</sup> measured the MTA radiopacity 4 times – from baseline (fresh samples) until complete setting.

In our experiment, the first radiopacity assessment was performed immediately after preparation. Only a fresh sample from Calcipro, despite the addition of barium sulfate, showed lower radiopacity, with an aluminum equivalent value of 1.98 mm. Other tested non-setting calcium hydroxide materials reached the minimum required radiopacity, ranging from 2.10 to 3.19 mm Al. This result is difficult to interpret. Manufacturers do not provide full ingredient lists; they only use terms such as ‘excipients’. This may suggest that other ingredients besides barium sulfate influence radiopacity, which is confirmed by the literature data.<sup>26</sup> The authors also noted that non-setting calcium hydroxide materials are characterized by high X-ray permeability.<sup>18</sup> The most radiopaque materials among the tested objects were the MTA preparations, with radiopacity ranging from 8.70 to 11.38 mm Al. Laghios et al. showed lower radiopacity of MTA samples of 2 mm (6.43 mm Al) than what we observed in our study.<sup>24</sup> This may be due to different exposure conditions. Other authors made similar observations.<sup>27,28</sup> Kim et al. found high radiopacity of 1-millimeter-thick samples of ProRoot MTA (6.92 mm Al).<sup>25</sup> Researchers who evaluated samples after setting also showed high radiopacity of MTA.<sup>14,29</sup> Differences in radiopacity between the assessed MTA preparations, despite similar bismuth oxide content, could be the result of varying chemical compound proportions in the materials.<sup>30</sup> Setting calcium hydroxide cements – Dycal and Life – obtained radiopacity values lower than MTA preparations (6.41 mm Al and 6.00 mm Al, respectively).

Both these cements belong to a group showing medium radiopacity values, as confirmed by Devito et al.<sup>15</sup> Life and Dycal showed similar radiopacity despite certain differences in their chemical composition.

While analyzing the changes in the radiopacity of each of the evaluated preparations during the 8-week experiment, we noticed that the optical density of all materials increased insignificantly. Our study showed a steady, insignificant increase in optical density 6 and 8 weeks after sample preparation. Also, all materials exceeded the minimum values of recommended radiopacity.

Difficulties in determining the detailed concentrations of radiopaque substances in the tested materials and problems with the simulation of the oral environment may be possible limitations of the present study.

## Conclusions

Within the limitations of the present study, based on the obtained results, the tested materials can be divided into 3 groups in terms of their radiopacity. The highest radiopacity was produced by the MTA preparations, followed by the setting calcium hydroxide materials, and was the lowest in the non-setting calcium hydroxide group.

To conclude, considering that a material must be radiopaque, a clinician must pay careful attention to the chemical composition characteristic to a certain group of preparations. It can be stated that all the tested preparations showed acceptable radiopacity, enabling radiological detection during vital pulp therapy. However, radiopacity is only one of the components that affect the efficacy of therapeutic procedures. Therefore, other factors determining the choice of therapeutic materials should also be taken into account.

## ORCID iDs

Elżbieta Łuczaj-Cepowicz  <https://orcid.org/0000-0002-3055-5918>  
 Grażyna Marczyk-Kolada  <https://orcid.org/0000-0002-2344-9922>  
 Małgorzata Pawińska  <https://orcid.org/0000-0003-0044-638X>  
 Janusz Różycki  <https://orcid.org/0000-0002-6423-5365>  
 Ewa Chorzewska  <https://orcid.org/0000-0003-2464-5316>

## References

- Nosrat A, Seifi A, Asgary S. Pulpotomy in caries-exposed immature permanent molars using calcium-enriched mixture cement or mineral trioxide aggregate: A randomized clinical trial. *Int J Paediatr Dent.* 2013;23(1):56–63.
- Witherspoon DE. Vital pulp therapy with new materials: New directions and treatment perspectives – permanent teeth. *J Endod.* 2008;34(7 Suppl):S25–S28.
- Paranjpe A, Zhang H, Johnson JD. Effects of mineral trioxide aggregate on human dental pulp cells after pulp-capping procedures. *J Endod.* 2010;36(6):1042–1047.
- Nair PN, Duncan HF, Pitt Ford TR, Luder HU. Histological, ultrastructural and quantitative investigations on the response of healthy human pulps to experimental capping with mineral trioxide aggregate: A randomized controlled trial. *Int Endod J.* 2008;41(2):128–150.
- Swift EJ Jr., Trope M, Ritter AV. Vital pulp therapy for the mature tooth – can it work? *Endod Topics.* 2003;5(1):49–56.

6. Cianconi L, Palopoli P, Campanella V, Mancini M. Composition and microstructure of MTA and Aureoseal Plus: XRF, EDS, XRD and FESEM evaluation. *Eur J Paediatr Dent.* 2016;17(4):281–285.
7. Ferracane JL, Cooper PR, Smith AJ. Can interaction of materials with the dentin-pulp complex contribute to dentin regeneration? *Odontol.* 2010;98(1):2–14.
8. Olsson H, Petersson K, Rohlin M. Formation of a hard tissue barrier after pulp cappings in humans. A systematic review. *Int Endod J.* 2006;39(6):429–442.
9. Parolia A, Kundabala M, Rao NN, et al. A comparative histological analysis of human pulp following direct pulp capping with Propolis, mineral trioxide aggregate and Dycal. *Aust Dent J.* 2010;55(1):59–64.
10. Camilleri J, Gandolfi MG. Evaluation of the radiopacity of calcium silicate cements containing different radiopacifiers. *Int Endod J.* 2010;43(1):21–30.
11. Dionysopoulos D, Tolidis K, Gerasimou P, Koliniotou-Koumpia E. Effects of shade and composition on radiopacity of dental composite restorative materials. *Oral Radiol.* 2017;33(3):178–186.
12. Watts DC, McCabe JF. Aluminium radiopacity standards for dentistry: An international survey. *J Dent.* 1999;27(1):73–78.
13. Baksi BG, Ermis RB. Comparison of conventional and digital radiography for radiometric differentiation of dental cements. *Quintessence Int.* 2007;38(9):e532–e536.
14. Souza LC, Yadlapati M, Dorn SO, Silva R, Letra A. Analysis of radiopacity, pH and cytotoxicity of a new bioceramic material. *J Appl Oral Sci.* 2015;23(4):383–389.
15. Devito KL, Ortega AI, Haiter-Neto F. Radiopacity of calcium hydroxide cement compared with human tooth structure. *J Appl Oral Sci.* 2004;12(4):290–293.
16. Antonijevic D, Jevremovic D, Jovanovic S, Obradovic-Djuricic K. An in vitro radiographic analysis of the density of dental luting cements as measured by CCD-based digital radiography. *Quintessence Int.* 2012;43(5):421–428.
17. Medgovic IM, Antonijevic D. In vitro radiographic density of dental posts measured by digital radiography. *Oral Radiol.* 2014;30(1):9–12.
18. Pires de Souza FC, Pardini LC, Cruvinel DR, Hamida HM, Garcia LF. In vitro comparison of the radiopacity of cavity lining materials with human dental structures. *J Conserv Dent.* 2010;13(1):65–70.
19. Bueno CE, Zeferino EG, Manhães LR Jr., Rocha DG, Cunha RS, De Martin AS. Study of the bismuth oxide concentration required to provide Portland cement with adequate radiopacity for endodontic use. *Oral Surg Oral Med Oral Pathol Oral Radiol Endod.* 2009;107(1):e65–e69.
20. Tanalp J, Karapınar-Kazandağ M, Dölekoğlu S, Kayahan MB. Comparison of the radiopacities of different root-end filling and repair materials. *ScientificWorldJournal.* 2013;2013:594950.
21. Tanomaru-Filho M, Jorge EG, Tanomaru JMG, Gonçalves M. Evaluation of the radiopacity of calcium hydroxide- and glass-ionomer-based root canal sealers. *Int Endod J.* 2008;41(1):50–53.
22. Dammaschke T, Stratmann U, Wolff P, Sagheri D, Schäfer E. Direct pulp capping with mineral trioxide aggregate: An immunohistologic comparison with calcium hydroxide in rodents. *J Endod.* 2010;36(5):814–819.
23. Cutajar A, Mallia B, Abela S, Camilleri J. Replacement of radiopacifier in mineral trioxide aggregate; characterization and determination of physical properties. *Dent Mater.* 2011;27(9):879–891.
24. Laghios CD, Benson BW, Gutmann JL, Cutler CW. Comparative radiopacity of tetracalcium phosphate and other root-end filling materials. *Int Endod J.* 2000;33(4):311–315.
25. Kim EC, Lee BC, Chang HS, Lee W, Hong CU, Min KS. Evaluation of the radiopacity and cytotoxicity of Portland cements containing bismuth oxide. *Oral Surg Oral Med Oral Pathol Oral Radiol Endod.* 2008;105(1):e54–e57.
26. Ordinola-Zapata R, Bramante CM, García-Godoy F, et al. The effect of radiopacifiers agents on pH, calcium release, radiopacity, and antimicrobial properties of different calcium hydroxide dressings. *Microsc Res Tech.* 2015;78(7):620–625.
27. Islam I, Chng HK, Yap AU. Comparison of the physical and mechanical properties of MTA and portland cement. *J Endod.* 2006;32(3):193–197.
28. Chng HK, Islam I, Yap AU, Tong YW, Koh ET. Properties of a new root-end filling material. *J Endod.* 2005;31(9):665–668.
29. Danesh G, Dammaschke T, Gerth HU, Zandbiglari T, Schäfer E. A comparative study of selected properties of ProRoot mineral trioxide aggregate and two Portland cements. *Int Endod J.* 2006;39(3):213–219.
30. Parirokh M, Torabinejad M. Mineral trioxide aggregate: A comprehensive literature review – part I: Chemical, physical, and antibacterial properties. *J Endod.* 2010;36(1):16–27.

# Dental treatment of post-myocardial infarction patients: A review of the literature

## Leczenie stomatologiczne pacjentów po przebytych zawale mięśnia sercowego – przegląd piśmiennictwa

Renata Samulak-Zielińska<sup>1,A,B,D,F</sup>, Elżbieta Dembowska<sup>1,D–F</sup>, Piotr Lizakowski<sup>2,B,D–F</sup>

<sup>1</sup> Department of Periodontology, Pomeranian Medical University in Szczecin, Poland

<sup>2</sup> Specialist Medical Practice in Szczecin, Poland

A – research concept and design; B – collection and/or assembly of data; C – data analysis and interpretation;  
D – writing the article; E – critical revision of the article; F – final approval of the article

Dental and Medical Problems, ISSN 1644-387X (print), ISSN 2300-9020 (online)

*Dent Med Probl.* 2019;56(3):291–298

### Address for correspondence

Renata Samulak-Zielińska

E-mail: renata.samulak.zielinska@gmail.com

### Funding sources

None declared

### Conflict of interest

None declared

Received on January 2, 2019

Reviewed on February 20, 2019

Accepted on May 8, 2019

Published online on September 30, 2019

### Abstract

Patients who have suffered a heart attack often require dental treatment. The inflammation of the oral cavity not only reduces the quality of life, but also negatively affects the course of ischemic heart disease. Dental treatment in patients with a history of myocardial infarction seems complicated, since these patients require special consideration with regard to the timing and form of dental treatment as well as to the precautions required. Patients at risk of cardiac complications that are greater than the benefits of dental treatment should be identified and only the most urgent conditions should be treated. The aim of this study was to present the latest guidelines for dental treatment in patients who have suffered myocardial infarction. We reviewed the available literature explaining when dental treatment can be undertaken, whether antibiotic prophylaxis is required, whether the patient can be anesthetized locally, and how to provide the maximum safety during the visit. The principles of the surgical treatment of patients receiving drugs that affect hemostasis were also reviewed.

**Key words:** dental care, oral anticoagulants, antibiotic prophylaxis, myocardial infarction

**Słowa kluczowe:** opieka stomatologiczna, doustne antykoagulanty, profilaktyka antybiotykowa, zawał mięśnia sercowego

### Cite as

Samulak-Zielińska R, Dembowska E, Lizakowski P. Dental treatment of post-myocardial infarction patients: A review of the literature. *Dent Med Probl.* 2019;56(3):291–298. doi:10.17219/dmp/109232

### DOI

10.17219/dmp/109232

### Copyright

© 2019 by Wrocław Medical University

This is an article distributed under the terms of the

Creative Commons Attribution 3.0 Unported License (CC BY 3.0)

(<https://creativecommons.org/licenses/by/3.0/>)

## Introduction

The number of patients with general diseases requiring dental treatment is on the increase. According to the estimates presented in Bhateja's report, out of 36,729 patients of Dental College and Hospital in Mathura, India, 58% had a history of cardiovascular disease.<sup>1</sup> Such patients require an individualized treatment plan and the continuous monitoring of oral health. The current state of knowledge indicates that inflammation in the oral cavity, particularly periodontitis, affects the general state of health, including the development and course of atherosclerosis. Cardiovascular disease has an inflammatory origin. Firstly, there is an increase in the level of pro-inflammatory mediators in response to the presence of Gram-negative lipopolysaccharides (LPSs), C-reactive protein (CRP), interleukin 1 $\beta$  and interleukin 6 (IL-1 $\beta$  and IL-6), tumor necrosis factor alpha (TNF- $\alpha$ ), fibrinogen, and matrix metalloproteinase 9 (MMP-9). These substances contribute to the destabilization of the atherosclerotic plaque.<sup>2</sup> Secondly, there is a cross-reaction of the patient's antibodies with heat shock protein (HSP) present in the damaged vascular endothelium and atherosclerotic plaques. This leads to the continuation of the inflammatory process, and thus to the progression of the disease. Cross-reactivity is triggered by the presence of oral bacteria *Porphyromonas gingivalis* and *Tannerella forsythia*, whose HSP is in 60% homologous to HSP found in mammals.<sup>3</sup> Thirdly, direct bacterial mechanisms (e.g., bacterial enzyme activity) contribute to the progression of cardiovascular disease. Bacterial DNA of *Tannerella forsythia*, *Porphyromonas gingivalis*, *Aggregatibacter actinomycetemcomitans*, and *Prevotella intermedia* has been found in the atherosclerotic plaque.<sup>4</sup> Finally, the concept of 'vascular endothelial activation' can explain the mechanism underlying inflammatory-induced atherosclerotic plaque formation. The LPS binding, bacterial outer membrane vesicles, fimbriae, and other bacterial antigenic structures have an impact on the local and systemic host response. This leads to the upregulation of endothelial cell receptors followed by monocyte adhesion to the vascular wall. Monocytes migrate into the subendothelial space, absorb low-density lipoprotein cholesterol (LDL-C) and become foam cells. After their apoptosis, lipids are accumulated in the vessel wall, covered by matrix and accompanied by smooth muscle cell proliferation, which is induced by invasive periodontal pathogens. The enzymatic degradation of the extracellular matrix results in plaque rupture, the exposure of prothrombotic components and subsequent thrombus formation, which ultimately leads to blood vessel occlusion.<sup>4</sup> This results in a need for treatment of oral cavity diseases as well as in intensive efforts toward periodontal disease prevention in patients with cardiovascular diseases.<sup>5</sup>

The need for periodontal treatment is significant among Polish patients after myocardial infarction. With regard to the Community Periodontal Index of Treatment

Needs (CPITN), 38.6% of them have a score of 3 and 46% a score of 4, meaning they are in urgent need of periodontal treatment.<sup>6</sup> Questions concerning the safety of dental treatment of patients after myocardial infarction need to be addressed.

## Material and methods

To identify key words, a Population, Intervention, Comparison and Outcome (PICO) question was formulated as: What are the safety rules for dental care of patients following myocardial infarction? A comprehensive search of the MEDLINE (PubMed), Scopus and Google Scholar electronic databases was undertaken in January 2019 to find relevant articles, using the following search terms: [dental care OR dental anesthesia OR tooth extraction] AND [myocardial infarction OR ischemic heart disease]. The timeframe was 2000–2019. Additionally, a manual search of the bibliographies of full-text articles was also conducted. The guidelines of the American Heart Association (AHA), American College of Cardiology (ACC), European Society of Cardiology (ESC), and Polish Society of Cardiology were also reviewed. We considered reviews, systematic reviews, guidelines and statements of dental and cardiological associations, randomized controlled trials (RCTs) as well as cohort, case and cross-sectional studies. Papers with abstracts written in English or Polish were included. Letters, book chapters, case reports, and studies without an abstract or with no full text available were not included. Only publications addressing the protocol for the treatment of post-myocardial infarction patients were analyzed. Articles dealing with the influence of oral inflammation on cardiovascular disease or the effects of dental treatment on general health were excluded.

The limitations of this review include the open PICO question, the broad spectrum of relevant issues requiring urgent explanation, and the restriction to cardiological society guidelines and reviews rather than RCTs. Taking all this into account, only some of the Preferred Reporting Items for Systematic Reviews and Meta-Analyses (PRISMA) rules could be fulfilled. The study selection was conducted independently by 2 reviewers (PL and RSZ), with any disagreements resolved by the 3<sup>rd</sup> reviewer (ED). A total of 37 articles were included in the review. No meta-analyses or systematic reviews were found.

Our findings were compatible with those presented by Napeñas et al. at a panel of experts during World Workshop on Oral Medicine VI.<sup>7</sup> They stated that "with a lack of consensus statements, guidelines, or systematic reviews focused on these specific issues related to dental treatment for patients with cardiovascular diseases, the vast majority of current recommendations are not linked to levels of evidence and are presumably derived from expert opinion."<sup>7</sup>

## Appropriate time to start dental treatment in post-myocardial infarction patients

Dental procedures are classified as minor surgical procedures of a low cardiovascular risk. The risk of death or myocardial infarction within 30 days of a dental procedure is less than 1%. However, a patient after a heart attack is at high risk of recurrence of cardiovascular events. Only considering patients with acute ST-elevation myocardial infarction (STEMI), the risk of in-hospital death ranges from 4% to 14% and the annual mortality after a surgical intervention is 10%.<sup>8</sup> Over 70% of relapses occur in the 1<sup>st</sup> month after the initial incident. The risk of recurrence depends on the severity of the disease, type of disease, treatment applied, and possible complications of the infarction.<sup>5</sup>

The most burdened group of patients are those treated conservatively – currently only a small number, due to the pressure of cardiac society guidelines pertaining to early invasive treatment. In these cases, the natural course of the disease lasts for more than 6 weeks.<sup>9</sup> This is the period needed for a post-infarction scar to form, to create collateral circulation and to restore the contractility of the damaged (but not necrotic) areas of the myocardium. To avoid late infarction complications, all procedures excluding emergency treatment should be avoided in this period. This also applies to dental surgery. Former AHA guidelines extended this period to 6 months, during which avoiding dental surgery was recommended, as the risk of complications was considered the highest in this period.<sup>10</sup>

Due to advances in cardiac management in the last 2 decades, these limitations are no longer recommended. Firstly, there is widespread access to the invasive methods of treatment of infarctions, allowing the immediate reperfusion of tissues, thus avoiding early and late complications. In addition, on the 2<sup>nd</sup> day after myocardial infarction patients are subjected to early cardiac rehabilitation; this is continued after discharge in rehabilitation centers, where patients undergo fitness tests in the 1<sup>st</sup> month of convalescence. When the patient's test tolerance is found to be good, the risk of recurrence is considered low, and if the attending physician does not find otherwise, there are no contraindications to dental treatment.<sup>5</sup> Patients who had myocardial infarction in the past and are in a stable period of coronary heart disease do not need stress tests and can be assessed on the basis of an interview. In terms of metabolic equivalents of task (METs), efficiency at 4 METs is sufficient to qualify the patient for dental procedures.

Patients at risk of cardiac complications exceeding the benefits of dental treatment should be identified and only the most urgent conditions should be treated. However, pain and inflammation, which may be a consequence of avoiding dental treatment as a precaution against cardiac complications, are a source of endogenous catechol-

amines that burden the already damaged heart muscle, which means caution might not always be the safest solution. The priority is to cure inflammation in the oral cavity, as it can cause pain similar to angina pectoris, with the same characteristic pain radiation. In addition, painful inflammation hinders food intake and interrupts sleep, resulting in a significant reduction in the quality of life.<sup>11</sup> Endodontic treatment, conservative treatment, non-surgical periodontal treatment, or prophylactic treatment are considered procedures entailing a low risk of complications. In addition, the risk decreases in stable periods of coronary heart disease or after heart failure, when the symptoms have a constant intensity, are predictable and occur only after intense physical activity. A good determinant of the patient's condition is a lack of chest pain for 2 weeks and satisfactory test results.<sup>12</sup> Most authors recommend a cautious 4–6-week period after myocardial infarction to stabilize the disease.<sup>13</sup> During this period, the most indispensable procedures, such as extractions, the drainage of abscesses or pulpotomies can be performed in a hospital setting. After this period, unless the cardiologist recommends otherwise, complex dental treatment can be carried out.<sup>13</sup>

## Antibiotic prophylaxis in post-myocardial infarction patients

Another issue is antibiotic prophylaxis prior to treatment, associated with the risk of bacteremia in patients who have suffered myocardial infarction. Patients with angina pectoris, cardiovascular events or coronary artery bypass surgery (bypass grafts) are classified as patients at low risk of infective endocarditis, and therefore antibiotic prophylaxis is not indicated.<sup>14</sup> The same applies to stent-injected patients. Guidelines set by the Polish Dental Association and the National Antibiotic Protection Program in 2019 continue to support the 2015 guidelines of ESC on the prevention and treatment of infective endocarditis (Table 1). They recommend the use of antibiotics in a number of situations, including the presence of an artificial prosthetic valve, the presence of artificial material used to repair the valve (e.g., a mitral ring) and cyanotic congenital heart disease. In the cases of congenital heart defects repaired with artificial material, prophylaxis is recommended for 6 months after surgery, or permanently if the defect has not been completely corrected and there is intracardiac leakage. The guidelines do not include a history of myocardial infarction or bypass surgery as posing an increased risk of infection. They limit high-risk dental procedures to those in which the continuity of the mucous membranes is disrupted and the risk of injury to the gingival or periapical area is present. Such procedures require antibiotic prophylaxis only in selected cases mentioned above.<sup>15,16</sup> However, some authors recommend antibiotics in the case of invasive procedures up to 30 days after the cardiological intervention.<sup>17</sup>

Table 1. Comparison of guidelines for the antibiotic prophylaxis of endocarditis

AHA 2007 American Heart Association <sup>20</sup>	ESC 2015 European Society of Cardiology <sup>15</sup>	Polish Dental Association and National Antibiotic Protection Program 2019 <sup>16</sup>
<ul style="list-style-type: none"> <li>– patients with a prosthetic heart valve or who have had a heart valve repaired with prosthetic material</li> <li>– patients with a history of endocarditis</li> <li>– patients with a heart transplant with abnormal heart valve function</li> <li>– patients with certain congenital heart defects, including:               <ul style="list-style-type: none"> <li>• cyanotic congenital heart disease (birth defects, with oxygen levels lower than normal) that has not been fully repaired, including children who have had surgical shunts and conduits</li> <li>• a congenital heart defect that has been completely repaired with prosthetic material or a device, for the first 6 months after the repair procedure</li> <li>• repaired congenital heart disease with residual defects, such as persisting leaks or abnormal flow at or adjacent to a prosthetic patch or prosthetic device</li> </ul> </li> </ul>	<ul style="list-style-type: none"> <li>– patients with any prosthetic valve, including a transcatheter valve, or those in whom any prosthetic material was used for cardiac valve repair</li> <li>– patients with a previous episode of infective endocarditis</li> <li>– patients with congenital heart defects:               <ul style="list-style-type: none"> <li>• any type of cyanotic congenital heart defects</li> <li>• any type of congenital heart defects repaired with prosthetic material, whether placed surgically or by percutaneous techniques</li> <li>• up to 6 months after the procedure</li> <li>• lifelong if a residual shunt or valvular regurgitation remains</li> </ul> </li> </ul>	<ul style="list-style-type: none"> <li>– patients with an artificial heart valve, including those implanted percutaneously, or patients who have been treated with artificial material for valve repair</li> <li>– patients after an episode of infective endocarditis</li> <li>– patients with congenital heart disease, including:               <ul style="list-style-type: none"> <li>• patients with a congenital cyanotic heart defect</li> <li>• patients after the repair of a congenital malformation of the heart with artificial material, both during surgery and using transcatheter techniques for up to 6 months after surgery, or lifelong if residual leakage or valve regurgitation remains</li> </ul> </li> </ul>

In each case, the benefits and risks of possible antibiotic usage should be balanced. It should be noted that in post-myocardial infarction patients there may be indications for antibiotic prophylaxis resulting from other concomitant diseases.<sup>18</sup> The most important factors in the prevention of infective endocarditis are good oral hygiene and oral inflammation prophylaxis.<sup>19,20</sup>

### Rules for safe dental treatment

The basics of safe dental treatment of patients with cardiovascular diseases comprise a detailed medical history, including complaints, allergies, medications, and specialist recommendations. It is important to monitor the patient's condition and to interrupt the procedures when the patient becomes restless or cardiac problems arise. An angina attack can occur in the dental chair due to stress, pain and anxiety triggers.<sup>3</sup> Pain can be felt in the jaw, from where it can radiate to the neck and throat, so in some cases, the patient and the dentist may interpret it as toothache. If the patient experiences retrosternal pain, the procedure should be interrupted, and sublingual nitroglycerin (0.4–0.8 mg) and oxygen (3L/min) should be administered. If the pain subsides within 5 min, the appointment can be continued or postponed to the next day. If the pain persists after 5 min, nitrates should be given again. If there is no improvement after 15 min since the first symptoms occurred, a re-infarction should be suspected, and in this situation the patient should be transferred as soon as possible to an emergency department.<sup>5</sup>

Psychological and physiological stress during dental appointments has the potential to significantly alter hemodynamic stability. Therefore, a stress-reduction protocol is suggested for post-myocardial infarction patients, including profound local anesthesia, preoperative or intraoperative sedation and excellent post-operative analgesia.<sup>21</sup> The dental visit should be short – up to 30 min – and in the middle of the day. Morning hours, with the highest

incidence of myocardial infarction, and late afternoon hours, when fatigue and stress levels are high, should be avoided.

During dental procedures, a supine position should be avoided, as it leads to the return of blood from peripheral areas to the central circulation system and may overload pulmonary circulation. In cases of systolic heart failure following myocardial infarction, this overload may result in the aggravation of heart failure, including pulmonary edema after re-verticalization, and further contribute to orthostatic syncope.<sup>8</sup> The patient should continue to take the medication before the appointment as directed by the attending physician. If the patient's regular therapy includes nitrates, the patient should bring them. In cases of anxiety disorders and stress, the administration of 5–10 mg of diazepam is recommended the night prior to the visit and 1–2 h before the treatment. In this case, the patient should not drive a motor vehicle.<sup>5</sup>

### Local anesthesia in post-myocardial infarction patients

Another important aspect of dental treatment is local anesthesia. If the patient's condition is stable and the medication is taken as prescribed, there are no contraindications for local anesthesia with adrenaline. Patients with ischemic heart disease are more vulnerable to the negative effects of the release of endogenous adrenaline as a result of severe pain during surgery than they are to a small amount of adrenaline in an anesthetic.<sup>22</sup> A visit to the dental office is a stressful event, meaning the level of endogenous catecholamines increases more than after the administration of anesthesia.<sup>23</sup> The level of endogenous adrenaline is naturally the highest between 8 and 11 a.m., so the visits should not be in the morning.<sup>9</sup> Vanderheyden et al. showed that the highest increase in the level of adrenaline is associated with the beginning of the visit and the treatment itself.<sup>24</sup> However,

during the administration of anesthesia and immediately after the injection, increases in adrenaline levels were not observed.<sup>24</sup> This means that most of the adrenaline is of endogenous origin, hence the reduction of stress and good, effective anesthesia are indicated. Moreover, local anesthetics without vasoconstrictors do not provide satisfactory hemostasis or anesthesia during dental procedures.<sup>25</sup> However, it is recommended not to exceed 0.04 mg of adrenaline, which corresponds to 2 1.8-cc cartridges of an anesthetic with adrenaline at a dilution of 1:100,000.<sup>14</sup> If it is necessary to administer more anesthesia, subsequent portions should be administered without a vasoconstrictor. Intravascular anesthesia should be avoided.<sup>4</sup> The use of intrapulpal and intraosseous anesthesia is contraindicated, as this could lead to the excessive absorption of adrenaline.<sup>9</sup> For this reason, retraction cords impregnated with adrenaline should be avoided. However, in the case of untreated, unregulated arrhythmias or unstable angina, vasoconstrictor substances are contraindicated. Similarly, caution with the use of vasoconstrictors is indicated in patients with pacemakers, especially implantable automatic defibrillators.<sup>23</sup> Elad et al. showed that local anesthesia using 4% articaine hydrochloride with adrenalin 1:200,000 is as safe as local anesthesia with 2% lidocaine and adrenalin 1:100,000 in cardiovascular patients.<sup>26</sup> They observed neither severe adverse effects nor cardiac ischemic changes on electrocardiography (ECG) in either group.<sup>26</sup>

## Hemostasis in post-myocardial infarction patients

Today the risk of complications of dental procedures is dependent more on the anticoagulant therapy used than on the severity of coronary heart disease. Patients who have had acute myocardial infarction always take medications that affect hemostasis.<sup>27</sup> Depending on the indications, these are either antiplatelet drugs, vitamin K antagonists or new non-vitamin K antagonist oral anticoagulants (NOACs). The discontinuation of therapy with these drugs is associated with a high risk of complications, including death. This risk far exceeds the risk of increased bleeding during and after surgery. In addition, a surgical intervention itself increases the risk of deep vein thrombosis. Double antiplatelet therapy (DAPT) is aimed at preventing thrombosis in the coronary artery. The risk of thrombosis lasts until the atherosclerotic plaque stabilizes (a process taking about 4–6 weeks) or – in the case of stent implantation – until it is covered with the vascular endothelium (the conventional limit for metal stents is 1 month, and for coated stents 6–12 months). Double antiplatelet therapy includes acetylsalicylic acid (ASA) and an inhibitor of the P2Y12 glycoprotein receptor (clopidogrel, prasugrel or ticagrelor) (Table 2).<sup>28</sup> In cases when there is also a risk of cardiac embolism (atrial fibrillation, intracardiac thrombus) or concomitant venous thromboembolism, DAPT treatment is supplemented with an oral anticoagulant.<sup>28</sup>

**Table 2.** Recommendations for patients receiving drugs that affect hemostasis depending on the risk of excessive bleeding after dental procedures<sup>28</sup>

Risk of bleeding in dental procedures	Patients on ASA and/or clopidogrel	Patients on oral anticoagulants	Patients on NOACs
Low risk of excessive bleeding: 1. conservative and endodontic treatment; 2. supragingival scaling; 3. periodontal pocket probing; 4. air polishing; 5. extraction of 1 tooth or teeth that are loose; 6. single implant placement; 7. laser evaporation of oral mucosa lesions.	continue therapy without any changes	check if INR < 3	continue therapy without any changes
Moderate risk of excessive bleeding: 1. subgingival scaling; 2. root debridement; 3. frenulectomy; 4. periodontal flap surgery; 5. guided tissue regeneration; 6. tooth extraction with flap elevation; 7. extraction of impacted teeth; 8. root resection; 9. vestibuloplasty; 10. several implant placement; 11. closed sinus lift procedure; 12. excisional or incisional biopsy.	continue therapy without any changes	check if INR < 3	stop therapy with rivaroxaban – 24 h before surgery, and with dabigartan – 1–2 days before surgery  restart therapy 24–48 h after surgery
High risk of excessive bleeding: 1. soft tissue augmentation with free gingival grafts or connective tissue grafts; 2. placement of 6–8 implants in the edentulous alveolar ridge; 3. bilateral open sinus lift procedure; 4. oncological, orthognathic and reconstructive surgery.	continue therapy with ASA stop therapy with P2Y12 inhibitors 24–72 h before surgery in patients at high risk of thrombosis, consider glycoprotein IIa/IIIa inhibitors	check if INR = 2–2.5 convert to heparin only in selected cases	stop therapy with rivaroxaban – 24 h before surgery, and with dabigartan – 1–2 days before surgery  restart therapy 24–48 h after surgery

ASA – acetylsalicylic acid; NOACs – non-vitamin K antagonist oral anticoagulants.



Coronary angiography is routinely performed in patients with acute coronary syndrome, and if the coronary artery responsible for myocardial infarction is identified, a revascularization procedure is performed. Coronary angioplasty is the most common one, with the implantation of an anti-proliferative eluting stent, coated with a cytostatic agent that inhibits cell division. This limits the inflammatory process and the formation of restenosis in the vessel, but at the same time slows down the epithelialization of the stent and prolongs the need for DAPT. New drug-eluting stents require the use of 2 antiplatelet drugs for about 6 months, or 12 months if they are implanted due to acute coronary syndrome. This is a conventional time period to allow the vascular endothelium to grow. The earlier discontinuation of therapy may result in acute thrombosis in the stent, myocardial infarction and death. In exceptional situations, metal stents are used; their epithelialization takes 1 month.<sup>28</sup>

The time limits for DAPT were modified by the ESC guidelines published in 2017.<sup>28</sup> Two scales were created to establish a safe date for ending the treatment. The PRECISE-DAPT score is used for stent implantation based on the results of laboratory tests (hemoglobin, leukocytes, creatinine clearance) and the patient's data (age, history of bleeding), and indicates either a brief (3–6 months) or extended (12–24 months) use of DAPT. Longer therapy may be beneficial and may lower the risk of stent closing. However, the duration of therapy depends on individual factors (e.g., age, comorbidities, left ventricular ejection fraction (LVEF), bleeding risk, or smoking) as well as on the procedure technique (implanted stent caliber, type of substance released, presence of a stent in the vein bridge).<sup>28,29</sup>

In 2016, Pruszczyk et al. published (in Polish) a paper detailing a protocol for preparing patients on anticoagulants for dental surgical procedures.<sup>30</sup> It follows the guidelines set out by ESC and the European Association for Cardio-Thoracic Surgery (EACTS).<sup>28</sup> Most dental procedures are defined as low-risk in terms of blood loss, and hemostasis can be achieved through the use of local hemostatic agents. There is a greater risk of blood loss associated with major reconstructive procedures, bone block transplants, implantological procedures, extractions of more than 3 teeth, treatment with the elevation of the mucoperiosteal flap, soft tissue augmentation procedures, connective tissue grafts, and open sinus lift procedures. The 4 criteria for abundant post-operative bleeding are: bleeding lasting longer than 12 h, forcing the patient to report to the dental office or the emergency room, hematoma or bruising, and need for a blood transfusion.<sup>30</sup>

The effect of antiplatelet therapy may double the bleeding time, but in most cases, it remains within the normal range or only slightly over it.<sup>30</sup> The results of the platelet aggregation test might be abnormal, although without clinical consequences.<sup>31</sup> Prolonged bleeding time is not a major clinical problem, since hemostasis can be

achieved by pressure, suturing, applying collagen sponges, or prescribing tranexamic acid. As mentioned above, the discontinuation of antiplatelet therapy is the main cause of late stent thrombosis, which can result in serious complications, including death (in up to 45% of cases) and significant damage to the heart.<sup>32</sup> The safety of surgical dental procedures during antiplatelet therapy was confirmed by Park et al.<sup>33</sup> Among 100 patients undergoing combined antiplatelet therapy with ASA, clopidogrel and, in some cases, with the addition of cilostazol, only 2 patients had increased post-operative bleeding after tooth extraction and in both, it was enough to apply pressure to stop the bleeding.<sup>31</sup> Dodson demonstrated that the amount of bleeding measured during invasive procedures was similar in the group of patients who suspended their ASA therapy for 7 days before tooth extraction and in patients who continued their ASA therapy.<sup>32</sup> However, Buhatem Medeiros et al. showed that patients on DAPT presented a larger volume of bleeding during invasive procedures than patients not using these medications.<sup>34</sup> Local hemostatic methods were sufficient to control the bleeding and there were no post-operative bleeding complications in any of the presented cases.<sup>34</sup> When in doubt, it is recommended to check prothrombin time (PT), partial thromboplastin time (PTT) and the number of platelets. If PT and PTT are found to be within the normal range and the number of platelets exceeds 100,000/mm<sup>3</sup>, surgery can safely be performed.<sup>31</sup> In more complicated surgical procedures with a moderate bleeding risk, patients should be maintained on aspirin, while P2Y12 inhibitor therapy should be discontinued.<sup>30</sup>

Vitamin K antagonists warfarin and acenocoumarol are used in conditions associated with coronary heart disease, including the prophylaxis of venous thromboembolism, and in patients with arrhythmias, artificial valves, thrombophilia, and antiphospholipid syndrome.<sup>35,36</sup> In these cases, the administration of vitamin K antagonists should not be stopped before any dental procedures – including procedures of a higher risk of bleeding – if the patient's international normalized ratio (INR) <3 24 h before the planned procedure.<sup>34</sup> If the patient's INR > 3, the attending physician should adjust the therapy to achieve a lower INR.<sup>30</sup> The withdrawal of oral anticoagulants does not guarantee that bleeding will not occur; serious bleeding occurs also in patients who have never taken anticoagulants. Only 0–3.5% of cases of excessive bleeding are so severe that they cannot be controlled with local measures. A higher risk of death or permanent disability is associated with the discontinuation of anticoagulant treatment. In a relapse of venous thromboembolism, the risk of death is 6% and of permanent disability 2%. In the case of arterial embolism, the former risk is 20% and the latter 40%.<sup>37</sup> It should be emphasized that there is no description in the literature of any case of death or permanent disability resulting from massive bleeding after a dental procedure in a patient taking anticoagulants. It should be borne in

mind that during anticoagulant therapy, the administration of tetracyclines, erythromycin, clarithromycin, and metronidazole is contraindicated.<sup>9</sup>

Newer anticoagulants are direct inhibitors of factor Xa – rivaroxaban, apixaban and edoxaban, and direct thrombin inhibitor dabigatran. They are used in deep vein thrombosis, pulmonary embolism, embolism due to non-valvular atrial fibrillation, following orthopedic surgery as well as in acute coronary syndrome and venous thromboembolism. There are no unambiguous guidelines of how to proceed with the use of these drugs in planned surgical procedures. The manufacturers of these drugs recommend a break of 1 day in pharmacotherapy, extended to 2 days in cases of impaired renal function with glomerular filtration rate (GFR) lowering to 30 mL/min/1.73 m<sup>2</sup>. It is recommended that the procedure should be performed when the drug concentration is the lowest, i.e., 12 h or 24 h after the last dose, depending on whether the drugs are taken once or twice daily. If procedures of a high risk of bleeding are planned and the medications are taken in the morning, the dose of the drug used once a day (edoxaban) should be delayed until after the procedure, whereas in the case of the drugs taken twice daily (apixaban, dabigatran and rivaroxaban), the evening dose should be skipped. If edoxaban is taken in the evening, there is no need to skip the dose. If complete hemostasis is obtained during the procedure, the dose that was previously skipped can be taken after 6–8 h.<sup>37</sup> In patients taking medications affecting hemostasis, it is recommended that dental procedures should be performed early enough during the day to allow the patient to seek help in case of prolonged bleeding. Likewise, treatment should be carried out at the beginning of the week, as re-bleeding usually takes place after 24–48 h.<sup>38</sup> The use of an infiltration anesthetic with a vasoconstrictor is recommended and nerve block anesthesia should be avoided if possible. If nerve block anesthesia is necessary, it should always be performed with aspiration.

Following an extraction, the tooth socket should be provided with a hemostatic dressing and sutured well for 7–14 days, and gauze pad compression should be maintained for 30 min after treatment.<sup>36</sup> The patient should be advised not to rinse their mouth for 24 h, not to perform suction or create negative pressure in the mouth, not to touch the alveolus with the tongue or any foreign body, to avoid hot and hard food, and not to bite on the side of the procedure. The patient should be advised to apply pressure for 20 min with a clean gauze pad in case of bleeding, and contact the dentist if hemostasis does not occur.<sup>30,38</sup>


## Conclusions


Patients who have suffered a heart attack often require dental treatment. The inflammation of the oral cavity not only reduces the quality of life, but can also contribute to the deterioration of the course of ischemic heart disease. In most cases, dental treatment can be under-

taken 6 weeks after myocardial infarction. It is important to eliminate pain, so local anesthesia with a vasodilator in a dose not exceeding 0.04 mg should be used. Antibiotic prophylaxis is usually not required. Visits should be short and carried out in the early afternoon. The patient should be in a comfortable sitting position. If the patient complains of retrosternal pain, the procedure should be discontinued, and oxygen and nitrates should be administered. If there is no improvement, a re-infarction should be suspected and an ambulance should be called immediately. In the vast majority of cases, antiplatelet drugs and anticoagulants should not be discontinued prior to planned surgery, since there is a significantly higher risk of thromboembolism than of increased bleeding in these patients. In case of any doubts as to the patient's health and the possibility of dental treatment, the patient should be referred to a specialist to establish an individualized treatment plan.

## ORCID iDs

Renata Samulak-Zielińska  <https://orcid.org/0000-0003-0145-9131>

Elżbieta Dembowska  <https://orcid.org/0000-0002-3646-1314>

Piotr Lizakowski  <https://orcid.org/0000-0001-5648-2027>

## References

- Bhateja S. High prevalence of cardiovascular diseases among other medically compromised conditions in dental patients: A retrospective study. *J Cardiovasc Dis Res.* 2012;3(2):113–116.
- Włosowicz M, Wozakowska-Kapłon B, Górka R. Periodontitis in relation to selected parameters of cardiovascular system in the group of patients with acute myocardial infarction [in Polish]. *Czas Stomatol.* 2012;65(5):636–653.
- Chaudhry S, Jaiswal R, Sachdeva S. Dental considerations in cardiovascular patients: A practical perspective. *Indian Heart J.* 2016;68(4):572–575.
- Kebschull M, Demmer RT, Papapanou PN. “Gum bug, leave my heart alone!” – epidemiologic and mechanistic evidence linking periodontal infections and atherosclerosis. *J Dent Res.* 2010;89(9):879–902.
- Cruz-Pamplona M, Jimenez-Soriano Y, Sarrión-Pérez MG. Dental considerations in patients with heart disease. *J Clin Exp Dent.* 2011;3(2):e97–e105.
- Górski B, Włosowicz M, Dembowska E, Kręgielczak A, Górka R. More than 40% patients after cardiac infarct require immediate application of specialist periodontal treatment [in Polish]. *Magazyn Stomatol.* 2014;24(1):95–98.
- Napeñas JJ, Kujan O, Arduino PG, et al. World Workshop on Oral Medicine VI: Controversies regarding dental management of medically complex patients: Assessment of current recommendations. *Oral Surg Oral Med Oral Pathol Oral Radiol.* 2015;120(2):207–226.
- Pedersen F, Butrymovich V, Kelbæk H, et al. Short- and long-term cause of death in patients treated with primary PCI for STEMI. *J Am Coll Cardiol.* 2014;64(20):2101–2108.
- Thygesen K, Alpert JS, Jaffe AS, Simoons ML, Chaitman BR, White HD. Third universal definition of myocardial infarction. *Circulation.* 2012;126(16):2020–2035.
- Research, Science and Therapy Committee, American Academy of Periodontology. Periodontal management of patients with cardiovascular diseases. *J Periodontol.* 2002;73(8):954–968.
- Niwa H, Sato Y, Matsuura H. Safety of dental treatment in patients with previously diagnosed acute myocardial infarction or unstable angina pectoris. *Oral Surg Oral Med Oral Pathol Oral Radiol Endod.* 2000;89(1):35–41.
- Roberts HW, Mitnitsky EF. Cardiac risk stratification for postmyocardial infarction dental patients. *Oral Surg Oral Med Oral Pathol Oral Radiol Endod.* 2001;91(6):676–681.

13. Silvestre FJ, Miralles-Jorda L, Tamarit C, Gascon R. Dental management of the patient with ischemic heart disease: An update. *Med Oral*. 2002;7(3):222–230.
14. Napora M. Antibiotics prophylaxis for patients at high risk of infective endocarditis [in Polish]. *Nowa Stomatol*. 2008;13(1):24–26.
15. Habib G, Lancellotti P, Antunes MJ, et al. ESC guidelines for the treatment of infective endocarditis in 2015 [in Polish]. *Kardiol Pol*. 2015;73(11):963–1027.
16. Kaczmarzyk T, Babiuch K, Bołtacz-Rzepkowska E, et al. *Rekomendacje Grupy Roboczej Polskiego Towarzystwa Stomatologicznego i Narodowego Programu Ochrony Antybiotyków w zakresie stosowania antybiotyków w stomatologii*. Warsaw, Poland: Narodowy Instytut Leków; 2019.
17. Roberts HW, Redding SW. Coronary artery stents: Review and patient-management recommendations. *J Am Dent Assoc*. 2000;131(6):797–801.
18. AAE Quick Reference Guide: Antibiotic Prophylaxis 2017 Update. [https://www.aae.org/specialty/wp-content/uploads/sites/2/2017/06/aae\\_antibiotic-prophylaxis-2017update.pdf](https://www.aae.org/specialty/wp-content/uploads/sites/2/2017/06/aae_antibiotic-prophylaxis-2017update.pdf)
19. Kaura A, Dworakowska D, Dworakowski R. Infective endocarditis – Cinderella in cardiology. *Kardiol Pol*. 2017;75(10):965–974.
20. Wilson W, Taubert KA, Gewitz M, et al.; American Heart Association Rheumatic Fever, Endocarditis, and Kawasaki Disease Committee; American Heart Association Council on Cardiovascular Disease in the Young; American Heart Association Council on Clinical Cardiology; American Heart Association Council on Cardiovascular Surgery and Anesthesia; Quality of Care and Outcomes Research Interdisciplinary Working Group. Prevention of infective endocarditis: Guidelines from the American Heart Association: A guideline from the American Heart Association Rheumatic Fever, Endocarditis, and Kawasaki Disease Committee, Council on Cardiovascular Disease in the Young, and the Council on Clinical Cardiology, Council on Cardiovascular Surgery and Anesthesia, and the Quality of Care and Outcomes Research Interdisciplinary Working Group. *Circulation*. 2007;116(15):1736–1754.
21. Rose LF, Mealey B, Minsk L, Cohen DW. Oral care for patients with cardiovascular disease and stroke. *J Am Dent Assoc*. 2002;133(Suppl):375–445.
22. Laragnoit AB, Neves RS, Neves ILI, Vieira JE. Locoregional anesthesia for dental treatment in cardiac patients: A comparative study of 2% plain lidocaine and 2% lidocaine with epinephrine (1:100,000). *Clinics (Sao Paulo)*. 2009;64(3):177–182.
23. Margaix Muñoz M, Jiménez Soriano Y, Poveda Roda R, Sarrión G. Cardiovascular diseases in dental practice. Practical considerations. *Med Oral Pathol Oral Cir Bucal*. 2008;13(5):E296–E302.
24. Vanderheyden PJ, Williams RA, Sims TN. Assessment of ST segment depression in patients with cardiac disease after local anesthesia. *J Am Dent Assoc*. 1989;119(3):407–412.
25. Daskalov H, Dinkova A, Drangov M. Local anesthetics in patients with cardiovascular diseases. *J of IMAB*. 2015;21(1):728–731.
26. Elad S, Admon D, Kedmi M, et al. The cardiovascular effect of local anesthesia with articaine plus 1:200,000 adrenalin versus lidocaine plus 1:100,000 adrenalin in medically compromised cardiac patients: A prospective, randomized, double-blinded study. *Oral Surg Oral Med Oral Pathol Oral Radiol Endod*. 2008;105(6):725–730.
27. Skaar D, O'Connor H, Lunos S, Luepker R, Michalowicz BS. Dental procedures and risk of experiencing a second vascular event in a Medicare population. *J Am Dent Assoc*. 2012;143(11):1190–1198.
28. Valgimigli M, Bueno H, Byrne RA, et al.; ESC Scientific Document Group; ESC Committee for Practice Guidelines (CPG); ESC National Cardiac Societies. 2017 ESC focused update on dual antiplatelet therapy in coronary artery disease developed in collaboration with EACTS: The Task Force for dual antiplatelet therapy in coronary artery disease of the European Society of Cardiology (ESC) and of the European Association for Cardio-Thoracic Surgery (EACTS). *Eur Heart J*. 2018;39(3):213–260.
29. Levine GN, Bates ER, Bittl JA, et al. 2016 ACC/AHA guideline focused update on duration of dual antiplatelet therapy in patients with coronary artery disease: A report of the American College of Cardiology/American Heart Association Task Force on Clinical Practice Guidelines. *J Thorac Cardiovasc Surg*. 2016;152(5):1243–1275.
30. Pruszczyk P, Ciużyński M, Opolski G, et al. Dental cardio common position for dealing anticoagulation in patients undergoing dental procedures [in Polish]. *Kardiol Pol*. 2016;74(1):87–98.
31. Gziut Al. Late in-stent thrombosis as a cause of acute coronary syndrome complicated by out-of-hospital cardiac arrest [in Polish]. *Kardiol Pol*. 2008;66(6):697–699.
32. Dodson T. Should acetylsalicylic acid (ASA) therapy for prevention of thromboembolic events be stopped prior to surgical extractions? *Evid Based Dent*. 2012;13(3):89–90.
33. Park MW, Her SH, Kwon JB, et al. Safety of dental extractions in coronary drug-eluting stenting patients without stopping multiple antiplatelet agents. *Clin Cardiol*. 2012;35(4):225–230.
34. Buhatem Medeiros F, Pepe Medeiros de Rezende N, Bertoldi Franco J, et al. Quantification of bleeding during dental extraction in patients on dual antiplatelet therapy. *Int J Oral Maxillofac Surg*. 2017;46(9):1151–1157.
35. Singh S, Gupta K, Garg KN, Fuloria NK, Fuloria S, Jain T. Dental management of the cardiovascular compromised patient: A clinical approach. *J Young Pharm*. 2017;9(4):453–456.
36. Milczarek S, Smektała T, Jędrzejewski M, Szyndel J, Sporniak-Tutak K. Dental procedures in patients with coexistent blood clotting disorder or arterial hypertension. Pt 2. Procedure with patients taking oral anticoagulants or modern anticoagulants [in Polish]. *Magazyn Stomatol*. 2013;23(12):116–118.
37. Pototski M, Amenábar JM. Dental management of patients receiving anticoagulation or antiplatelet treatment. *J Oral Sci*. 2007;49(4):253–258.
38. Dézsi CA, Dézsi BB, Dézsi AD. Management of dental patients receiving antiplatelet therapy or chronic oral anticoagulation: A review of the latest evidence. *Eur J Gen Pract*. 2017;23(1):196–201.

# Clinicians' role in the occurrence of oral biopsy artifacts as a potential diagnostic dilemma

## Rola lekarzy klinicyków w powstawaniu artefaktów w badaniu histopatologicznym jamy ustnej jako możliwy dylemat diagnostyczny

Massoumeh Zargaran<sup>A-F</sup>

Department of Oral and Maxillofacial Pathology, Faculty of Dentistry, Kurdistan University of Medical Sciences, Sanandaj, Iran

A – research concept and design; B – collection and/or assembly of data; C – data analysis and interpretation; D – writing the article; E – critical revision of the article; F – final approval of the article

Dental and Medical Problems, ISSN 1644-387X (print), ISSN 2300-9020 (online)

*Dent Med Probl.* 2019;56(3):299–306

### Address for correspondence

Massoumeh Zargaran  
E-mail: massoumehzargaran@gmail.com

### Funding sources

None declared

### Conflict of interest

None declared

Received on February 11, 2019

Reviewed on March 11, 2019

Accepted on April 17, 2019

Published online on September 30, 2019

### Abstract

A lack of knowledge about biopsy techniques and the management of biopsy specimens can cause artifacts. Artifacts are false structures that change the normal morphological and cytological features of tissues. This review article aimed to familiarize clinicians / dentists / surgeons with the factors causing artifacts and with the efficient strategies to prevent or minimize their occurrence. Non-adherence to several rules can result in the formation of artifacts. The clinician's performance during and after the surgical procedure (until the sample is received by the laboratory) may damage the biopsy specimen or make it susceptible to damage. Artifacts may not be clinically considered noteworthy. However, by modifying the histopathological features of the specimen, they can lead to serious errors in the interpretation of lesions. Knowledge on the part of clinicians / dentists / surgeons regarding the factors and potential conditions that can lead to artifacts can decrease the risk of their occurrence, and considerably help pathologists and patients by paving the way for a correct diagnosis, and consequently an appropriate treatment plan.

**Key words:** biopsy, dentist, artifact, oral lesion

**Słowa kluczowe:** biopsja, dentysta, artefakt, zmiana patologiczna w jamie ustnej

### Cite as

Zargaran M. Clinicians' role in the occurrence of oral biopsy artifacts as a potential diagnostic dilemma. *Dent Med Probl.* 2019;56(3):299–306. doi:10.17219/dmp/108597

### DOI

10.17219/dmp/108597

### Copyright

© 2019 by Wrocław Medical University

This is an article distributed under the terms of the

Creative Commons Attribution 3.0 Unported License (CC BY 3.0)

(<https://creativecommons.org/licenses/by/3.0/>)

## Introduction

The detection of oral lesions by dentists is highly important,<sup>1,2</sup> because in many diseases or conditions, oral lesions manifest themselves sooner than cutaneous lesions.<sup>3</sup> This can help in an early diagnosis and the subsequent management of the disease in its initial stages.<sup>3</sup> The clinical diagnosis of lesions is confirmed with different techniques.<sup>1</sup> The gold standard of diagnostic procedures is biopsy.<sup>4–6</sup> Biopsy is defined as taking a sample of a living organism,<sup>4,5,7</sup> which can include the entire lesion or a part of it.<sup>5,8</sup> Biopsy is performed to allow a histopathological analysis of the specimen under a microscope to make a definite diagnosis.<sup>9,10</sup> This assessment is important for the diagnosis of the lesion and also to determine the presence/absence of evidence of malignancy. Biopsy provides information about the clinical course of the lesion and may even provide prognostic data. All these can directly affect the patient management.<sup>11,12</sup>

Nonetheless, in some cases, dentists fail to send tissue specimens to histopathological laboratories and explain that they are concerned about the risk of misdiagnosing the lesion.<sup>12</sup>

One challenge in the correct interpretation of histopathological sections is the presence of defects not related to the existing disease.<sup>13,14</sup> In microscopic analysis, such defects can create manifestations that are not necessarily related to the actual histological/histopathological features of the specimen.<sup>13</sup> These defects are known as artifacts.<sup>13</sup> The term ‘artifact’ is derived from 2 Latin terms: ‘ars’ and ‘factum’, and is defined as a false or altered tissue structure in a microscopic feature as a result of some external factors.<sup>5</sup> Artifacts are illusive structures, although they can be misinterpreted as real ones.<sup>13</sup> Artifacts can interfere with the histopathological assessment of the specimen<sup>6</sup> and affect the pathologist’s ability to correctly diagnose lesions, especially in small samples.<sup>12</sup> They also compromise the correct histopathological interpretation of specimens, especially at the margins.<sup>15</sup>

Biopsy is a simple, minor surgical procedure.<sup>16,17</sup> However, achieving an accurate and correct diagnosis requires more than just a correct surgical technique.<sup>18,19</sup> Suitable tissue preparation for microscopic analysis depends on the correct performance of the dentist/surgeon, assistant and lab staff to minimize the risk of artifact occurrence.<sup>19</sup>

Biopsy (taking a tissue sample) comprises 6 steps: selection of the biopsy site, preparation of the surgical field, anesthetic injection, incision, handling of the biopsy sample, and suturing of the surgical wound.<sup>20</sup> The processing of the tissue sample is a long process, from surgical removal to staining and mounting the tissue sections on the slides. Artifacts may occur at any step, from the time of performing biopsy to the final step of mounting.<sup>13</sup> It is imperative for clinicians / dentists / surgeons to have adequate knowledge about artifacts<sup>5</sup> and this study is aimed to familiarize them with tissue artifacts. This review article discusses the causes of artifacts during surgery, the fixation and transfer of the samples to the lab in order to find strategies to minimize their occurrence.

## Preoperative surgical artifacts

Artifacts can change the normal morphological and cytological appearance of the biopsied samples.<sup>5,21</sup> They may be confined to only a small portion of the sample. As such, they can be easily detected by an experienced pathologist and no longer interfere with an accurate pathology report and a correct diagnosis.<sup>5</sup> However, in some cases, the artifactual damage may be extensive or involve the entire sample. Then, artifacts result in a suboptimal quality or quantity of the sample for diagnosis or may even render the tissue useless.<sup>21</sup>

### Artifacts caused by the surface preparation of the surgical field prior to biopsy

After the biopsy site has been precisely selected,<sup>1</sup> the preparation of the site with iodine tincture or other colored solutions should be avoided.<sup>5,22</sup> Colored antiseptics or similar agents are not recommended for disinfecting the surface or the external margins of the incision site,<sup>6</sup> since they can interfere with tissue processing and staining procedures. If they are nevertheless used, dentists must inform the lab about it.<sup>21</sup> It should be noted that toluidine blue, used to determine the most representative part of premalignant and malignant oral lesions,<sup>3,23</sup> does not interfere with the aforementioned processes.<sup>6</sup>

### Artifacts caused by injection

Injecting the anesthetic solution into the biopsy site can damage the tissue sample<sup>4,8</sup> and cause 2 major tissue changes<sup>24</sup>:

- bleeding and extravasation of red blood cells due to needle insertion into the tissue, and the subsequent possible masking of tissue structures<sup>7,24,25</sup>;
- splitting of connective tissue bands, associated with vacuolization.<sup>20,24</sup>

In a microscopic feature, the area into which the anesthetic agent has been directly injected shows artifactual tissue edema or distortion, which can lead to misdiagnosis. For instance, the formation of a bulla or artifactual edema in the gingival tissue may mistakenly lead to the diagnosis of Crohn’s disease or orofacial granulomatosis.<sup>26</sup>

Block injection is recommended to prevent artifacts. If not possible,<sup>3</sup> the site of infiltration anesthesia injection should be adequately far from the lesion.<sup>25</sup> Injection should be administered at a distance of at least 3–4 mm from the lesion and at 4 points around it (superior, inferior, right, and left).<sup>3</sup>

Excessive pressure should be avoided<sup>7</sup> and the anesthetic solution should be injected slowly.<sup>19</sup>

If achieving hemostasis is among the objectives of injection, it should be administered deeply into the lesion or postponed to immediately after the biopsy.<sup>25</sup>

## Artifacts during surgery

### Artifacts due to the use of biopsy instruments

Some cutting instruments, such as a scalpel, forceps, a punch, electrode blades/electroscalpels, and laser blades, are used to take biopsy samples.<sup>7,15,27</sup>

#### Scalpel

Biopsy samples are usually obtained using surgical scalpels.<sup>3,11</sup> This is considered a conventional method of biopsy.<sup>11,28</sup> It seems that an incision with a sharp scalpel causes less tissue damage.<sup>8,14</sup> Sharp instruments are required for biopsy.<sup>3</sup> The sample should be taken with one sharp incision.<sup>7</sup> Multiple incisions with a blunt scalpel<sup>5,8,22,28</sup> can cause a number of artifacts in the sample.<sup>28</sup> A blunt scalpel can cause squeeze artifacts,<sup>22</sup> which are a form of tissue distortion that may result from even the slightest compression of the tissue.<sup>5,20</sup> These artifacts include crush, hemorrhage, split, fragmentation,<sup>5,20</sup> or the occurrence of pseudocysts in the tissue (Fig. 1A–E).<sup>20,22</sup>

The split artifact can occur at the surface or margins of the samples taken with a scalpel (especially a blunt scalpel).<sup>5,28</sup> Several incisions made with a scalpel result in a split between the epithelium and the connective tissue (Fig. 1F).<sup>5,28</sup> The split artifact creates a false impression

of vesiculobullous lesions.<sup>5,28</sup> The crush artifact is destructive and dangerous,<sup>24</sup> and can occur even at the slightest compression of the tissue.<sup>5</sup> It changes the morphology of the tissue and squeezes chromatin out of the nucleus.<sup>24</sup> Microscopically, crushed cells appear as black chromatin strands, which may be mistaken for a dysplastic lesion.<sup>5</sup> Inflammatory and tumor cells are most susceptible to the crush artifact (Fig. 2A–C).<sup>24</sup>

#### Forceps

They also can be used to perform biopsy.<sup>7,29</sup> They facilitate the biopsy of oral soft tissues and small salivary glands. Forceps have 2 cusps and a window that allows the compaction of the target tissue between them.<sup>7</sup> The use of dentate forceps is an old technique. They firmly hold the tissue and acceptably protect it during removal.<sup>26</sup> If used inappropriately, forceps can also cause squeeze artifacts, just like blunt scalpels.<sup>5,22</sup> Forceps should never grasp the lesion,<sup>25</sup> because it can result in the crush artifact.<sup>4,8</sup> Dentate forceps can create holes in the tissue when used carelessly with great force.<sup>3,16</sup> Such holes can histologically mimic mucosal pits or an epidermoid cyst.<sup>16</sup> An inappropriate use of forceps can also result in the formation of pseudocysts in the tissue.<sup>5,16,24,25</sup> The teeth of forceps can push the superficial epithelium into the underlying connective tissue. This, along with the compression of the connective tissue, can create pseudocysts.<sup>5,24,25</sup>

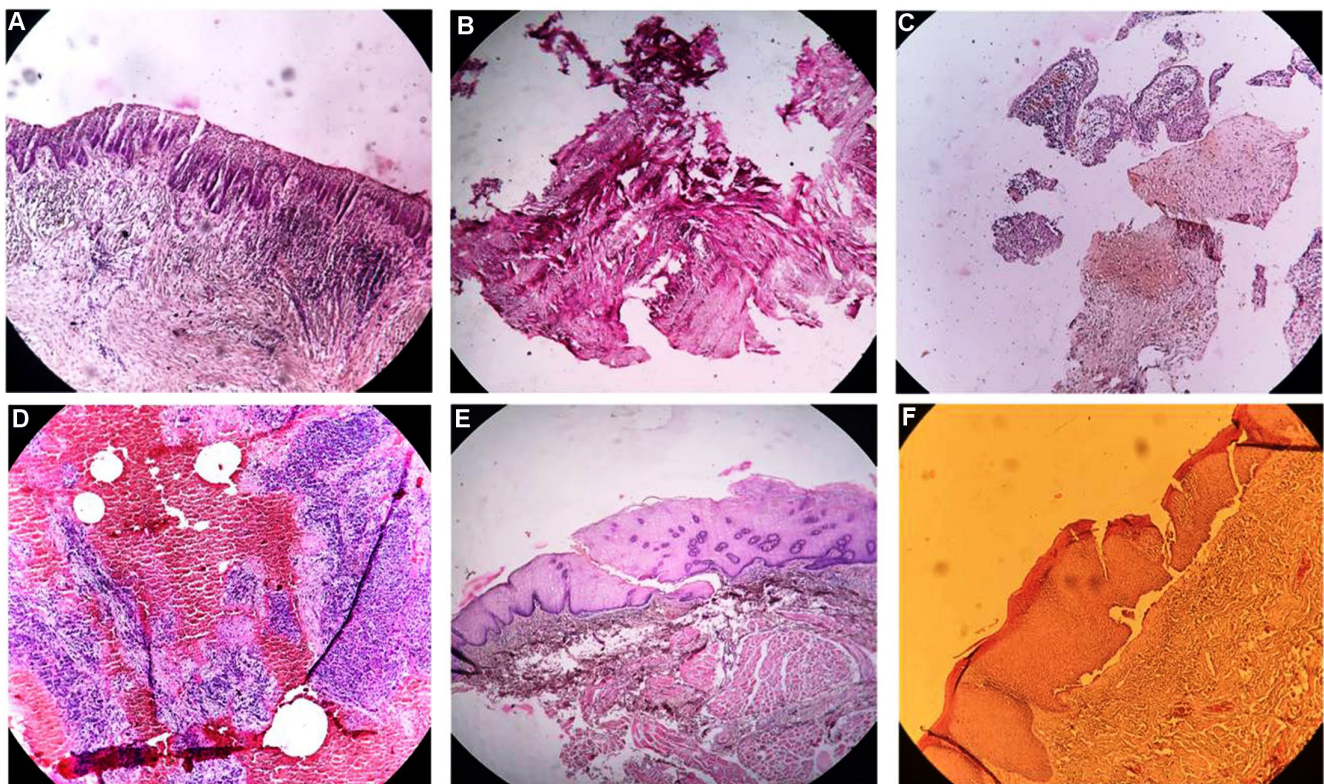


Fig. 1. A – epithelial tissue crush artifact; B – connective tissue crush artifact; C – fragmentation of the tissue sample; D – hemorrhage artifact; E – split artifact; F – split between the epithelial and connective tissues, false impression of a vesiculobullous lesion

Hematoxylin and eosin staining (H & E),  $\times 100$  original magnification.

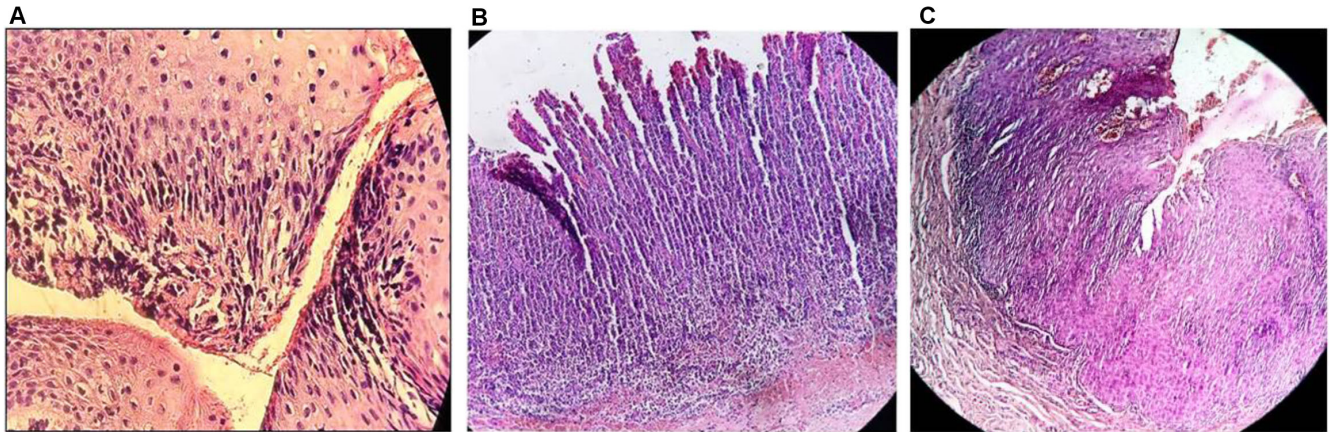


Fig. 2. A – crushed cells that microscopically mimic dysplastic features (H & E;  $\times 400$  original magnification); B – crush artifact of inflammatory cells (H & E;  $\times 100$  original magnification); C – crush artifact of tumor cells (H & E;  $\times 100$  original magnification)

These pseudocysts, which apparently line with the surface epithelium, can make the exact assessment of the sample difficult.<sup>5,24,25</sup> When the teeth of forceps perforate the tissue, they not only create voids or tears, but also compress the surrounding tissue.<sup>19,25</sup> Microscopically, the tissue appears distorted with scalloped serrations (caused by the forceps tip) and crushed cells (Fig. 3A–C).<sup>5,25</sup> The compression of the tissue eliminates its cytological details. It also changes the dimensions of the nucleus, and particularly its ratio to the cytoplasm.<sup>24,25</sup> These changes may be sufficient to complicate diagnosis<sup>16</sup> or lead to misdiagnosis.<sup>25</sup> Forceps artifacts can be overcome by the correct handling and careful use of this instrument.<sup>5</sup>

The lesion should not be directly grasped with forceps<sup>25</sup>; the grasped tissue should be acceptably far from the biopsy site.<sup>26,29</sup> Blunt forceps should be used instead of toothed forceps.<sup>13,24</sup>

Excessive force at the time of grasping should be avoided in order to prevent significant changes in the epithelium and the underlying connective tissue.<sup>25</sup>

Suturing should be performed at the sample border and used instead of forceps for tissue immobilization.<sup>24</sup>

### Punch

The use of a punch is an affordable, fast, simple, and safe technique for biopsy.<sup>7</sup> Evidence shows that it creates fewer artifacts in the tissue compared to a scalpel.<sup>13,15</sup> In punch biopsy, artifacts are in the form of tissue fragmentation, probably due to the use of scissors for separating the sample from the underlying tissue base.<sup>13</sup> It cannot be used for deep lesions and punch biopsy is limited to the epithelial or superficial mesenchymal tissues.<sup>7</sup> The use of a punch in some areas, such as the soft palate, maxillary tuberosity or floor of the mouth, is difficult due to the mobility of the site and the absence of a hard, fixed tissue.<sup>3,7</sup> The punch biopsy of freely mobile tissues<sup>3</sup> can damage the tissue and cause artifacts.<sup>3,7</sup>

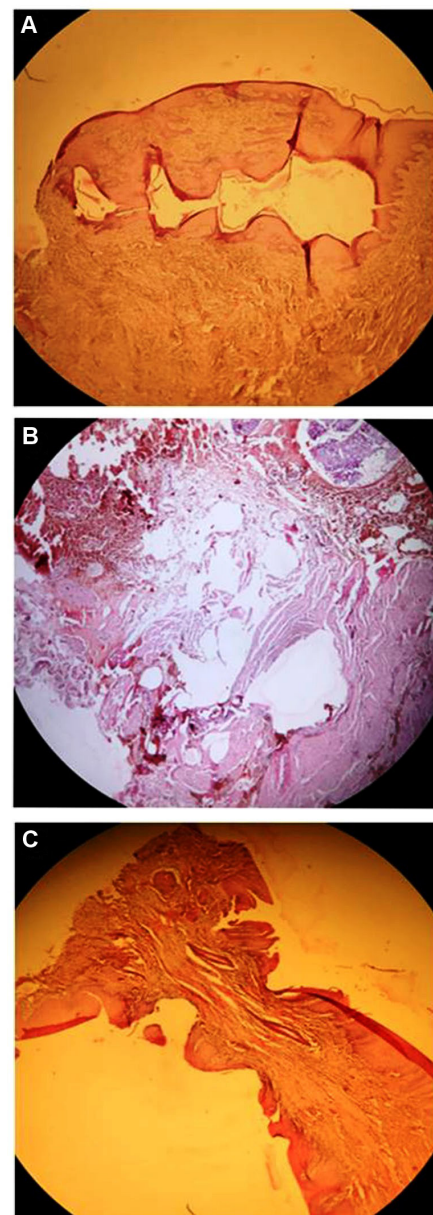


Fig. 3. Artifacts due to forceps

A – pseudocyst; B – tearing of the connective tissue; C – compression of the tissue samples; H & E;  $\times 100$  original magnification.

## Electrical cautery instruments and laser

The surgical electrical cautery instruments and laser have the advantage of causing hemostasis during surgery.<sup>3</sup> On the other hand, overheating generated by these devices can cause changes in the epithelial and connective tissues (the fulguration artifact).<sup>5,21,30</sup> In the tissue sections with the fulguration artifact, epithelial cells appear detached.<sup>24,25</sup> The nuclei of cells have a spindled, palisading shape<sup>24,25</sup> and are hyperchromatic.<sup>3</sup> These changes can mimic the presence of epithelial dysplasia and lead to an incorrect histopathology report of the lesion, especially at the margins, which are extremely important for the clinician in terms of presence/absence of dysplasia and invasion.<sup>28</sup> In the fulguration artifact, the separation of the epithelium from the basement membrane can be observed,<sup>24,25</sup> which may be associated with epithelial loss.<sup>28</sup> The underlying tissues, such as the fibrous connective tissue, fat and muscle tissues, have an opaque amorphous appearance.<sup>24,25,30</sup> Protein is deposited when the generated heat results in the boiling of the tissue fluids.<sup>24</sup> Microscopically, such a tissue has a coagulated and torn appearance.<sup>24</sup> In the lesion, particularly along the surgical margins, tissue protein coagulation in the form of a wide, extensive basophilic coagulum band is seen, giving an amorphous appearance to the epithelium and the connective tissue (Fig. 4A–C).<sup>20</sup>

To prevent this, it has been recommended that these instruments should be used according to the dysplastic potential of the lesion.<sup>31</sup> For lesions suspected of dysplasia or neoplasia, their use should be avoided or the incision margin should be sufficiently far from the interface of the lesion and the normal tissue.<sup>7,24,25,27</sup>

The use of a laser should be limited to excisional biopsy and relatively large samples, where an adequate margin is available.<sup>3,28</sup>

Low power settings of the laser should be used to effectively decrease the risk of separating the epithelium from the basement membrane and of epithelial loss during tissue processing.<sup>28</sup>

A combination of electrosurgery and scalpel should be used instead of electrosurgery alone, because the former would yield more favorable results. In this technique, a scalpel is used for the primary incision around or within the lesion, and then the lesion is completely excised using electrosurgery. This method results in optimal hemostasis and minimizes the heat exposure of the sample.<sup>7,24,25</sup>

Cutting electrodes should be used for tissue sampling rather than coagulation electrodes.<sup>19,24</sup> This is conventionally done by using low-milliampere current.<sup>5,20,24,25</sup>

The intentional or incidental contact of the tip of the cutting electrode with metal instruments used for holding the sample should be prevented, because it can cause tissue changes.<sup>24,25</sup>

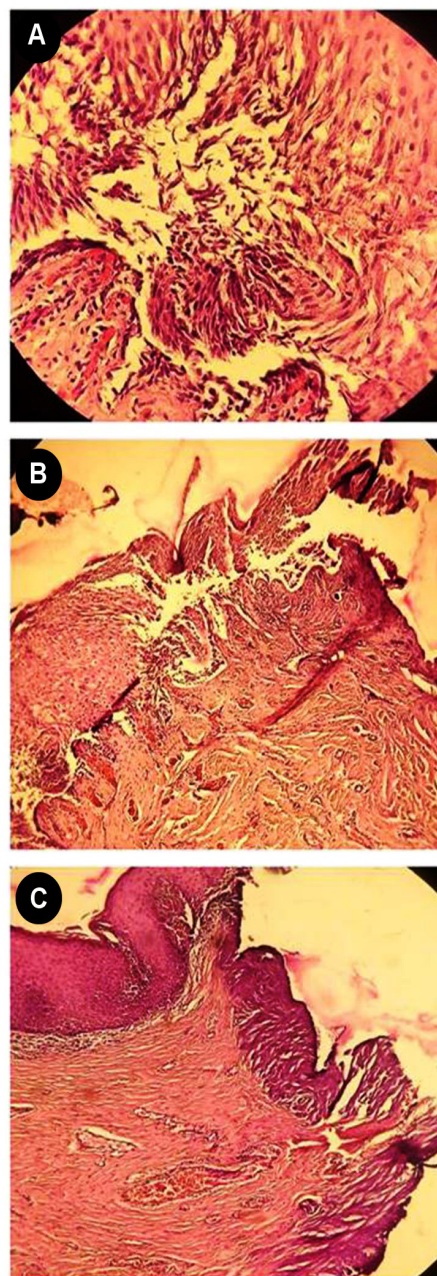


Fig. 4. Fulguration artifact

A – detached epithelium (H & E; ×400 original magnification); B – separation of the epithelium from the baseline membrane (H & E; ×100 original magnification); C – extensive basophilic coagulum band along the surgical margin (H & E; ×100 original magnification).

## Artifacts due to the improper handling of the tissue specimens

Care must be taken when handling mucosal biopsy samples, since the tissue specimen can be easily damaged. The presence of artifacts in the histopathological sections of damaged tissue can decrease their diagnostic accuracy or render them useless.<sup>26</sup> Traumatic injuries and rough handling can cause artifacts in the specimen.<sup>3,26</sup> Suturing is one common method to limit them. It enables the traction and elevation of the tissue during biopsy.<sup>26</sup>



Moreover, it prevents the unwanted movement of the tissue (especially mobile structures, such as the tongue) during the procedure.<sup>26,29</sup> They orientate at least one side of the lesion, facilitate the surgical procedure, and prevent the compression and destruction of the tissue specimen.<sup>7</sup> However, care must be taken, since the excessive traction of the tissue can cause the laceration or crushing of the specimen, and significantly damage the epithelium or connective tissue.<sup>7</sup> It can also split the epithelium from the connective tissue and mimic the appearance of vesicubullous lesions.<sup>5</sup> The forced traction of the surface epithelium against the underlying connective tissue can cause pseudocysts, and result in the loss of cytoplasmic and nuclear features.<sup>21</sup> The excessive traction can cause tissue fragmentation<sup>28</sup> and the subsequent bleeding can be interpreted as a pathologic change by an inexperienced pathologist.<sup>13</sup>

Thus, it is important:

- to handle the tissue specimen with care<sup>21,29</sup>;
- not to apply too much pressure during tissue traction with the sutures<sup>5</sup>;
- to ensure that the sutures have not been placed within the area designated for biopsy<sup>8</sup>;
- to ensure that the suture knots are loose, since firm knots can cause tissue crush<sup>26</sup> (inflammatory cells<sup>28</sup> and tumor cells are susceptible to crush artifacts, which can make the specimen uninterpretable).<sup>24</sup>

## Vacuum artifact

This type of artifact is caused by vacuuming the tissues,<sup>4</sup> especially the connective tissue around odontogenic cysts and dental follicles, with surgical suction tips. These artifacts are seen as large and mostly pleomorphic vacuoles in the connective tissue, similar to the traumatized fat tissue.<sup>19</sup>

## Artifacts due to the contamination of the specimens

Some artifacts are due to the contamination of the specimen with foreign bodies, which may occur during surgery.<sup>21,30</sup> Cotton and starch are among the most common contaminants.<sup>20</sup> Starch artifacts may occur due to the contamination of the specimen with starch powder, which is used as a lubricant in surgical gloves.<sup>5,20,21</sup> Starch granules may be superficially similar to atypical epithelial cells,<sup>5,20</sup> and mimic the appearance of salivary gland diseases, autoimmune disorders, granulomatous lesions, or benign epithelial lesions.<sup>5</sup> These spore-like structures with a dark central area could be mistaken as pyknotic nuclei or mitotic nuclei.<sup>20,21</sup> Starch granules appear light blue on hematoxylin and eosin staining (H & E), blue-black with Lugol's solution and deep lilac-red on periodic acid–Schiff staining (PAS).<sup>5,20</sup> The starch artifact can be prevented by using latex gloves.<sup>5</sup> The presence of cotton in the histopathological sections (cotton contamination) may resemble eosinophilic, amyloid-like or black

substances.<sup>5,20</sup> The similarity of cotton to an amyloid-like material, which is among the characteristics of odontogenic tumors, may result in misdiagnosis.<sup>5</sup>

To control bleeding during surgery, gel foam or surgical sponges are used.<sup>13</sup> In the histopathological sections contaminated with gel foam, the characteristic appearance of distorted superficial spaces is seen. These spaces may be filled with blood and surrounded by slightly basophilic gelatin walls.<sup>13</sup> Dentists/surgeons should be careful to prevent the foreign body contamination of the specimens.<sup>19</sup> On the other hand, knowledge about these materials and their correct identification in the sections can help in establishing an accurate pathologic interpretation.<sup>5</sup>

## Post-surgical artifacts (occurring after specimen removal until a transfer to the lab)

### Artifacts due to a delay in fixation

After tissue removal, the biopsy specimen should be fixed.<sup>5,7,17</sup> Autolysis and bacterial attack start immediately after tissue removal.<sup>19,32</sup> Fixation stops these changes.<sup>19,32,33</sup> It maintains the integrity of cells and their chemical components,<sup>34</sup> preserving the tissue in conditions like when alive.<sup>13,34</sup> The time interval between the surgical removal of the sample and its immersion in a proper fixative is referred to as the ischemia or hypoxia time,<sup>34,35</sup> which is associated with the activation of tissue enzymes, autolysis, and the degradation of proteins, DNA and RNA.<sup>34</sup> A delay in fixation yields a poor histopathologic feature.<sup>5</sup> It also changes the quality of cell staining<sup>24,25</sup> and makes mitosis hard to detect.<sup>5</sup> Cells shrink and cytoplasmic clumping is observed.<sup>7,25</sup> Chromatin in the nuclei cannot be detected and the nucleoli are not visible in some cases.<sup>5,7</sup> Some changes occur in tissue structures as well.<sup>5,7,25</sup> Vascular, nervous and gland structures lose their details,<sup>5,7,25</sup> simulating scar tissue formation<sup>25</sup> or the loss of cellularity.<sup>5,7,25</sup> To prevent the occurrence of these changes, the biopsy samples should be placed in a suitable fixative immediately after removal.<sup>19,36</sup>

### Artifacts due to the type of fixative used

The 10% neutral buffered formalin is an alternative fixative to optimize the fixation of the biopsy specimen for the routine histopathological assessment.<sup>12,24,36</sup> Despite attempts to find a replacement for it,<sup>35,37</sup> formalin remains the most popular, reliable and affordable fixation solution.<sup>34</sup>

Tap water,<sup>3</sup> distilled water or saline are occasionally used for tissue fixation.<sup>18,20,33</sup> Tissues fixed with these solutions often show abnormal cellular or structural

changes<sup>33</sup> that can pose a challenge for the correct diagnosis of the lesion.<sup>33</sup> Saline does not cause any fixation at all<sup>19</sup> and should not be used even for a short time.<sup>33</sup> The immersion of the specimen in saline causes the bizarre appearance of epithelial cells, which can suggest malignancy.<sup>5</sup> Antiseptics, mouthwashes or local anesthetic solutions are also inappropriate for tissue fixation.<sup>3,5,15,26</sup> The specimen cannot be properly fixed with these solutions,<sup>3,5,15,26</sup> and thus, tissue autolysis continues.<sup>24</sup> Fixatives that are protein precipitants, such as ethanol and methanol (irrespective of their osmotic pressure), cause tissue shrinkage. Thus, tissues that are attached to each other when alive may be pulled apart in these fixatives and leave empty spaces.<sup>5</sup> Alcohol makes the tissue fragile and creates artifacts following microtome sectioning (chattering and the Venetian blind artifact).<sup>24</sup> The use of ethanol as a fixative can cause the crush artifact, which is due to protein coagulation seen as intense eosinophilic staining at the center of the tissue specimen in H & E. Ethanol does not completely fix proteins.<sup>5</sup> The use of alcohol as a fixative results in the weak staining of the epithelium and an inadequate fixation of the connective tissue. In such conditions, collagen bundles have an amorphous feature, which is not due to scar tissue formation; it is an artifact.<sup>24</sup> When encountering the tissue specimen in an unsuitable fixative, it should be immediately replaced with the 10% neutral buffered formalin<sup>5</sup> to prevent further morphological changes in the tissue.<sup>20</sup>

Freezing the specimen before or instead of fixation is not suitable.<sup>4,5,7,25,37</sup> It can cause the dehydration of cells and the subsequent condensation of the cytoplasm.<sup>5,7,24</sup> This change is characterized by the granular paranuclear condensation of the cytoplasm.<sup>24</sup> The formation of ice crystals following the freezing of the tissue specimen results in the formation of interstitial and intracytoplasmic vacuoles.<sup>5,7,24</sup> In the histopathologic sections of the frozen tissues, gaps in the tissue cause the appearance of Swiss cheese holes in the epithelium, indicative of areas where ice crystals have perforated the tissue.<sup>24</sup>

### Artifacts caused by formalin

The 10% neutral buffered formalin is the best tissue fixative introduced so far.<sup>5,24</sup> Fixation with formalin prevents autolysis and the occurrence of some artifacts.<sup>19</sup> However, some considerations should be taken into account when using it. Formalin itself can cause tissue artifacts.<sup>5,7,19,34</sup>

The concentration of formalin should be adequate to ensure accurate fixation.<sup>7</sup> Formalin is a diluted solution of buffered formaldehyde.<sup>6</sup> However, sometimes the ancillary staff may overdilute it.<sup>3</sup> This can result in the weak fixation of the tissue specimen.<sup>3</sup> Artifacts occur in the form of the acantholysis of epithelial cells, whereas the basal cell layer remains attached to the underlying connective tissue. This acantholytic artifact can mimic pemphigus, as well as Hailey–Hailey disease or Darier’s disease.<sup>24</sup>

To ideally preserve the morphological details of the tissue, fixation should be done at room temperature. Although a rise of temperature (45–55°C)<sup>13,20</sup> increases the rate of fixation, the overheating of formalin can cause vacuolization, the overstaining of cytoplasm and the appearance of pyknotic nuclei.<sup>13</sup>

The tissue specimen fixed in the 10% neutral buffered formalin should be sent to the lab as soon as possible.<sup>7</sup> Formalin fixation is often associated with color change,<sup>3</sup> volume change (33% shrinkage)<sup>19,24</sup> and the hardening of the tissue.<sup>3,25</sup> Moreover, secondary shrinkage may occur in the specimen following long-term immersion in formalin.<sup>5,24</sup> Similar to delayed or inadequate fixation, long-term fixation also causes some changes in the tissues.<sup>19,25</sup> Long-term formalin fixation can cause secondary shrinkage and hardening.<sup>5</sup> This can result in tissue separation, microscopically mimicking empty spaces.<sup>5</sup>

Formalin fixation can cause the pigmentation artifact. The bonding of formalin with the heme of red blood cells forms the formalin–heme complex, which is seen as black precipitates in the tissue specimen.<sup>5,20,21</sup> The fast transfer of the formalin-fixed specimen to the pathology lab enables the lab staff to start tissue processing in optimal fixation conditions.<sup>38</sup>

The preservation of the specimen depends both on the pathologist and on the dentist. Unfortunately, it seems dentists believe that the lab would start processing on their specimen immediately after receipt; however, that is not really the case.<sup>39</sup>

### Artifacts due to the size of the specimen

The ability of oral pathologists to correctly interpret the biopsy sample depends not only on the quality, but also on the quantity of the sample.<sup>20,30</sup> In biopsy, and more commonly in incisional biopsy, if the specimen is thin, especially if it is in the form of a thin, delicate oral mucosa ribbon,<sup>5</sup> its shrinkage in formalin causes the curling and bending of the tissue.<sup>5,30</sup> This change, known as the curling artifact, complicates the orientation of the specimen.<sup>5,20,30</sup> Unsuitable orientation can lead to the tangential incisions of the specimen, or the sectioning of only the epithelium or the connective tissue, and not both.<sup>3</sup>

Moreover, the curling of the specimen onto itself during fixation often results in the loss of junction between the epithelium and the connective tissue, especially if the specimen does not have the submucosal layer or the underlying muscle.<sup>7</sup>

This artifact can be prevented by ensuring an adequate depth of the specimen.<sup>5</sup>

If the biopsy sample is small, thin and narrow, the specimen should be immediately placed on a piece of stiff,<sup>3,24</sup> sterile/clean paper<sup>1,3</sup> for a short time (i.e., 1 min)<sup>4,15,22</sup> before its immersion in a fixative so that its surface faces upward<sup>3</sup> and its connective tissue side faces downward.<sup>15</sup> By doing so, the epithelium is preserved in its correct


position,<sup>24</sup> and one can ensure that the tissue specimen is positioned straight during fixation and is well-oriented for the histopathological assessment.<sup>15</sup>

Surgeons can use sutures to help in the correct orientation of the specimen and send a note to the lab regarding the relation between the sutures and the specimen.<sup>3</sup>

## Conclusions

Knowledge on the part of clinicians / dentists / surgeons regarding the factors and potential conditions that can lead to artifacts can decrease the risk of their occurrence, and considerably help pathologists and patients by paving the way for a correct diagnosis, and consequently an appropriate treatment plan.

### ORCID iDs

Massoumeh Zargarán  <https://orcid.org/0000-0002-8843-2590>

### References

- López Jornet P, Velandrino Nicolás A, Martínez Beneyto Y, Fernández Soria M. Attitude towards oral biopsy among general dentists in Murcia. *Med Oral Patol Oral Cir Bucal*. 2007;12(2):E116–E121.
- James K, Toner M, Stassen LF. Performing mucosal tissue biopsies in general dental practice. *J Ir Dent Assoc*. 2011;57(4):203–208.
- Kumaraswamy KL, Vidhya M, Rao PK, Mukunda A. Oral biopsy: Oral pathologist's perspective. *J Cancer Res Ther*. 2012;8(2):192–198.
- Avon SL, Klieb HB. Oral soft-tissue biopsy: An overview. *J Can Dent Assoc*. 2012;78:c75.
- Rastogi V, Puri N, Arora S, Kaur G, Yadav L, Sharma R. Artefacts: A diagnostic dilemma – a review. *J Clin Diagn Res*. 2013;7(10):2408–2413.
- Melrose RJ, Handlers JP, Kerpel S, Summerlin DJ, Tomich CJ; American Academy of Oral and Maxillofacial Pathology. The use of biopsy in dental practice. The position of the American Academy of Oral and Maxillofacial Pathology. *Gen Dent*. 2007;55(5):457–463,468.
- Mota-Ramírez A, Silvestre FJ, Simó JM. Oral biopsy in dental practice. *Med Oral Patol Oral Cir Bucal*. 2007;12(7):E504–E510.
- Jephcott A. The surgical management of the oral soft tissues: 3. Biopsy. *Dent Update*. 2007;34(10):654–657.
- Manyam R, Reena K, Saraswathi TR. Role of deeper sections in diagnostic oral histopathology: A retrospective study. *Indian J Dent Res*. 2011;22(1):62–65.
- Wan A, Savage NW. Biopsy and diagnostic histopathology in dental practice in Brisbane: Usage patterns and perceptions of usefulness. *Aust Dent J*. 2010;55(2):162–169.
- Saini R, Saini S, Sharma S. Oral biopsy: A dental gawk. *J Surg Tech Case Rep*. 2010;2(2):93.
- Logan RM, Goss AN. Biopsy of the oral mucosa and use of histopathology services. *Aust Dent J*. 2010;55(Suppl 1):9–13.
- Bindhu P, Krishnapillai R, Thomas P, Jayanthi P. Facts in artifacts. *J Oral Maxillofac Pathol*. 2013;17(3):397–401.
- Allen CM. The oral pathology report: Submission of specimens and interpretation of results. *Dermatol Ther*. 2002;15(3):179–184.
- Poh CF, Ng S, Berean KW, Williams PM, Rosin MP, Zhang L. Biopsy and histopathologic diagnosis of oral premalignant and malignant lesions. *J Can Dent Assoc*. 2008;74(3):283–288.
- Camacho Alonso F, López Jornet P, Jiménez Torres MJ, Orduña Domingo A. Analysis of the histopathological artefacts in punch biopsies of the normal oral mucosa. *Med Oral Patol Oral Cir Bucal*. 2008;13(10):E636–E639.
- Pippi R. Technical notes about soft tissues biopsies of the oral cavity. *Minerva Stomatol*. 2006;55(10):551–566.
- Atanda AT, Raphael S. Role of surgeons in determining outcome of histopathology specimens. *Niger J Surg*. 2013;19(2):68–72.
- Jain N. Essentials before sending biopsy specimens: A surgeon's perspective and pathologists concern. *J Maxillofac Oral Surg*. 2011;10(4):361–364.
- Kumar K, Shetty DC, Dua M. Biopsy and tissue processing artifacts in oral mucosal tissues. *Int J Head Neck Surg*. 2012;3(2):92–98.
- Khan S, Tijare M, Jain M, Desai A. Artifacts in histopathology: A potential cause of misinterpretation. *Research & Reviews: Journal of Dental Sciences*. 2014;2(2):23–31.
- Seoane J, Varela-Centelles PI, Ramírez JR, Cameselle-Teijeiro J, Romero MA. Artefacts in oral incisional biopsies in general dental practice: A pathology audit. *Oral Dis*. 2004;10(2):113–117.
- Handlers JP. Diagnosis and management of oral soft-tissue lesions: The use of biopsy, toluidine blue staining, and brush biopsy. *J Calif Dent Assoc*. 2001;29(8):602–606.
- Chatterjee S. Artefacts in histopathology. *J Oral Maxillofac Pathol*. 2014;18(Suppl 1):S111–S116.
- Margarone JE, Natiella JR, Vaughan CD. Artifacts in oral biopsy specimens. *J Oral Maxillofac Surg*. 1985;43(3):163–172.
- Oliver RJ, Sloan P, Pemberton MN. Oral biopsies: Methods and applications. *Br Dent J*. 2004;196(6):329–333.
- Christensen GJ. Soft-tissue cutting with laser versus electrosurgery. *J Am Dent Assoc*. 2008;139(7):981–984.
- Yanduri S, Pandey G, Kumar VB, Suma S, Madhura MG. Artifacts in oral biopsy specimens: A comparison of scalpel, punch, and laser biopsies. *Indian J Oral Health Res*. 2016;2(2):100–105.
- Davari P, Fazel N. Practical pearls for oral procedures. *Clin Dermatol*. 2016;34(4):440–448.
- Masthan KM, Sankari SL, Babu NA, Rajguru JP. How to help the oral pathologist in making an accurate diagnosis. *J Clin Diagn Res*. 2013;7(1):181–184.
- Romeo U, Palaia G, Del Vecchio A, et al. Effects of KTP laser on oral soft tissues. An in vitro study. *Lasers Med Sci*. 2010;25(4):539–543.
- Singhal P, Singh NN, Sreedhar G, Banerjee S, Batra M, Garg A. Evaluation of histomorphometric changes in tissue architecture in relation to alteration in fixation protocol – an in vitro study. *J Clin Diagn Res*. 2016;10(8):ZC28–ZC32.
- Sengupta S, Prabhat K, Gupta V, Vij H, Vij R, Sharma V. Artefacts produced by normal saline when used as a holding solution for biopsy tissues in transit. *J Maxillofac Oral Surg*. 2014;13(2):148–151.
- Comănescu M, Arsene D, Ardeleanu C, Bussolati G. The mandate for a proper preservation in histopathological tissues. *Rom J Morphol Embryol*. 2012;53(2):233–242.
- Comanescu M, Annaratone L, D'Armento G, Cardoso G, Sapino A, Bussolati G. Critical steps in tissue processing in histopathology. *Recent Pat DNA Gene Seq*. 2012;6(1):22–32.
- Sleiman R, Kurban M, Abbas O. Maximizing diagnostic outcomes of skin biopsy specimens. *Int J Dermatol*. 2013;52(1):72–78.
- Patil S, Rao RS, Agarwal A, Raj AT. Instant transport media for biopsied soft tissue specimens: A comparative study. *Scientifica (Cairo)*. 2015;2015:876531.
- Start RD, Cross SS, Smith JH. Assessment of specimen fixation in a surgical pathology service. *J Clin Pathol*. 1992;45(6):546–547.
- Dimenstein IB. Grossing biopsies: An introduction to general principles and techniques. *Ann Diagn Pathol*. 2009;13(2):106–113.

# Shprintzen–Goldberg syndrome with plagiocephaly: A case report

## Zespół Shprintzena–Goldberga ze skośnogłowie – opis przypadku

Chaitali Hambire<sup>A–F</sup>

Department of Pediatric Dentistry, Government Dental College and Hospital, Aurangabad, India

A – research concept and design; B – collection and/or assembly of data; C – data analysis and interpretation; D – writing the article; E – critical revision of the article; F – final approval of the article

Dental and Medical Problems, ISSN 1644-387X (print), ISSN 2300-9020 (online)

*Dent Med Probl.* 2019;56(3):307–310

### Address for correspondence

Chaitali Hambire  
E-mail: chaitalimirajkar@gmail.com

### Funding sources

None declared

### Conflict of interest

None declared

Received on March 25, 2019

Reviewed on April 14, 2019

Accepted on April 30, 2019

Published online on September 30, 2019

### Abstract

The Shprintzen–Goldberg syndrome (SGS) is an autosomal dominant disorder with multiple congenital abnormalities. It is the result of de novo gene mutations. Recently, mutations in the *SKI* gene are considered to be related to this syndrome. This gene is responsible for the manufacturing of protein which regulates the transforming growth factor beta (TGF- $\beta$ ) signaling pathway. There are characteristic craniofacial, skeletal, neurological, and connective tissue abnormalities associated with SGS.

This is a case report of a 6-year-old male child who reported to the Department of Pediatric Dentistry at the Government Dental College and Hospital, Aurangabad, India, with decayed teeth. He had craniofacial, skeletal, cardiovascular, and other abnormalities suggestive of SGS. The patient had a tall forehead with plagiocephaly and a high-arched palate with hypoplastic teeth. His ears were apparently low-set with posterior rotation. The child had eyes with proptosis, myopia, hypertelorism, and down-slanting palpebral fissures. The child had moderate mental retardation with craniofacial features typical of this syndrome. The Shprintzen–Goldberg syndrome has many similarities with the Marfan syndrome (MFS) or the Loeys–Dietz syndrome (LDS) due to considerable phenotypic overlapping.

**Key words:** strabismus, Shprintzen–Goldberg syndrome, high-arched palate, plagiocephaly

**Słowa kluczowe:** zez, syndrom Shprintzena–Goldberga, podniebienie gotyckie, skośnogłowie

### Cite as

Hambire C. Shprintzen–Goldberg syndrome with plagiocephaly: A case report. *Dent Med Probl.* 2019;56(3):307–310. doi:10.17219/dmp/109111

### DOI

10.17219/dmp/109111

### Copyright

© 2019 by Wrocław Medical University

This is an article distributed under the terms of the

Creative Commons Attribution 3.0 Unported License (CC BY 3.0)

(<https://creativecommons.org/licenses/by/3.0/>)

## Introduction

The Shprintzen–Goldberg syndrome (SGS) is a very rare congenital disorder affecting craniofacial, skeletal, neurological, and connective tissues. Craniosynostosis with marfanoid habitus and characteristic facial dysmorphism are the key features of this syndrome.<sup>1–3</sup> Dolichocephaly, low-set ears, a high prominent forehead, proptosis, hypertelorism, divergent strabismus, down-slanting eyes, a high-arched narrow palate, and maxillary hypoplasia are the most frequent craniofacial abnormalities in SGS.<sup>1,2</sup> Arachnodactyly, flat feet, pectus deformity, scoliosis, and hypermobile joints are the skeletal abnormalities.<sup>1</sup> Myopia and telecanthus are some other important ophthalmic features characteristic of SGS.<sup>2</sup> Affected individuals also suffer from hypotonia, cardiac defects and umbilical hernia.<sup>3–5</sup>

The Shprintzen–Goldberg syndrome has many similarities with the Marfan syndrome (MFS) or the Loeys–Dietz syndrome (LDS) due to considerable phenotypic overlapping.<sup>3–5</sup> Differential diagnosis includes MFS, LDS, the Idaho syndrome-II, the Antley–Bixler syndrome (ABS), congenital contractural arachnodactyly (CCA), and several other craniosynostotic syndromes.<sup>4,5</sup> There is no male or female predilection. The development of the affected individual is delayed, with mild to moderate intellectual disability.

This is a case report of a 6-year-old male child who reported to the Department of Pediatric Dentistry at the Government Dental College and Hospital, Aurangabad, India, with decayed teeth. He had craniofacial, skeletal, cardiovascular, and other abnormalities suggestive of SGS.

## Case report

A six-year-old male patient was brought to our department by his parents with a chief complaint of decayed teeth. The child was carried by his father, as he was unable to walk without support. The parents were healthy, in a non-consanguineous marriage. They had a poor socioeconomic background. The boy was their first-born child. He was born without any history of complications during pregnancy. There was no history of known exposure to teratogens during the perinatal period. His parents reported delayed developmental milestones. The child had defective hearing and speech. He was not able to express his problems. The parents reported that the child did not attend any school. The boy was suffering from moderate mental retardation. He presented with facial dysmorphism and musculoskeletal abnormalities.

Our physical examination revealed that the boy's limbs were weak and he had difficulty with walking. He had a tall forehead with plagiocephaly. His ears were apparently low-set with posterior rotation. The child had eyes with proptosis, myopia, hypertelorism, and down-slanting palpebral fissures. He was suffering from strabismus. His nasal bridge was flattened. The face profile was convex with marked facial asymmetry. His lips were potentially competent. The skeletal findings included pectus carinatum and flat feet. Umbilical hernia was also present (Fig. 1–3). The intraoral examination revealed that the child had deciduous dentition with multiple carious teeth (Fig. 4). His maxillary arch

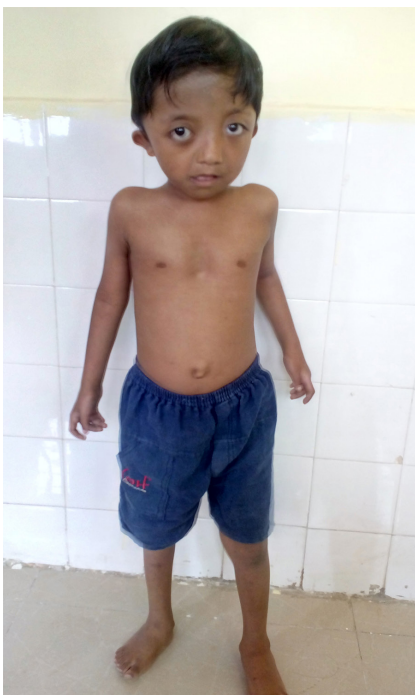

Fig. 1. Frontal view of the patient

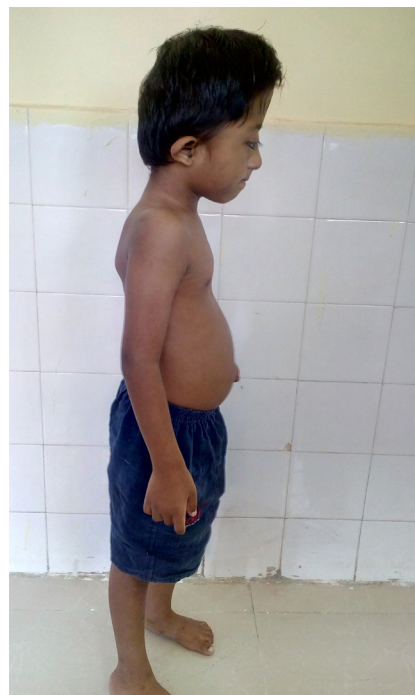

Fig. 2. Lateral view of the patient

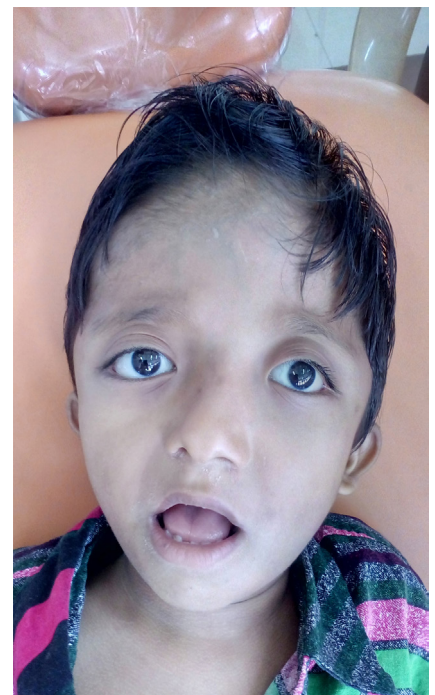


Fig. 3. Craniofacial features

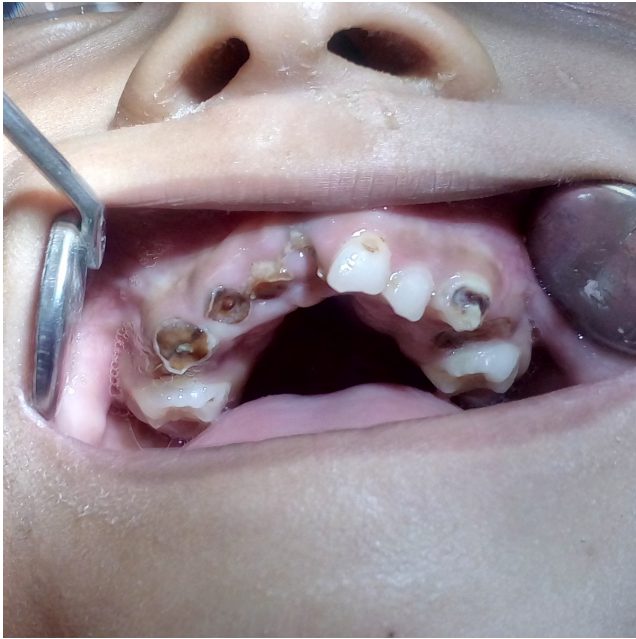

Fig. 4. Decayed and malaligned teeth

was high with a narrow and deep palate. He had a negative history of thumb sucking. Crowding was present in the mandibular teeth. The maxilla was hypoplastic. Besides, the child had congenital heart disease with aortic regurgitation.

In 1998, Greally et al. described the clinical features typical of SGS.<sup>1</sup> Based on the unusual and atypical clinical findings, the patient was subsequently diagnosed to be a possible case of SGS.

## Discussion

The Shprintzen–Goldberg syndrome is sometimes called the marfanoid-craniosynostosis syndrome, the Shprintzen–Goldberg craniosynostosis syndrome, craniosynostosis with arachnodactyly and abdominal herniae, marfanoid disorder with craniosynostosis, or type I marfanoid-craniosynostosis syndrome. Shprintzen and Goldberg described this syndrome in 1982.<sup>3</sup> Sugarman and Vogel were the first to report this condition in 1981, in a 17-year-old male with plagiocephaly, multiple craniofacial, vertebral and skeletal anomalies, umbilical and inguinal herniae, hypotonia, and mental retardation.<sup>6</sup> This syndrome has a variable phenotypic expression, as it involves the abnormalities of skeletal, connective, craniofacial, cardiovascular, and neurological tissues. Greally et al. gave a thorough review of the clinical features of SGS (Table 1).<sup>1</sup>

Mutations in the *SKI* gene are considered to be the most common etiology. This gene is responsible for the manufacturing of protein which regulates the transforming growth factor beta (TGF- $\beta$ ) signaling pathway. The TGF- $\beta$  signaling pathway is responsible for the regulation of cellular proliferation, differentiation, apoptosis, and motility. The SKI protein plays a crucial role in the development of the tissues of the skull, bones, skin, and brain. In this syndrome, a mutation in the *SKI* gene alters the SKI protein. This altered protein is not able to attach to proteins in the TGF- $\beta$  pathway and to block signaling. This results in an abnormally active TGF- $\beta$  pathway. Excess signaling of TGF- $\beta$  affects the gene activity.

Table 1. Characteristic features of the Shprintzen–Goldberg syndrome (SGS) as described by Greally et al.<sup>1</sup>

Features	Description	
Craniosynostosis	premature fusion of certain skull bones, involving the coronal, sagittal or lambdoid sutures	
Craniofacial features	head	dolichocephaly, scaphocephaly, plagiocephaly, prominent forehead
	palate and jaws	flattening/hypoplasia of the malar bone, high and narrow palate with prominent palatine ridges, micrognathia and/or retrognathia
	ears	apparently low-set with posterior rotation
	eyes	myopia, proptosis, strabismus, hypertelorism, telecanthus, down-slanting palpebral fissures
Neurological abnormalities	mild to moderate intellectual disability, delayed motor and cognitive milestones	
Brain abnormalities	hydrocephalus, dilatation of the lateral ventricles, Chiari malformation type I	
Cardiovascular abnormalities	prolapsed mitral valve, dilatation of the aortic root, mitral regurgitation/incompetence, aortic regurgitation	
Skeletal anomalies	joints	hypermobility of joints, osteopenia
	skull	craniosynostosis, wide anterior fontanel
	spine and vertebrae	C1–C2 vertebral abnormality (fusion or subluxation), scoliosis (abnormal side-to-side curvature of the spine), square-shaped vertebral bodies
	extremities	dolichostenomelia, arachnodactyly (long, slender fingers), camptodactyly (1 or more fingers permanently bent), metatarsus adductus, talipes equinovarus, flat feet
chest	pectus excavatum (sunken chest) or pectus carinatum (protruding chest), thin ribs, 13 pairs of ribs	
Genitourinary abnormalities	inguinal hernia, cryptorchidism in males	
Other findings	herniae and abdominal wall defects, loss of subcutaneous fat, arterial tortuosity and aneurysms, broad/bifid uvula, cleft palate, dural ectasia	

Consequently, the development of many body systems, including the bones and brain, is disturbed, producing a wide range of signs and symptoms of SGS.<sup>4,7</sup> In a case report describing a Japanese boy with clinical findings consistent with SGS, Kosaki et al. identified a 3662E-A transition (134797.0045) resulting in the cys 1221-to-tyr (C 1221 Y) substitution in the *FBN 1* gene.<sup>8</sup> A defect in the gene present on chromosome 15 is also considered to be responsible for this syndrome.<sup>9</sup> Germline mosaicism with mutations in 3 genomic loci have been linked to SGS, thereby making it a molecularly heterogeneous disorder.<sup>10</sup> The 4<sup>th</sup> region (15q25-qter) is also considered to be the cause of this syndrome.<sup>11</sup> Most investigators believe that multiple genes are responsible for a single phenotype. Thus, mutations in other genes may also be related to SGS.

The differential diagnosis of SGS should embrace LDS, MFS, CCA, frontometaphyseal dysplasia, the Melnick–Needles syndrome (MNS), the Idaho syndrome-II, and ABS.<sup>12–23</sup>

The occurrence of SGS is very rare. As of 2016, approx. 60 cases of SGS have been described in the medical literature since the first case was reported in the original publication by Sugarman and Vogel in 1981.<sup>6,24</sup>

In our case, the 6-year-old male child had the majority of the characteristic features of SGS as described by Greally et al.<sup>1</sup> The child had moderate mental retardation and craniofacial features typical of this syndrome. His skeletal, cardiovascular and neurological features could also be associated with SGS.

There was no positive family history in our case. The parents and siblings of the patient were without any abnormalities. The Shprintzen–Goldberg syndrome is mostly the result of de novo gene mutations. In very rare cases, this syndrome is inherited from normal parents with defective or altered genes.

## Conclusions

Patients with SGS can have variable phenotypes and abnormalities. A thorough and meticulous clinical examination along with a detailed history are required to diagnose this syndrome. This condition is not life-threatening, but the patient can suffer from the complications arising from cardiac, respiratory or skeletal abnormalities. A team of a pediatrician, cardiologist, ophthalmologist, radiologist, speech pathologist, physical therapist, and surgeon is needed to treat and manage such patients. Standard therapies are limited to symptom management, such as the repair of aneurysms and heart valves as well as spinal and chest malformations, and the operation of craniosynostosis, which has to be done in the 1<sup>st</sup> year of life.

## ORCID iDs

Chaitali Hambire  <https://orcid.org/0000-0001-7672-0184>

## References

1. Greally MT, Carey JC, Milewicz DM, et al. Shprintzen–Goldberg syndrome: A clinical analysis. *Am J Med Genet*. 1998;76(3):202–212.
2. Topouzelis N, Markovitsi E, Antoniadis K. Shprintzen–Goldberg syndrome: Case report. *Cleft Palate Craniofac J*. 2003;40(4):433–436.
3. Shprintzen RJ, Goldberg RB. A recurrent pattern syndrome of craniosynostosis associated with arachnodactyly and abdominal hernias. *J Craniofac Genet Dev Biol*. 1982;2(1):65–74.
4. Doyle AJ, Doyle JJ, Bessling SL, et al. Mutations in the TGF- $\beta$  repressor *SKI* cause Shprintzen–Goldberg syndrome with aortic aneurysm. *Nat Genet*. 2012;44(11):1249–1254.
5. Robinson PN, Neumann LM, Demuth S, et al. Shprintzen–Goldberg syndrome: Fourteen new patients and a clinical analysis. *Am J Med Genet*. 2005;135(3):251–262.
6. Sugarman G, Vogel MW. Craniofacial and musculoskeletal abnormalities. A questionable connective tissue disease. *Synd Iden*. 1981;7:16–17.
7. Carmignac V, Thevenon J, Ades L, et al. In-frame mutations in exon 1 of *SKI* cause dominant Shprintzen–Goldberg syndrome. *Am J Hum Genet*. 2012;91(5):950–957.
8. Kosaki K, Takahashi D, Udaka T, et al. Molecular pathology of Shprintzen–Goldberg syndrome. *Am J Med Genet*. 2006;140(1):104–108.
9. Sood S, Eldadah ZA, Krause WL, McIntosh I, Dietz HC. Mutation in *fibrillin-1* and the Marfanoid-craniosynostosis (Shprintzen–Goldberg) syndrome. *Nat Genet*. 1996;12(2):209–211.
10. Pauliks LB, Chan KC, Lorts A, Elias ER, Cayre RO, Valdes-Cruz LM. Shprintzen–Goldberg syndrome with tetralogy of Fallot and subvalvular aortic stenosis. *J Ultrasound Med*. 2005;24(5):703–706.
11. Shanske AL, Goodrich JT, Ala-Kokko L, Baker S, Frederick B, Levy B. Germline mosaicism in Shprintzen–Goldberg syndrome. *Am J Med Genet*. 2012;158A(7):1574–1578.
12. Loeyls BL, Chen J, Neptune ER, et al. A syndrome of altered cardiovascular, craniofacial, neurocognitive and skeletal development caused by mutations in *TGFBR1* or *TGFBR2*. *Nat Genet*. 2005;37(3):275–281.
13. Loeyls BL, Schwarze U, Holm T, et al. Aneurysm syndromes caused by mutations in the TGF-beta receptor. *N Engl J Med*. 2006;355(8):788–798.
14. Dietz HC. Marfan syndrome. In: Adam MP, Ardinger HH, Pagon RA, et al., eds. GeneReviews® [Internet]. Seattle, WA: University of Washington, Seattle; 1993–2014; 2001 [updated 2017]. <http://www.ncbi.nlm.nih.gov/books/NBK1335>. Accessed January 17, 2019.
15. Godfrey M. Congenital contractural arachnodactyly. In: Adam MP, Ardinger HH, Pagon RA, et al., eds. GeneReviews® [Internet]. Seattle, WA: University of Washington, Seattle; 1993–2014; 2001 [updated 2012]. <http://www.ncbi.nlm.nih.gov/books/NBK1386>. Accessed January 18, 2019.
16. Godfrey M. *Fibrillin-2* mutations in congenital contractural arachnodactyly. In: Robinson PN, Godfrey M, eds. *Marfan Syndrome: A Primer for Clinicians and Scientists*. New York, NY: Plenum; 2004:123–129.
17. Gorlin RJ, Cohen MM Jr. Frontometaphyseal dysplasia. A new syndrome. *Am J Dis Child*. 1969;118(3):487–494.
18. Danks DM, Mayne V. Frontometaphyseal dysplasia: A progressive disease of bone and connective tissue. *Birth Defects Orig Artic Ser*. 1974;10(12):57–60.
19. Holt JF, Thompson GR, Arenberg IK. Frontometaphyseal dysplasia. *Radiol Clin North Am*. 1972;10(2):225–243.
20. Melnick JC, Needles CF. An undiagnosed bone dysplasia. A 2-family study of 4 generations and 3 generations. *Am J Roentgenol Radium Ther Nucl Med*. 1966;97(1):39–48.
21. LaMontagne AE. Urological manifestations of the Melnick–Needles syndrome: A case report and review of the literature. *J Urol*. 1991;145(5):1020–1021.
22. Stoll C. Shprintzen–Goldberg marfanoid syndrome: A case followed up for 24 years. *Clin Dysmorphol*. 2002;11(1):1–7.
23. Antley R, Bixler D. Trapezoidocephaly, midfacial hypoplasia and cartilage abnormalities with multiple synostoses and skeletal fractures. *Birth Defects Orig Artic Ser*. 1975;11(2):397–401.
24. Greally MT. Shprintzen–Goldberg syndrome. In: Adam MP, Ardinger HH, Pagon RA, et al., eds. GeneReviews® [Internet]. Seattle, WA: University of Washington, Seattle; 1993–2014; 2006 [updated 2013]. <http://www.ncbi.nlm.nih.gov/books/NBK1277>. Accessed January 21, 2019.

# Transformation of a glandular odontogenic cyst into mucoepidermoid carcinoma of the mandible: A case report

## Transformacja zębopochodnej torbieli gruczołowej w raka śluzowo-płaskonabłonkowego żuchwy – opis przypadku

Mateusz Dymek<sup>1,2,A–F</sup>, Mariusz Książek<sup>3,C–E</sup>, Bogumił Lewandowski<sup>2,A,E,F</sup>

<sup>1</sup> Collegium Medicum of the University of Rzeszów, Poland

<sup>2</sup> Department of Maxillofacial Surgery, Fryderyk Chopin Clinical Voivodeship Hospital No.1 in Rzeszów, Poland

<sup>3</sup> Department of Pathology, MedLifeCover, Krosno, Poland

A – research concept and design; B – collection and/or assembly of data; C – data analysis and interpretation; D – writing the article; E – critical revision of the article; F – final approval of the article

Dental and Medical Problems, ISSN 1644-387X (print), ISSN 2300-9020 (online)

*Dent Med Probl.* 2019;56(3):311–316

### Address for correspondence

Mateusz Dymek  
E-mail: faceinstytut@gmail.com

### Funding sources

None declared

### Conflict of interest

None declared

Received on February 6, 2019

Reviewed on May 1, 2019

Accepted on June 3, 2019

Published online on September 30, 2019

### Abstract

The glandular odontogenic cyst (GOC) is a rare pathology of odontogenic origin, which can behave unpredictably. It is problematic in clinical, radiographic and histological diagnostics. Intraosseous mucoepidermoid carcinoma (MEC) is a rare tumor which affects the jaws, typically found in the mandible. This malignancy, which usually originates from the salivary glands, can also be caused by a transformation of the mucous cells found in odontogenic cysts.

This article presents a rare case of GOC transforming into MEC of the mandible, which was reported during the treatment of a 52-year-old male patient. The aim of this work was to present some of the therapeutic and clinical difficulties encountered when GOC transforms into mucoepidermoid cancer in the mandible, considering the pathomorphological and histological differentiations. The differentiation between MEC and GOC might be difficult through microscopic examination and requires the cooperation of a clinician – a maxillofacial surgeon – and a histopathologist.

**Key words:** glandular odontogenic cyst, mucoepidermoid carcinoma, neoplastic transformation

**Słowa kluczowe:** zębopochodna torbiel gruczołowa, rak śluzowo-płaskonabłonkowy, transformacja nowotworowa

### Cite as

Dymek M, Książek M, Lewandowski B. Transformation of a glandular odontogenic cyst into mucoepidermoid carcinoma of the mandible: A case report. *Dent Med Probl.* 2019;56(3):311–316. doi:10.17219/dmp/109807

### DOI

10.17219/dmp/109807

### Copyright

© 2019 by Wrocław Medical University

This is an article distributed under the terms of the Creative Commons Attribution 3.0 Unported License (CC BY 3.0) (<https://creativecommons.org/licenses/by/3.0/>)



## Introduction

According to the current literature, glandular odontogenic cysts (GOCs) are rare and they constitute 0.012–1.3% of all cysts located in the facial part of the skull.<sup>1</sup> The condition was first described in 1987 by Padayachee and Van Wyk in 2 cases known as ‘sialo-odontogenic cysts.’<sup>2</sup> In 1988, Gardner et al. introduced the term ‘glandular odontogenic cyst,’<sup>3</sup> and the World Health Organization (WHO) included this term in their classification of odontogenic tumors published in 1992. Approximately 180 GOC cases have been documented in the medical literature to date.<sup>2–4</sup> The glandular odontogenic cyst is marginally more common in men (1.3:1), with peak morbidity occurring in the patient’s 60s. In most cases described, these cysts were located in the mandible, primarily in its anterior section.<sup>5</sup> At its early stages, the cyst develops slowly and asymptotically in the form of a tumor located in the bone; it is frequently detected accidentally. Even when a tumor is detected randomly in the X-ray of the bone, with minimal facial asymmetry but without the presence of pain, it does not raise any concern in the patient.<sup>6</sup>

The etiology of the glandular cyst is still not clear. In the literature, the link between GOCs and the salivary gland tissue has been primarily stressed. At present, most authors point to the association with the odontogenic epithelium, and the etiological resemblance to lesions such as periodontal cysts, follicular cysts and odontogenic acinic cysts. Clinically, GOC is manifested in the tenderness of the bone, which is deformed, and the dilation of the cortical bone layer, frequently with discontinuation (perforation), accompanied by parchment crunch or fluctuation. Advanced lesions are accompanied by sensory disorders, pain and paresthesia.<sup>7,8</sup>

Microscopy often presents diagnostic difficulties. The morphological structure of the GOC epithelium contains the odontogenic cells and the elements of the secretory gland cells. Fowler et al. stated that the microscopic diagnosis of GOC should be based on the presence of at least 7 out of 10 microscopic parameters: surface eosinophilic cuboidal cells, intraepithelial microcysts, apocrine snouts, vacuolated cells, variable thickness of the cyst lining, papillary projections, mucous goblet cells, epithelial spheres, cilia, and multiple cystic spaces.<sup>4</sup> The pathomorphological diagnosis may be impaired and requires differentiation with intraosseous mucoepidermoid carcinoma (MEC). There are some features that are present in GOC but not in MEC, which permit a histopathologist to differentiate the 2 conditions. These include a lack of the aforementioned structures and a swirling pattern within the carcinoma. Another important feature to differentiate between GOC and MEC is the presence of more complex solid or follicular structures within the proliferating epithelium in MEC and its unequivocal invasion.<sup>9,10</sup> Additional immunohistochemistry (the expression of cytokeratin 18 (CK-18), cytokeratin 19 (CK-19), p53, and

Ki-67) may be helpful in the differential diagnosis.<sup>11–13</sup> The *MAML2* gene rearrangements have been found to be specific to MEC.<sup>14</sup>

The radiological image is unremarkable, exhibiting no pathognomonic features distinguishing GOC from other pathological lesions in the facial part of the skull which take the form of multi-cavity bone structure defects, and cause bulging and dilatation, mainly of the cortical layer of the involved bone. Cavities in the cortical bone layer are often described as perforations. In radiological diagnostic imaging, GOC should be differentiated from radicular cyst, ameloblastoma, odontogenic keratocyst, solitary bone cyst, and central giant cell lesions.<sup>15</sup>

The choice of treatment depends on the size, shape and structure of the lesion. Large lesions, with a multi-chamber structure, may have a more aggressive course and require complete eradication with a wide excision margin of healthy tissue, frequently with peripheral osteoectomy. The prevalence of GOC recurrence is estimated to be approx. 10–30%.<sup>9</sup> The onset of recurrence takes place approx. 2.7 years after resection on average. Due to the risk of GOC transforming into highly differentiated MEC, patients require regular clinical and radiological follow-ups, for up to 3 years or even longer.<sup>16</sup>

Numerous authors have identified the similarity and association of GOC with MEC.<sup>17</sup> Microscopically, both of these lesions exhibit some common features. Gardner et al. presented a case of MEC which developed from the GOC lining cells.<sup>3</sup> The microscopic morphology of GOC and MEC may be similar, and they may frequently appear ambiguous in their differentiation.<sup>18,19</sup>

An example of therapeutic difficulties is the case of GOC transforming into MEC in the mandible of a 52-year-old man who was recently treated at the Department of Maxillofacial Surgery at Fryderyk Chopin Clinical Voivodeship Hospital No. 1 in Rzeszów, Poland.

## Case report

A 52-year-old male patient was referred by a dentist to the Department of the Maxillofacial Surgery at the Clinical Voivodeship Hospital No.1 in Rzeszów, Poland, due to a bulge in the alveolar region of his left mandible, which he had noticed 3 months earlier; there were no other clinical signs and the patient was otherwise in good general health. Examination revealed some asymmetry in the left cheek, due to the presence of a lump in the mandibular angle. The regional lymph nodes were impalpable. Intraoral examination revealed a hard painless lump, covered with thickened, otherwise normal mucosa. This lesion caused the shortening of the oral vestibule due to the toothless alveolar part of the mandible, in the section from tooth 35 to the area of the retromolar trigon, toward the mandibular ramus. Tooth 35, directly adjacent to the lesion, did not exhibit pathological mobility. The multiple

osteolytic defects of the alveolus of the left side of the mandible, from tooth 35 to the mandibular ramus, were found in pantomographic imaging (Fig. 1).

Computed tomography (CT) revealed multiple, extensive osteolytic defects associated with the bone lesions in the area of the mandibular corpus and the alveolar part of the left mandible, measuring 36 mm × 27 mm × 27 mm, which caused the thinning of the cortex layer. These lesions approached the mandibular ramus. On the side of the proper oral cavity, at the level of the mandibular ramus, a focus of soft tissue measuring approx. 2 cm × 1.3 cm × 1.5 cm was found; it showed a strong contrast enhancement from 62 HU to 92 HU. Lymph node levels Ib, II and III of the neck on the left side were enlarged to as much as 13 mm (Fig. 2). The microscopic examination of the tumor specimen revealed the presence of GOC (Fig. 3). The patient was qualified for the surgical removal of the cyst located in the mandibular corpus and ramus as well as for the extraction of tooth 35, which was in the lumen of the cyst. The surgical procedure was performed. Intraoperatively, the lesion was found to have a typical capsule filled with fluid on the medial side, in the area of teeth 34–36. In the distal aspect, located in the mandible angle, the bone cavity was filled with something that macroscopically resembled the granulation tissue.

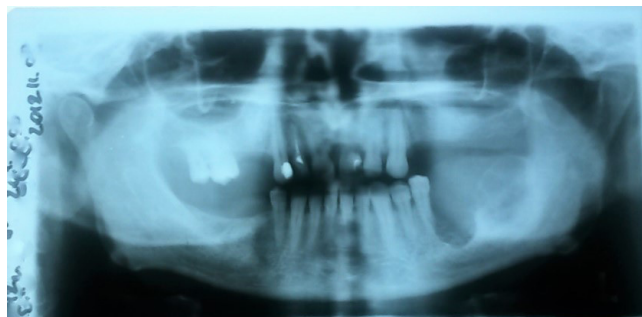

Fig. 1. Orthopantomography showing the tumor on the left side

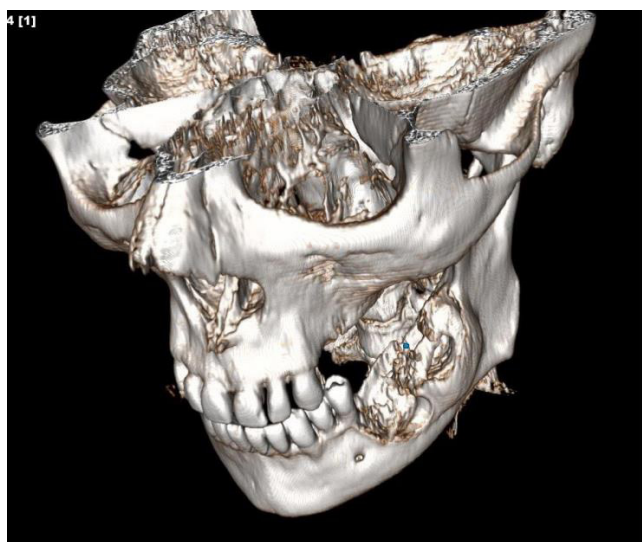

Fig. 2. Computed tomography (CT) scan of the left side of the mandible showing the tumor

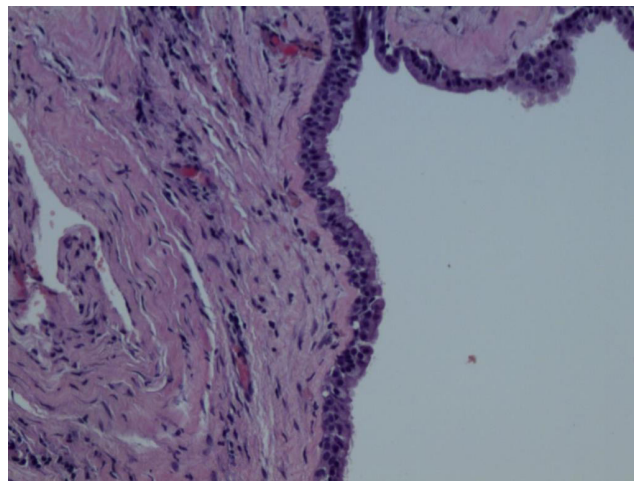


Fig. 3. Microscopic image of the characteristic epithelium of the glandular odontogenic cyst (GOC), composed of a slightly atrophic squamous layer with overlying ciliated, columnar epithelium

Hematoxylin and eosin staining (H & E); ×4 magnification.

The postoperative course was uneventful. The histopathological examination of the surgical specimen confirmed the presence of GOC. The patient was discharged on the 5<sup>th</sup> day after surgery with a recommendation for periodic monitoring and follow-ups at the hospital outpatient clinic. The microscopic image of the surgical specimen is shown in Fig. 4.

In the 1<sup>st</sup> year after surgery, the patient regularly returned for follow-ups. During the follow-ups, uneventful healing was observed. After a year, he arbitrarily discontinued monitoring and did not appear at the clinic for his appointments. He reappeared 2 years later because of swelling in his cheek, difficulties in opening and closing his jaw, and pain in his left mandibular angle. These ailments had appeared a few days earlier. External and internal oral examination suggested the recurrence of the cyst in the area of teeth 35–36, in the form of a lump

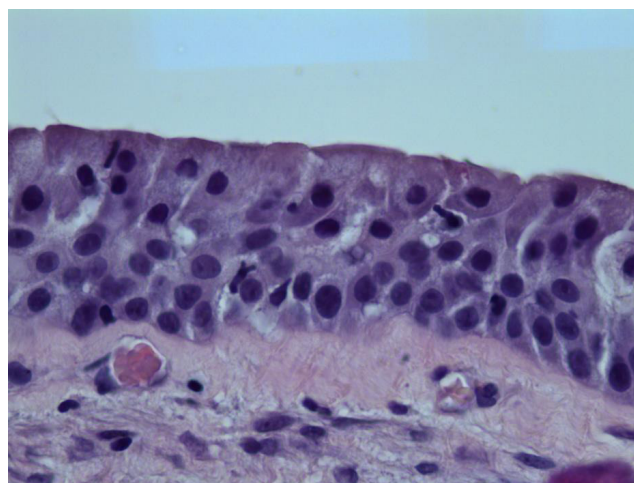


Fig. 4. Microscopic image exhibiting the details of the glandular odontogenic cyst (GOC) epithelium, in this case with only a few cilia present  
H & E; ×40 magnification.

3 cm in diameter, which was non-movable, elastic-hard and covered with normal-appearing mucosa. It caused the shortening of the oral vestibule and manifested itself in facial asymmetry on the left side. Computed tomography in combination with examination performed prior to the operation exhibited a progression in the form of exacerbated degenerative-osteolytic lesions in the mandible, including the mandibular corpus and ramus, i.e., the area of teeth 35–37 (Fig. 5), with damage to the mandibular lower margin. The defect was filled with low-density soft tissue. The lymph nodes were not enlarged. Computed tomography pointed to the recurrence of the cyst (Fig. 5). The histopathological examination of the recurrent cyst biopsy specimen revealed a relapse of GOC (Fig. 6).

Based on the histopathological and CT examination, the cyst was re-enucleated with more radical surgery, with the surrounding bone curetted to widen the surgical margins.

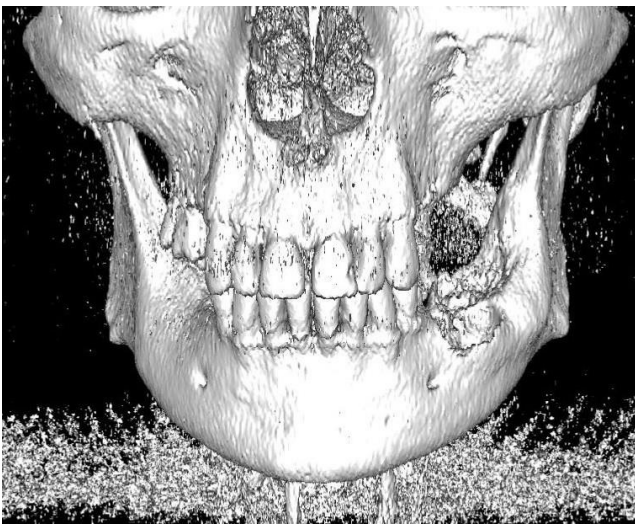


Fig. 5. Three-dimensional (3D) computed tomography (CT) scan presenting the recurring tumor on the left side

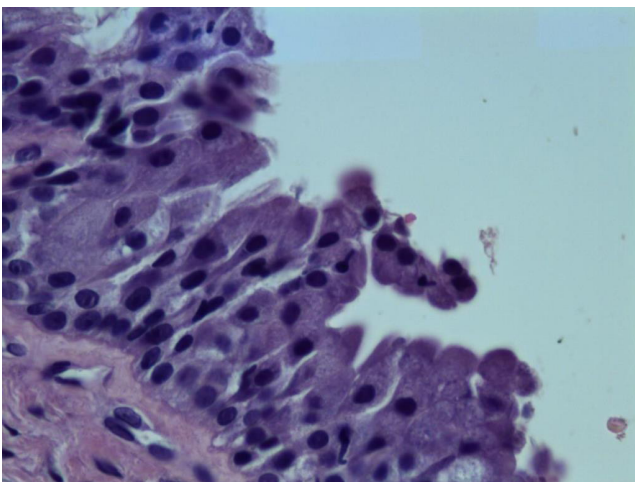


Fig. 6. Histopathologic diagnosis of the glandular odontogenic cyst (GOC) recurrence. Microscopic image showing overlying ciliated epithelium with pseudopapillae formation, with more basally located squamous differentiating cells

H & E;  $\times 40$  magnification.

During the operation, damage to the bone lamella in the lower margin of the mandibular corpus was found. The tumor mass was primarily composed of what macroscopically appeared to be the granulation tissue. The histopathological examination of the surgical specimen revealed intermediate-grade MEC (MEC G2), adjacent to GOC. Coexisting GOC-specific areas were also present, which, coupled with the previous histopathological findings of the lesion, implicated a diagnosis of MEC arising from the previous GOC (Fig. 7). Due to the location and malignant nature of the tumor as well as the history of previous surgeries, a partial mandibular resection was planned in order to remove the MEC foci from the bone, combined with a selective left suprascapular-hyoid lymphangiectomy. The patient was offered a simultaneous reconstruction with microvascular bone transplant from the iliac bone and postoperative radiotherapy, but the patient did not consent to the proposed microvascular bone graft, instead accepting the alternative of reinforcing the mandible with a standard titanium implant for stabilizing bone stumps. The resection of the left mandibular corpus was extended to include a preventive excision of the left lymphatic system on the neck, up to the level of the omohyoid muscle. The post-resection bone defect of the mandible was managed with a standard titanium plate.

The histopathological examination of the final surgical specimen after mandibular tumor resection confirmed the presence of MEC arising from the pre-existing GOC (Fig. 8 A–D). The postoperative course was uneventful. The patient was discharged on the 5<sup>th</sup> day after surgery and referred to the Radiotherapy Clinic to continue treatment with postoperative radiotherapy, where he received 60 Gy in 35 fractions. The course of the therapy was uneventful. Since radiotherapy, the patient has maintained regular surgical and oncological follow-ups.

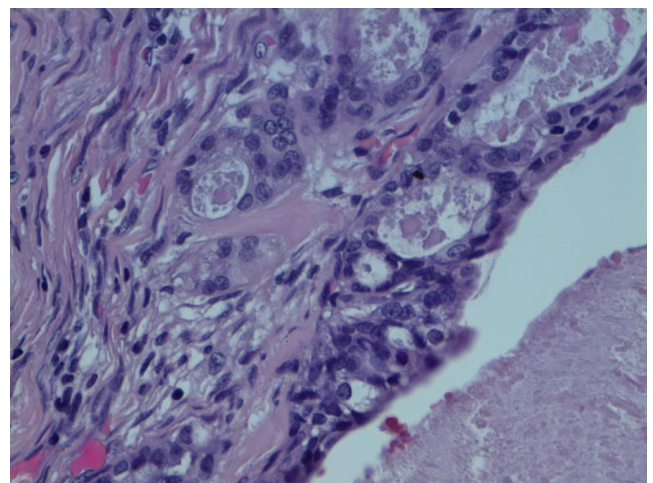
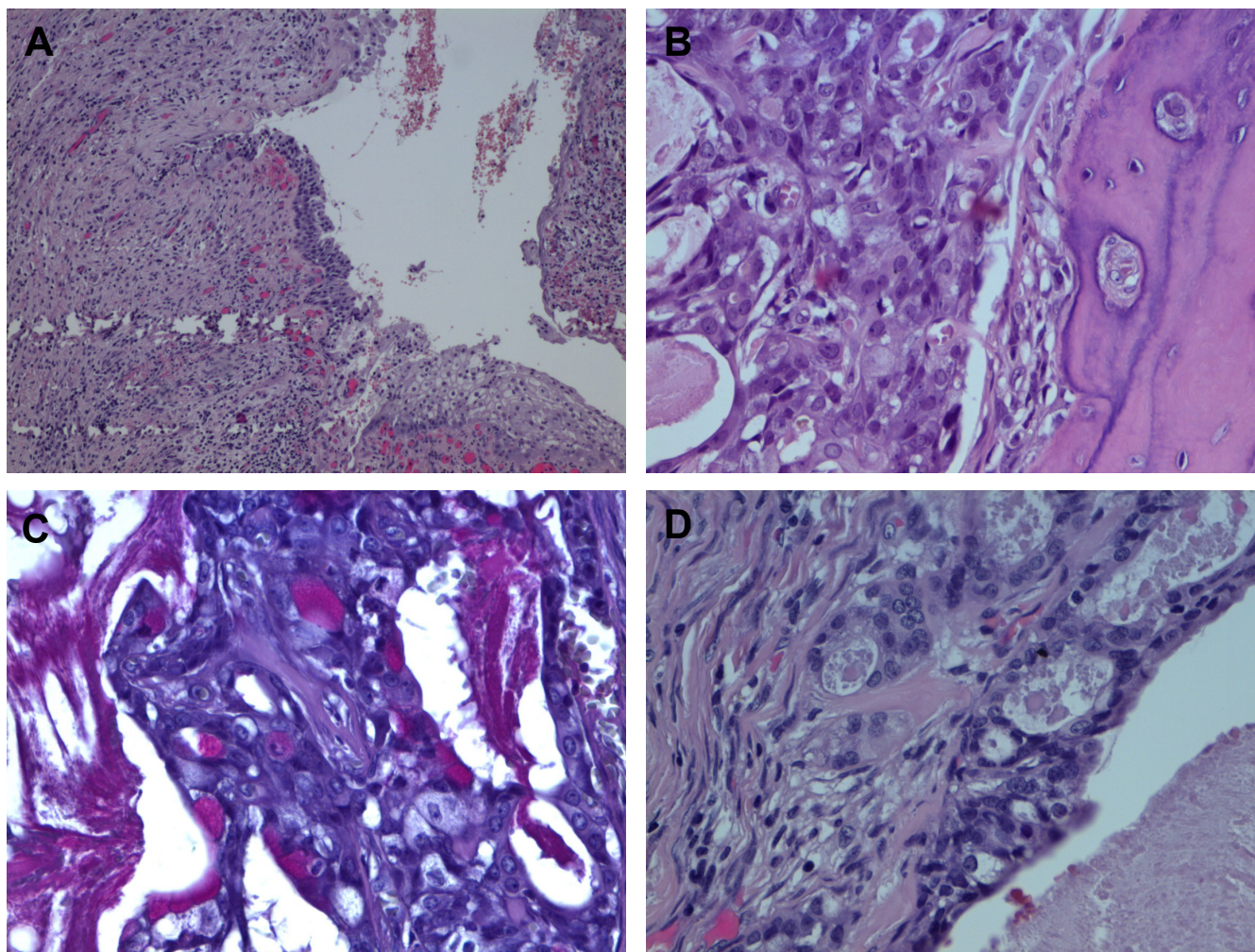


Fig. 7. Microscopic image of the surgical specimen after the removal of the recurring cyst. The malignant component on the left side of the picture are malignant glandular structures infiltrating the stroma; on the right side of the picture there is the remaining part of the glandular odontogenic cyst (GOC) with overlying epithelium

H & E;  $\times 20$  magnification.



**Fig. 8.** Post-surgical specimen showing 2 components: one benign (glandular odontogenic cyst – GOC) and the other malignant (mucoepidermoid carcinoma – MEC) A – fragment of the benign component with the GOC overlying epithelium (H & E; x4 magnification); B – bony structure infiltrated by MEC (H & E; x20 magnification); C – MEC, positive for intraepithelial mucin (pink-colored) (mucicarmine staining; x20 magnification); D – solid and glandular areas of invasive MEC (H & E; x20 magnification).

## Discussion

The literature shows examples of the neoplastic transformation of epithelial jaw cysts, most of which are associated with keratocysts or inflammatory radicular cysts.<sup>20–22</sup> According to Stoelting and Bronkhorst, the prevalence of malignant neoplasms developing from epithelial cysts is approx. 2 out of 1,000 cases.<sup>23</sup> The pathogenesis of this phenomenon has thus far remained unclear. The authors emphasize that the process of the malignant transformation of GOC into MEC can be attributed to factors occurring inside the cyst, including chronic and prolonged inflammation accompanying the cyst, various biochemical processes in the fluid of the cyst, and the mechanical irritation of the cyst by the fluid, resulting in the remodeling and keratinization of the cystic epithelium.<sup>24</sup> In the case described herein, the cyst transformation may have been affected by a prolonged chronic condition prior to treatment and recurrence after cyst removal. Fowler et al. observed recurrence in half of the 46 patients treated.<sup>4</sup> Mascitti et al. reported recurrence after ineffective cyst removal in 19.8% of the patients.<sup>25</sup>


Pires et al. suggested that many cases which were diagnosed as intraosseous MEC could be classified as low-grade MEC.<sup>11</sup> The glandular odontogenic cyst and low-grade MEC have many features in common in terms of the similarity of clinical, radiological and microscopic images. Some authors highlight the possibility of the neoplastic transformation of the glandular epithelium of GOCs as one of the causes of MEC. According to the literature, GOCs have a higher likelihood of transforming into cancer.<sup>15,17,18</sup> The clinical picture of MEC in the 52-year-old patient presented in this paper is consistent with the literature.<sup>5,9,18,24,26</sup> Mucoepidermoid carcinoma, like GOC, belongs to a family of rare jawbone tumors. Cancer can develop from the ectopic foci of the glandular tissue associated with the bone itself, or, as in this case of the 52-year-old man, from the GOC epithelium. The tumor equally affects men and women. It is usually located in the lateral aspect of the mandible. The clinical and radiological pictures of both GOCs and MEC lesions, as mentioned above, do not differ significantly. A diagnosis of MEC dictates a therapeutic management


involving a broad excision of the lesion with bone resection and lymphangiectomy. Approximately 10% of MEC tumors cause regional metastases to the cervical lymph nodes. The presented case is an example of the difficulties encountered by medical practitioners in the diagnosis and differentiation of GOC and MEC. As previously mentioned, there was a need for a maxillofacial surgeon and a histopathologist to provide clinical data, radiological images and other important test results that are necessary for a proper, unequivocal histopathological diagnosis. Therapeutic decisions should be made on the basis of a thorough individual assessment of the clinical picture, enhanced by radiographic images, taking into account the results of microscopic examination. The appearance of recurrent cysts at short intervals after surgery should arouse suspicion of transformation into low-grade MEC. Manojlović et al. observed the recurrence most frequently 2–3 years after surgery.<sup>17</sup> Numerous authors believe that in the differential diagnosis between GOC and MEC, immunohistochemistry, cytokine expression, markers, and – more and more frequently – genetic tests are needed.<sup>10–14</sup>


## Conclusions

Mucoepidermoid carcinoma can develop from the epithelial lining of GOC, which is confirmed by the available literature and our case of the 52-year-old patient. Despite the fact that both MEC and GOC are rare, they should be taken into account in the case of multiple large, cyst-like osteolytic defects located in the facial skeleton, primarily in the mandible, in the clinical radiological diagnosis, pathomorphology and differentiation between cysts and malignant bone tumors. The differentiation between MEC and GOC might be difficult on microscopic examination, requiring the cooperation of a maxillofacial surgeon and a histopathologist.

## ORCID iDs

Mateusz Dymek  <https://orcid.org/0000-0002-2001-8262>

Mariusz Książek  <https://orcid.org/0000-0002-9316-8034>

Bogumił Lewandowski  <https://orcid.org/0000-0002-8045-5093>

## References

- Abdolsamadi H, Sadr P, Barakian Y. Glandular odontogenic cyst: A case report. *Avicenna J Dent Res*. 2016;8(1):e25605.
- Padayachee A, Van Wyk CW. Two cystic lesions with features of both the botryoid odontogenic cyst and the central mucoepidermoid tumour: Sialo-odontogenic cyst? *J Oral Pathol*. 1987;16(10):499–504.
- Gardner DS, Kessler HP, Morency R, Schaffner DL. The glandular odontogenic cyst: An apparent entity. *J Oral Pathol*. 1988;17(8):359–366.
- Fowler CB, Brannon RB, Kessler HP, Castle JT, Kahn MA. Glandular odontogenic cyst: Analysis of 46 cases with special emphasis on microscopic criteria for diagnosis. *Head Neck Pathol*. 2011;5(4):364–375.
- Kasaboğlu O, Baçal Z, Usubütün A. Glandular odontogenic cyst presenting as a dentigerous cyst: A case report. *J Oral Maxillofac Surg*. 2006;64(4):731–733.
- Araújo de Morais HH, José de Holanda Vasconcellos R, de Santana Santos T, Guedes Queiroz LM, Dantas da Silveira EJ. Glandular odontogenic cyst: Case report and review of diagnostic criteria. *J Craniomaxillofac Surg*. 2012;40(2):e46–e55.
- Krishnamurthy A, Sherlin HJ, Ramalingam K, et al. Glandular odontogenic cyst: Report of two cases and review literature. *Head Neck Pathol*. 2009;3(2):153–158.
- Kaplan I, Anavi Y, Hirshberg A. Glandular odontogenic cyst: A challenge in diagnosis and treatment. *Oral Dis*. 2008;14(7):575–581.
- Patil AA, Barpande SR, Bhavthankar JD, Mandale MS. Glandular odontogenic cyst presenting as an aggressive multifocal lesion: Case report and review literature. *Int J Oral Maxillofac Pathol*. 2014;5(2):13–17.
- Kaplan I, Anavi Y, Manor R, Sulkes J, Calderon S. The use of molecular markers as an aid in the diagnosis of glandular odontogenic cyst. *Oral Oncol*. 2005;41(9):895–902.
- Pires FR, Chen SY, da Cruz Perez DE, de Almeida OP, Kowalski LP. Cytokeratin expression in central mucoepidermoid carcinoma and glandular cyst. *Oral Oncol*. 2004;40(5):545–551.
- de Sousa SO, Cabezas NT, de Oliveira PT, de Araújo VC. Glandular odontogenic cyst: Report of a case with cytokeratin expression. *Oral Surg Oral Med Oral Pathol Oral Radiol Endod*. 1997;83(4):478–483.
- Vered M, Allon I, Buchner A, Dayan D. Is maspin immunolocalization a tool to differentiate central low-grade mucoepidermoid carcinoma from glandular odontogenic cyst? *Acta Histochem*. 2010;112(2):161–168.
- Khan HA, Loya A, Azhar R, Din NV, Bell D. Central mucoepidermoid carcinoma, a case report with molecular analysis of the *TORC1/MAML2* gene fusion. *Head Neck Pathol*. 2010;4(3):261–264.
- Macdonald-Jankowski DS. Glandular odontogenic cyst: Systematic review. *Dentomaxillofac Radiol*. 2010;39(3):127–139.
- Boffano P, Cassarino E, Zavattoni E, Campisi P, Garzino-Demo P. Surgical treatment of glandular odontogenic cysts. *J Craniofac Surg*. 2010;21(3):776–780.
- Manojlović S, Grgurević J, Knezević G, Kruslin B. Glandular odontogenic cyst: A case report and clinicopathologic analysis of the relationship to central mucoepidermoid carcinoma. *Head Neck*. 1997;19(3):227–231.
- Prabhu S, Rekha K, Kumar G. Glandular odontogenic cyst mimicking central mucoepidermoid carcinoma. *J Oral Maxillofac Pathol*. 2010;14(1):12–15.
- Eversole LR, Sabes WR, Rovin S. Aggressive growth and neoplastic potential of odontogenic cysts: With special reference to central epidermoid and mucoepidermoid carcinomas. *Cancer*. 1975;35(1):270–282.
- Keszler A, Piloni MJ. Malignant transformation in odontogenic keratocysts. Case report. *Med Oral*. 2002;7(5):331–335.
- Masthan KMK, Rajkumari S, Deepasree M, Aravindha Babu N, Leena Sankari S. Neoplasms associated with odontogenic cysts. *J Dent Oral Hyg*. 2011;3(10):123–130.
- Aggarwal P, Saxena S. Aggressive growth and neoplastic potential of dentigerous cysts with particular reference to central mucoepidermoid carcinoma. *Br J Oral Maxillofac Surg*. 2011;49(6):e36–e39.
- Stoelinga PJ, Bronkhorst FB. The incidence, multiple presentation and recurrence of aggressive cysts of the jaws. *J Craniomaxillofac Surg*. 1988;16(4):184–195.
- Chan KC, Pharoah M, Lee L, Weinreb I, Perez-Ordóñez B. Intraosseous mucoepidermoid carcinoma: A review of the diagnostic imaging features of four jaw cases. *Dentomaxillofac Radiol*. 2013;42(4):20110162.
- Mascitti M., Santarelli A, Sabatucci A. Glandular odontogenic cyst: Review of literature and report of a new case with cytokeratin-19 expression. *Open Dent J*. 2014;8:1–12.
- Moghadam SA, Moghadam AF. Intraosseous mucoepidermoid carcinoma: Report of two cases. *J Dent (Shiraz)*. 2014;15(2):86–90.

# Low-level laser therapy (LLLT) in the treatment of recurrent aphthous stomatitis (RAS) – a promising treatment option: A report of two cases

## Terapia laserem małej mocy w aftach nawrotowych – obiecująca opcja w leczeniu. Opis dwóch przypadków

Maria Olejnik<sup>A–D</sup>, Zuzanna Ślebioda<sup>B–D</sup>, Barbara Dorocka-Bobkowska<sup>A,E,F</sup>

Department of Gerodontology and Oral Pathology, Poznan University of Medical Sciences, Poland

A – research concept and design; B – collection and/or assembly of data; C – data analysis and interpretation; D – writing the article; E – critical revision of the article; F – final approval of the article

Dental and Medical Problems, ISSN 1644-387X (print), ISSN 2300-9020 (online)

*Dent Med Probl.* 2019;56(3):317–321

### Address for correspondence

Maria Olejnik  
E-mail: ipdmarole@gmail.com

### Funding sources

None declared

### Conflict of interest

None declared

Received on December 14, 2018

Reviewed on March 5, 2019

Accepted on April 18, 2019

Published online on September 30, 2019

### Abstract

Recurrent aphthous stomatitis (RAS) is a chronic, ulcerative condition of the oral mucosa that affects 10–25% of the population. The etiopathogenesis of the disease is not fully understood, although a polygenic mode of inheritance and immunological dysregulation have been suggested in several studies. The contribution of numerous predisposing factors, such as a deficiency of iron, vitamin B12 or folic acid, trauma, emotional stress, endocrine disturbances, or allergy, have also been considered. So far, no causative treatment for RAS has been developed; instead, topical and systemic drugs are used to reduce pain and inflammation, and to lengthen the period of remission.

Low-level laser therapy (LLLT) is a non-invasive and atraumatic therapeutic method that involves the local application of a high-density, monochromatic, narrow-band light source. With the use of the appropriate power and wavelength, the therapy brings anti-inflammatory and analgesic results, and wound healing is promoted. Several reports on the beneficial effects of LLLT in RAS have been presented recently.

This report describes 2 cases of adult patients with RAS treated with LLLT to relieve pain and promote the healing of the ulcers. The clinical presentations with the signs and symptoms are discussed and illustrated, along with the treatment algorithms and outcomes.

**Key words:** oral mucosa, low-level laser therapy, aphthous stomatitis

**Słowa kluczowe:** błona śluzowa jamy ustnej, terapia laserem małej mocy, aftowe zapalenie jamy ustnej

### Cite as

Olejnik M, Ślebioda Z, Dorocka-Bobkowska B. Low-level laser therapy in the treatment of recurrent aphthous stomatitis (RAS) – a promising treatment option: A report of two cases. *Dent Med Probl.* 2019;56(3):317–321. doi:10.17219/dmp/108632

### DOI

10.17219/dmp/108632

### Copyright

© 2019 by Wrocław Medical University

This is an article distributed under the terms of the Creative Commons Attribution 3.0 Unported License (CC BY 3.0) (<https://creativecommons.org/licenses/by/3.0/>)

## Introduction

Recurrent aphthous stomatitis (RAS; aphthae) is a common, painful, chronic inflammatory disease affecting up to 25% of the population, with a slightly higher prevalence in women and in groups of a higher socioeconomic status.<sup>1,2</sup> The etiopathogenesis of RAS remains unclear, but an abnormal immune interaction within the oral mucosal cells caused by the impaired activation of the immune system in genetically predisposed subjects has been considered to be an essential contributor in this process.<sup>3–5</sup> In aphthous lesions, the barrier function of the oral epithelium is destroyed. The exposure of danger-signal receptors, such as Toll-like receptors (TLRs), to pathogen- or microbe-associated (PAMP/MAMP) and damage-associated (DAMP) molecular patterns leads to an acute inflammatory reaction with cytokine production in the epithelial cells.<sup>6</sup> The possible modifiers of the immune system in RAS include various local and systemic factors, e.g., stress and anxiety, mineral and vitamin deficiencies, hematological disorders, viral and bacterial infections, food allergies, trauma, smoking, or even left- or right-handedness. Systemic diseases and medications have also been suggested as the potential triggers of RAS in several studies, although the results remain equivocal.<sup>5,7,8</sup>

Familial accumulation was observed in up to 40% of patients with RAS.<sup>3,9</sup> The genetic risk factors determining an individual's susceptibility to the disease include various DNA polymorphisms distributed in the human genome, especially those related to alterations in the metabolism of cytokines.<sup>5,10</sup> Recent research has suggested that dysregulation in the production of defensins might be involved in the development of several oral pathologies, including those with an autoimmune background.<sup>6,11</sup>

Aphthous lesions may be associated with systemic diseases, such as Behçet's disease, Crohn's disease, HIV infection, anemia, cyclic neutropenia, and celiac disease.<sup>2,12</sup> Recurrent aphthous lesions have been classified into 3 varieties: major (Sutton), minor (Mikulicz) and herpetiform ulcers. Minor aphthae present as yellowish, shallow, ovoid erosions surrounded by an erythematous halo, smaller than 5 mm in diameter. They heal within 10–14 days and are typically located on the non-keratinized oral mucosa (the floor of the mouth and the labial or buccal mucosa). Major aphthae appear as deep ulcers, larger than 10 mm in diameter, which heal within 6 weeks, sometimes leaving a scar. The lesions are painful and show a predilection for the soft palate, palatal fauces, lips, and tongue. Herpetiform aphthae are small (1–2 mm in diameter) and multiple (up to 100), occurring throughout the oral cavity and lasting for 7–10 days.<sup>12,13</sup>

The treatment of RAS is difficult and not always effective. The standard treatment regime includes the local application of steroids and non-steroidal anti-inflammatory drugs, together with agents which enhance epithelial

regeneration. The therapy is mainly symptomatic and may lead to several side effects, including steroid-induced candidiasis. No effective causal treatment option is currently available.<sup>1,2,12,13</sup>

Low-level laser therapy (LLLT) involves the use of photons with non-thermal irradiance to alter biological activity. It is a non-invasive and atraumatic therapeutic method that involves the local application of a high-density, monochromatic, narrow-band light source. The main medical usage of LLLT is for pain and inflammation reduction, promoting the regeneration of different tissues and preventing damage to tissues. With the use of the appropriate power (from 5 to 200 mW) and wavelength (630–680 nm, 700–830 nm or 900 nm), the therapy brings anti-inflammatory and analgesic results, and wound healing is promoted.<sup>14,15</sup> The mechanism of action of LLLT may be very beneficial in the treatment of oral erosions and ulcers. There are few reports on accelerated healing in erosive mucocutaneous disorders and they are often presented as case series rather than large randomized clinical trials (RCTs). The effects on skin wound healing and periodontal inflammation management with laser biostimulation suggest that this treatment modality may also be useful for oral erosive conditions.<sup>16,17</sup>

This report describes 2 adult patients with RAS treated with LLLT to relieve pain and promote the healing of the ulcers. The clinical presentations with the signs and symptoms are discussed and illustrated, along with the treatment algorithms and outcomes.

## Case reports

### Case 1

A 25-year-old, generally healthy woman, reporting no detrimental habits was admitted to the Department of Gerodontology and Oral Pathology of Poznan University of Medical Sciences, Poland, with 2 painful ulcers on her tonsil and palatoglossal arch, which had developed 3 days earlier. Informed consent for examination was obtained from the patient as part of a routine protocol. According to the patient, the condition was recurrent, with flare-ups at 2–3-month intervals. The 1<sup>st</sup> episode appeared approx. 10 years earlier, and was exacerbated in the period 2009–2011, when she received orthodontic treatment with a fixed appliance. It was previously diagnosed as RAS by a general dentist. Usually, 1 or 2 major aphthae would appear simultaneously during a flare-up. The treatment of the previous lesions included a coating ointment composed of protein-free dialysate of calf blood and policresulen, which was not satisfactory for the patient. Upon admission, the patient suggested stress and tiredness as the cause for the lesions to recur.

On examination, 2 ulcers with an erythematous halo and fibrous coating, 2 cm in diameter, were revealed on the left tonsil and on the left palatoglossal arch (Fig. 1). Other regions of the oral mucosa were unaffected. The lymph nodes were normal. Due to the unfavorable location of the lesions and their large size, laser therapy was suggested. Low-level laser therapy was applied with a diode laser (DiodeLX, SMART M; Lasotronix, Piaseczno, Poland) set to a wavelength of 635 nm, a spot size of  $\varnothing$  8 mm, a power of 100 mW, and an energy fluency of 4 J/cm<sup>2</sup> in continuous mode for 20 s per lesion (Fig. 2). It was administered 3 times – on the 1<sup>st</sup>, 3<sup>rd</sup> and 4<sup>th</sup> day of the therapy. A baseline complete blood count (CBC) test performed on the day of the 1<sup>st</sup> visit showed no abnormalities. After the 1<sup>st</sup> session, the ulcers were less painful and the process of healing was evident (Fig. 3). After 3 sessions, the lesions were painless and the patient reported faster healing than during the previous episodes of RAS (Fig. 4).

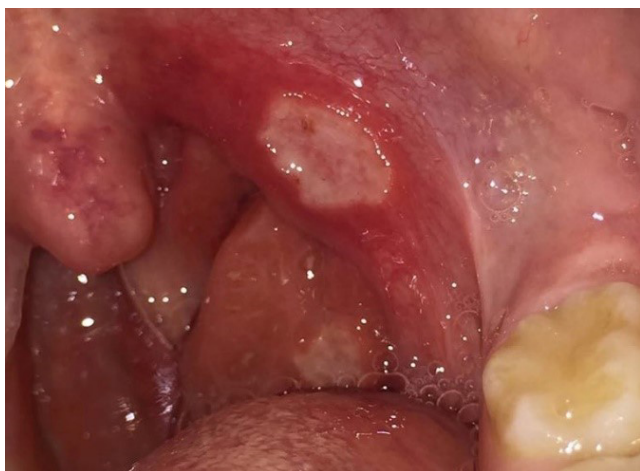

Fig. 1. Major aphthous ulcers on the tonsil and palatoglossal arch prior to treatment

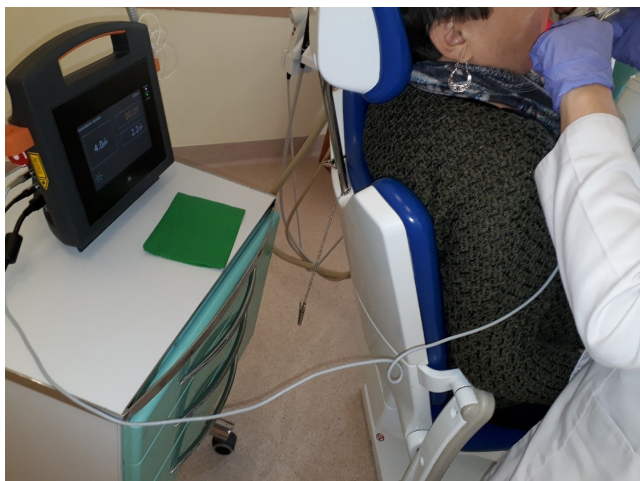

Fig. 2. SMART M diode laser with a wavelength of 635 nm and a spot size of  $\varnothing$  8 mm

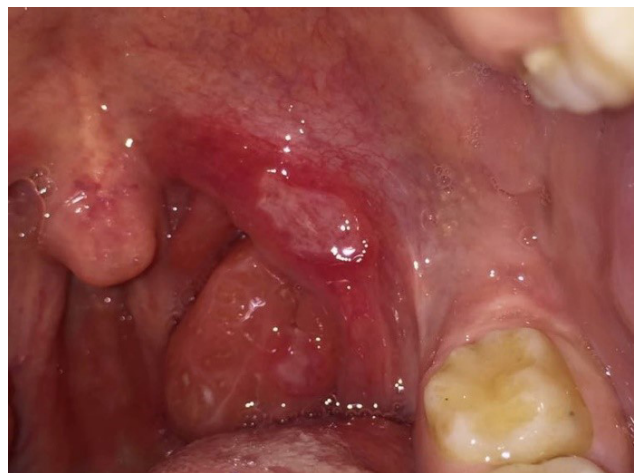

Fig. 3. Ulcers after the 1<sup>st</sup> session of low-level laser therapy (LLLT), showing the visible initiation of the healing process

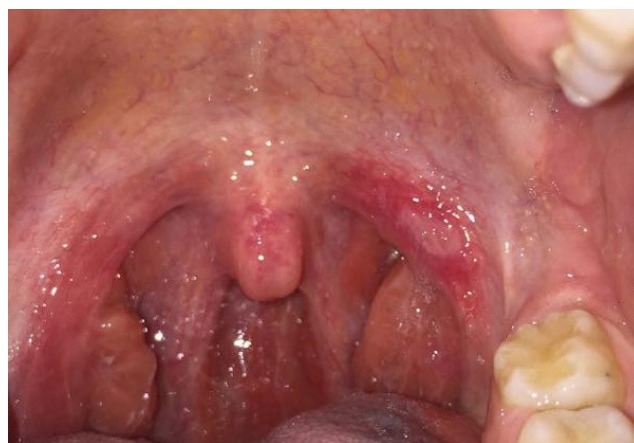

Fig. 4. Ulcers after 3 sessions of low-level laser therapy (LLLT)

## Case 2

An 81-year-old woman suffering from hypertension and type 2 diabetes (T2D) was admitted to the Department of Gerodontology and Oral Pathology of Poznan University of Medical Sciences, Poland, with a complaint of painful lesions in the oral cavity, which interfered with eating and speaking. Informed consent for examination was obtained from the patient as part of a routine protocol. The duration of the disease was 6 months with regular periods of remission and exacerbation. The patient had previously been treated by an otorhinolaryngologist and a general practitioner with topical choline salicylate, chlorhexidine mouth rinses and herbal extracts without satisfactory results. The CBC test results from the general outpatient clinic showed no abnormalities according to the patient.

Clinical examination revealed numerous minor aphthous erosions of the oral mucosa located on the buccal, labial, palatal, vestibular, gingival, tonsillar, and uvular surfaces (Fig. 5). Based on the anamnesis and the characteristic presentation of lesions, a diagnosis



of RAS was established. Low-level laser therapy was administered with a diode laser (DiodeLX, SMART M; Lasotronix) set to a wavelength of 635 nm, a spot size of  $\varnothing$  8 mm, a power of 100 mW, and an energy fluency of 4 J/cm<sup>2</sup> in continuous mode for 20 s per lesion a total of 3 times – on the 1<sup>st</sup>, 2<sup>nd</sup> and 4<sup>th</sup> day of treatment.

Additionally, a topical steroid and a coating salve were prescribed and applied to the available surfaces.

After the 1<sup>st</sup> session, the patient claimed that her pain had lessened and after 3 sessions, a significant improvement in her clinical condition was observed (Fig. 6).

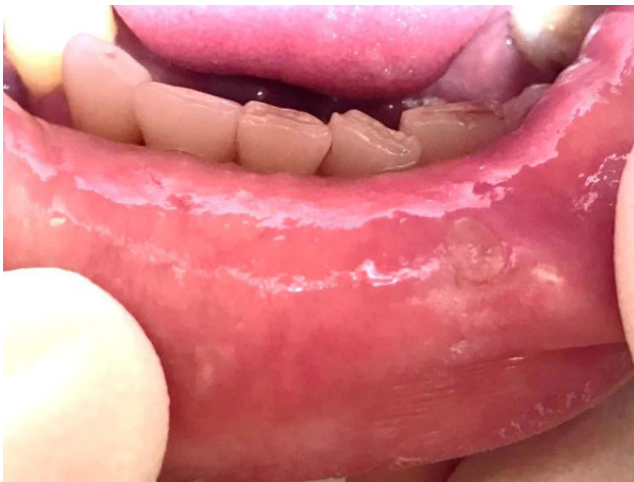

Fig. 5. Minor aphthous erosion on the labial surface prior to treatment

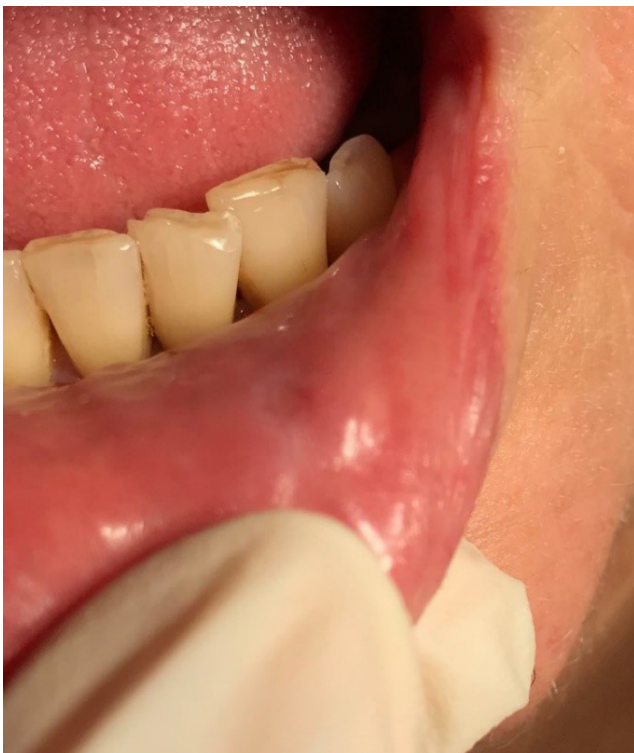

Fig. 6. Minor aphthous erosion on the labial surface after the 3<sup>rd</sup> session of low-level laser therapy (LLLT)

## Discussion

Although several multi-center studies have been performed worldwide, the etiology of RAS remains elusive and only non-specific, symptomatic treatment is currently available. Pain management in RAS is a challenge in oral medical practice. A typical treatment algorithm begins with excluding systemic diseases and correcting any predisposing factors, such as nutritional deficiencies.<sup>3,12,13</sup> Treatment options include non-steroidal and steroidal agents, antibiotics to prevent secondary infections, analgesic drugs, and coating films. Topical corticosteroids, which are widely used in immune-mediated oral diseases, eliminate pain and shorten the healing time, although they may induce acute pseudomembrane candidiasis in non-immunocompetent patients, e.g., those who suffer from diabetes mellitus or are HIV-positive. Mouthwashes containing tetracycline or chlorhexidine may reduce ulcer duration, although they may also cause tooth discoloration and are contraindicated in children.<sup>1,3,12</sup> A topical coating salve prevents the irradiation of the lesions. Low-level laser therapy may be successfully administered as a non-invasive method to patients with large aphthous ulcers to accelerate the healing process.<sup>18</sup>

The cases described in this paper demonstrated the analgesic and healing-promoting effects of LLLT as the only therapy, and in combination with a topical steroid and a coating salve.

Several articles describing the effects of laser therapy in patients with RAS and lichen planus (LP) have been published in recent years. Diode, Nd:Yag and CO<sub>2</sub> lasers have been used in trials. The beneficial effects of LLLT with diode lasers which have been reported in RCTs on RAS include immediate pain reduction and a shorter healing time in comparison with the placebo groups.<sup>19–22</sup> Moreover, De Souza et al. reported faster regression of lesions when using LLLT than in patients treated with corticosteroids (4 days vs 5–7 days).<sup>23</sup> In 2 case series presented by Anand et al. and Gandhi Babu et al., pain relief and faster healing times were reported, compared to previous episodes, by all RAS subjects who underwent diode laser stimulation.<sup>24,25</sup> Recent studies performed by Lalabonova and Daskalov revealed a greater efficacy of LLLT as compared to conventional pharmacotherapy in reducing pain and the symptoms of inflammation, and in promoting healing and epithelialization.<sup>26</sup> Albrektson et al. showed the analgesic effect of LLLT after the 1<sup>st</sup> session, persisting for up to 3 days according to the visual analog scale (VAS). Patients also reported pain relief while eating, drinking and tooth brushing.<sup>19</sup> On the other hand, Jijin et al. presented similar results for both LLLT and amlexanox – a topical anti-inflammatory and anti-allergic drug.<sup>27</sup> Likewise, Kashmoola et al., who examined 47 RAS subjects in Iraq, did not observe significant differences in the healing time between the experimental groups and the controls.<sup>28</sup> Attempts to manage RAS with CO<sub>2</sub> lasers

in a non-contact, non-ablative manner, where the mucosa was protected from the heat produced by the laser with a thick layer of a transparent gel, also resulted in significant pain reduction with a sustained analgesic effect and an accelerated healing process.<sup>16,17,20</sup> The use of Nd:Yag laser stimulation in 2 RCTs resulted in pain relief and a faster healing time in the experimental group as compared to the controls,<sup>29</sup> and led to a significant analgesic effect in the experimental group.<sup>30</sup> The diversity of LLLT parameters used in many of the studies, including treatment dosage, wavelength, exposure time, or tissue type, prevents an unambiguous interpretation of the results.

Pain reduction and the acceleration of healing in the case of recurrent flare-ups are extremely relevant to the quality of life of patients with RAS. Further studies are required to define the efficacy of LLLT in the treatment of RAS in comparison with more traditional, anti-inflammatory treatment modalities.

## Conclusions

Low-level laser therapy may be considered an effective and non-invasive method of reducing symptoms and promoting the healing of aphthous ulcers in patients with RAS without addressing the cause. There is, however, still an urgent need to develop an effective, causative treatment for RAS.

### ORCID iDs

Maria Olejnik  <https://orcid.org/0000-0003-3474-2179>  
 Zuzanna Ślebioda  <https://orcid.org/0000-0002-5482-3964>  
 Barbara Dorocka-Bobkowska  <https://orcid.org/0000-0003-3659-7761>

### References

- Belenguer-Guallar I, Jiménez-Soriano Y, Claramunt-Lozano A. Treatment of recurrent aphthous stomatitis. A literature review. *J Clin Exp Dent*. 2014;6(2):e168–e174.
- Akintoye SO, Greenberg MS. Recurrent aphthous stomatitis. *Dent Clin North Am*. 2014;58(2):281–297.
- Scully C, Gorsky M, Lozada-Nur F. The diagnosis and management of recurrent aphthous stomatitis: A consensus approach. *J Am Dent Assoc*. 2003;134(2):200–206.
- Ślebioda Z, Szponar E, Kowalska A. Etiopathogenesis of recurrent aphthous stomatitis and the role of immunologic aspects: Literature review. *Arch Immunol Ther Exp (Warsz)*. 2014;62(3):205–215.
- Ślebioda Z, Kowalska A, Rozmiarek M, Krawiecka E, Szponar E, Dorocka-Bobkowska B. The absence of an association between interleukin 1β gene polymorphisms and recurrent aphthous stomatitis (RAS). *Arch Oral Biol*. 2017;84:45–49.
- Al-Samadi A, Salem A, Ainola M, Hietanen J, Häyrynen-Immonen R, Konttinen YT. Increased beta 2 defensin in recurrent aphthous ulcer. *Oral Dis*. 2015;21(3):292–298.
- Davies A, Gebremedhin S, Yee M, et al. Cationic porphyrin-mediated photodynamic inactivation of *Candida* biofilms and the effect of miconazole. *J Physiol Pharmacol*. 2016;67(5):777–783.
- Dorocka-Bobkowska B, Düzgüneş N, Konopka K. AmBisome and Amphotericin B inhibit the initial adherence of *Candida albicans* to human epithelial cell lines, but do not cause yeast detachment. *Med Sci Monit*. 2009;15(9):BR262–BR269.
- Ship JA, Chavez EM, Doerr PA, Henson BS, Sarmadi M. Recurrent aphthous stomatitis. *Quintessence Int*. 2000;31(2):95–112.
- Guimarães AL, Correia-Silva Jde F, Sá AR, et al. Investigation of functional gene polymorphisms IL-1beta, IL-6, IL-10 and TNF-alpha in individuals with recurrent aphthous stomatitis. *Arch Oral Biol*. 2007;52(3):268–272.
- Ślebioda Z, Szponar E, Kowalska A. Defensins and their role in the maintenance of the oral cavity homeostasis – a literature review. *Centr Eur J Immunol*. 2013;38(1):111–117.
- Tarakji B, Gazal G, Al-Maweri SA, Azzeghaiby SN, Al Aizari NA. Guideline for the diagnosis and treatment of recurrent aphthous stomatitis for dental practitioners. *J Int Oral Health*. 2015;7(5):74–80.
- Barrons RW. Treatment strategies for recurrent oral aphthous ulcers. *Am J Health Syst Pharm*. 2001;58(1):41–50.
- Iwanicka-Grzegorek E, Puczyłowska-Rybaczyk M. Therapeutic and diagnostic application of laser in oral cavity diseases [in Polish]. *Nowa Stomat*. 2011;16(3):128–133.
- Cotler HB, Chow RT, Hamblin MR, Carroll J. The use of low level laser therapy (LLLT) for musculoskeletal pain. *MOJ Orthop Rheumatol*. 2015;2(5):00068.
- Owczarek B, Kiernicka M, Gałkowska E, Wysokińska-Miszczuk J. Influence of laser biostimulation on the healing of tissues in patients treated for chronic periodontitis [in Polish]. *Dent Med Probl*. 2004;41(1):45–49.
- Hall G, Anneroth G, Schennings T, Zetterqvist L, Rydén H. Effect of low level energy laser irradiation on wound healing. An experimental study in rats. *Swed Dent J*. 1994;18(1–2):29–34.
- Caputo BV, Noro-Filho GA, dos Santos CC, Okida Y, Giovanni EM. Laser therapy of recurrent aphthous ulcer in patient with HIV infection. *Case Rep Med*. 2012;2012:695642.
- Albrektson M, Hedström L, Bergh H. Recurrent aphthous stomatitis and pain management with low-level laser therapy: A randomized controlled trial. *Oral Surg Oral Med Oral Pathol Oral Radiol*. 2014;117(5):590–594.
- Aggarwal H, Singh MP, Nahar P, Mathur H, Gv S. Efficacy of low-level laser therapy in treatment of recurrent aphthous ulcers – a sham-controlled, split mouth follow up study. *J Clin Diagn Res*. 2014;8(2):218–221.
- Al Mulla F, Al Amari R, Zakaria D, Hemdan H. Diode laser treatment in aphthous ulcer for handicapped patients in Kuwait. *J Am Sci*. 2012;8(8):994–997.
- Khademi H, Shirami AM, Nikegbal F. Evaluation of low level laser therapy in recurrent aphthous stomatitis. *Shiraz Univ Dent J*. 2009;10(2):160–162.
- De Souza TO, Martins MA, Bussadori SK, et al. Clinical evaluation of low-level laser treatment for recurring aphthous stomatitis. *Photomed Laser Surg*. 2010;28(Suppl 2):S85–S88.
- Anand V, Gulati M, Govila V, Anand B. Low level laser therapy in the treatment of aphthous ulcer. *Indian J Dent Res*. 2013;24(2):267–270.
- Gandhi Babu DB, Chavva S, Waghay S, Jyothi Allam NS, Kondaiah M. Low level laser therapy to reduce recurrent oral ulcers in Behçet's disease. *Case Rep Dent*. 2016;2016:4283986.
- Lalabonova H, Daskalov H. Clinical assessment of the therapeutic effect of low-level laser therapy on chronic recurrent aphthous stomatitis. *Biotechnol Biotechnol Equip*. 2014;28(5):929–933.
- Jijin MJ, Rakaraddi M, Pai J, et al. Low-level laser therapy versus 5% amlexanox: A comparison of treatment effects in a cohort of patients with minor aphthous ulcers. *Oral Surg Oral Med Oral Pathol Oral Radiol*. 2016;121(3):269–273.
- Kashmoola MA, Salman H, Al-Waez MM. Clinical effect of low level laser therapy on healing of recurrent aphthous ulcer and oral ulceration in Behçet's disease. *J Coll Dent*. 2005;17(2):36–40.
- Arabaci T, Kara C, Çiçek Y. Relationship between periodontal parameters and Behçet's disease and evaluation of different treatments for oral recurrent aphthous stomatitis. *J Periodontol Res*. 2009;44(6):718–725.
- Tezel A, Kara C, Balkaya V, Orbak R. An evaluation of different treatments for recurrent aphthous stomatitis and patient perceptions: Nd:YAG laser versus medication. *Photomed Laser Surg*. 2009;27(1):101–106.

Dental  
and Medical Problems

